II. *The Development of some of the Cranial Muscles of Ganoid Fishes.*

By F. H. EDGEWORTH, *M.D., Professor of Medicine, University of Bristol.*

(*Communicated by Prof.* J. P. HILL, *F.R.S.*)

(Received October 31, 1927,—Read February 2, 1928.)

(PLATES 7–33.)

CONTENTS.

This paper, which is based on investigation of Acipenser, Polypterus, Amia and Lepidosteus, is written partly to supplement, partly to amend, some scanty notes which I published on the subject in 1911. Observations on Plagiostomi, Teleostei and Amphibia, which have a bearing on the problems discussed, are incorporated in the paper.

The Ocular Muscles.

The study of the development of the ocular muscles was begun by BALFOUR (1878), who stated that it is probable that the walls of the 1st head-cavity of Selachian embryos develop into the external ocular muscles. MARSHALL (1881) stated that the Recti superior, internus and inferior, and probably the Obliquus inferior, are derived from the walls of the 1st head-cavity. He did not find the origins of the Obliquus superior and Rectus externus, but in regard to the latter said that it is probable that it is developed from the walls of the dorsal ends of the 2nd and 3rd head-cavities.

v. WIJHE (1882) confirmed MARSHALL'S statements in regard to the muscles developed from the 1st head-cavity. He was the first to state that the Obliquus superior is

[Published August 20, 1928.

developed from the dorsal end of the mandibular head-cavity (which he called the 2nd myotome), and that the Rectus externus is developed from the dorsal end of the hyoid head-cavity (which he called the 3rd myotome). He also stated that there is a serial homologue of these dorsal ends in the 1st branchial arch (which he called the 4th myotome). He was of opinion that the primordia of the Obliquus superior and Rectus externus are the 2nd and 3rd præotic myotomes, and are serially homologous with the postotic spinal myotomes. He regarded the IVth and VIth nerves as ventral roots, the corresponding dorsal roots being the Vth and VIIth nerves innervating muscles derived from the corresponding "Visceralbogenhöhle."

These views have always presented difficulties and many alternative theories have been advanced, which it is not necessary to recapitulate. An excellent summary was given by NEAL in 1914. NEAL put v. WIJHE'S theory very concisely as follows: "The eye muscles are the last remnants of the lateral trunk musculature anterior to the ear."

The first notable advance in knowledge, as distinguished from opinion, subsequent to the publication of v. WIJHE'S paper, was made by Miss PLATT (1891), who stated that in *Acanthias vulgaris* the posterior end of the Obliquus superior separates from the remainder and forms a rudimentary muscle, which she called "muscle E." This, she said, subsequently disappears. It was, however, shown by DOHRN (1901 and 1904) that muscle E does not disappear, but fuses with the Rectus externus. He found this to be the case in Scyllium, Pristiurus, Mustelus, Acanthias, Heptanchus, Scymnus, Torpedo and Raja. This statement was confirmed by NEAL (1909, 1914 and 1918) in Squalus, and by myself (1925) in *Scyllium canicula* and *Acanthias vulgaris*.

DE BEER (1924) stated that muscle E of Heterodontus does not fuse with the Rectus externus, but breaks down into mesenchyme subsequent to the 21-mm. stage (the exact stage in which this was said to occur was not given). This statement is, I think, based on insufficient evidence, for I find muscle E as a small mass partially fused with the Rectus externus in a 30-mm. embryo (fig. 19). In this frontal section the two parts of the Rectus externus can be easily distinguished. The cells of muscle E are cut transversely, those of the hyoid constituent longitudinally. There is no limiting membrane between these two parts.

Dipnoi.—The external ocular muscles of Dipnoi are developed exclusively from the præmandibular somite—an epithelium-lined vesicle in early stages of Ceratodus, an aggregate of cells without any central cavity in the Dipneumona (AGAR, 1907; EDGEWORTH, 1925 and 1926).

Urodela.—The development of the ocular muscles of Urodela, so far as I have been able to find, has not hitherto been followed. SCOTT and OSBORN stated that an epithelium lined vesicle, the præmandibular somite, is formed in Triton, but the investigations were not carried farther, and Miss PLATT stated that in Necturus there appears to be no early division between the mesoderm of the præmandibular and mandibular somites.

In an 11-mm. larva of *Menopoma alleghaniense* the mandibular segment is occupied by yolk-filled cells. In one of 12 mm. (figs. 149 to 151) the mandibular muscle-plate and præmandibular somite are formed as a continuous whole. The cells are packed with yolk-granules and the limits of the individual cells are not clear, but the muscle-plate and præmandibular somite, apparently of epithelial cells, are sharply marked off from the surrounding scanty mesoblast except at the dorsal end of the muscle-plate. Just below this the muscle-plate is continuous anteriorly with the præmandibular somite, which extends forward between the eye and the brain. The two præmandibular somites are continuous with one another by a transverse bridge across the middle line. Below the junction of the præmandibular somite and the mandibular muscle-plate the latter passes down in the mandibular segment. Its lower extremity is continuous with that of its fellow and with the lower end of the hyoid muscle-plate.

In a 15-mm. larva (figs. 152, 153) the cells of the præmandibular somite and mandibular muscle-plate are still filled with yolk-granules. They are continuous with one another.

In a 17-mm. larva (fig. 154) the præmandibular somite is separate. It consists of a vertical plate of cells median to the hinder part of the eye. This plate has a long anterior projection from its upper end—the primordium of the Obliquus superior; a similar one from its lower end—the primordium of the Obliquus inferior; and a short posterior projection from its lower end—the primordium of the Rectus externus.

In an 18-mm. larva (fig. 155) the Obliquus superior, Obliquus inferior and Rectus externus are separate. The vertical plate has separated into Rectus superior and Rectus inferior. In a 20-mm. larva the Rectus internus is developed as an anterior projection from the upper end of the Rectus inferior. The development of the external ocular muscles of *Hynobius nebulosus* and *Necturus maculatus* is similar to that occurring in Menopoma.

The differences between these Urodela and Ceratodus are, in some measure at least, related to the great size of the bulbus oculi and its closeness to the brain in the former. The muscles—so to speak—have great difficulty in getting to their places.

Anura.—CORNING (1899) stated that in Rana the primordium of the oculo-motorius musculature is visible, at a tolerably late period, as a cell-mass close to the median and posterior sides of the bulbus oculi. The length of this larva was not given, nor any figures or further details.

In a 7-mm. larva of *Rana temporaria* (fig. 156, from a transverse section) the mandibular muscle-plate has undergone a slight amount of rotation and slopes downwards and forwards in the mandibular segment. Its hind, or dorsal, end is below the posterior edge of the bulbus oculi. The præmandibular somite is an upward projection from the hind end of the mandibular muscle-plate, internal to the posterior part of the eye.

In an 8-mm. larva (fig. 157, from a transverse section) the præmandibular somite has separated. In one of 9 mm. (fig. 159, from a transverse section, and figs. 160 to 162, from horizontal sections) the præmandibular somite is concavo-convex in shape, fitting up against the eye. It has three projections: (1) Dorso-anterior, reaching as high up as the upper level of the eye—the primordium of the Obliquus superior; (2) external, extending outwards between the eye and the Gasserian ganglion—the Rectus externus;

(3) forwards, beneath the eye—the primordium of the Obliquus inferior and Recti inferior and internus. In a 10-mm. larva all six ocular muscles are separate and distinct.

Ganoids.—Observations have been recorded on *Acipenser sturio* by v. KUPFFER, on Lepidosteus by VEIT, and on Amia by DE BEER. v. KUPFFER (1893), who investigated his material only by sagittal sections, stated that in embryos of *Acipenser sturio*, between 60 and 70 hours after fertilisation, there are two pairs of large epithelium-lined vesicles just behind the eyes. The medial pair is connected together by a transverse tract, and is to be regarded as "præmandibular." The lateral pair is presumably "mandibular." He found it difficult to determine the younger stages, but at length found, between the 55th and 58th hours, a transverse swelling (querer Wulst) of the endoderm with which both pairs of vesicles are continuous. The transverse swelling is constricted from the endoderm and develops into the transverse tract, whilst the lateral pair becomes isolated. The further development was not traced. No figures were given.

VEIT (1911) stated that in the earliest stages of Lepidosteus he investigated (embryos of 8 to 10 mm.) three primordia of the ocular muscles are present: (1) A large mesoderm cavity lined by flat cubical epithelium, between the hinder part of the eye and the brain. This gives rise to the Recti superior, internus and inferior, and the Obliquus inferior. (2) The primordium of the Obliquus superior—a short cellular cord dorsal to the hinder part of the eye. (3) The primordium of the Rectus externus—a cell-cord close to the Trigeminus ganglion. The subsequent development was followed from this stage.

DE BEER (1924) stated that the præmandibular somite of Amia gives rise to the Recti superior, internus and inferior, and the Obliquus inferior. He also stated that the Obliquus superior and Rectus externus arise by condensation of mesenchyme. This mesenchyme, in the case of the latter muscle, represents the broken-down hyoid somite. The figures given show the Obliquus superior as absent in a 7-mm. embryo, but present in an 11-mm. one, and the Rectus externus as present in the 7-mm. embryo, *i.e.*, that the Obliquus superior is developed subsequently to the Rectus externus. No figure showing the existence of a "hyoid somite" was given.

The development of the external ocular muscles could not be traced in Polypterus, as in the 6·75-mm. embryo—the earliest available—they are already formed. It was, however, possible to do so in Acipenser, Amia and Lepidosteus.

In a 6·5-mm. embryo of *Acipenser ruthenus* (figs. 20 to 23) the mandibular muscle-plate is a column of cells in the mandibular segment which is sharply marked off from the surrounding loose mesoblast. Its upper part is behind the maxillo-mandibular ganglion of the Vth nerve. A little below the apex of the muscle-plate a projection passes forward internal to the ganglion. Its apex is a large vesicle—the anterior head cavity or præmandibular somite—which is connected across the middle line to its fellow by a column of epithelial cells. Behind the præmandibular vesicle is another large vesicle—the primordium of the Obliquus superior. There is only a layer, one cell thick, between the cavities of the præmandibular vesicle and that of the Obliquus superior. The Obliquus superior is connected with the mandibular muscle-plate by a neck, internal to the ganglion. The cavity of the Obliquus superior shows a little diverticulum downwards and backwards in the neck. The neck is the primordium of the Rectus externus.

In a 7·5-mm. embryo (fig. 24) the præmandibular somite is a separate structure. A little vesicle has appeared in the neck of the projection from the muscle-plate. It was not determined whether this vesicle is the separated diverticulum mentioned above, or of independent formation. The mandibular muscle-plate is beginning to separate into the parts it will form—from above downwards the Constrictor i dorsalis, the Adductor mandibulæ and the Intermandibularis. The anterior projection, *i.e.*, the primordia of the Obliquus superior and the Rectus externus, is continuous with the Constrictor i dorsalis portion. Figs. 25 and 26, from a model of an 8-mm. embryo, shows the same conditions. The Obliquus superior portion of the anterior projection is a little smaller and projects forwards and upwards over the eye.

In a 9-mm. embryo (fig. 27) the anterior projection has separated from the mandibular muscle-plate. The walls of the Obliquus superior portion have thickened, but there is still a small cavity. The cavity in the Rectus externus portion is obliterated.

In a 9·5-mm. embryo (fig. 28) the primordia of the Obliquus superior and Rectus externus have separated from one another. The former, in which the cavity is obliterated, has migrated over the dorsum of the eye. The posterior end of the Rectus externus has extended backwards and inwards towards the parachordal plate. The præmandibular somite is still a vesicle.

In a 10-mm. embryo the cavity in the præmandibular somite is obliterated, and the somite has separated into the Recti superior, internus and inferior, and the Obliquus inferior.

The formation of the Obliquus superior and Rectus externus in Amia and Lepidosteus is essentially similar to that in Acipenser, but there are differences which are related to three phenomena: (1) The upper part of the mandibular muscle-plate—the part which subsequently develops into the Constrictor i dorsalis and Adductor mandibulæ—is almost horizontal in position (*vide* fig. 71 of Amia and fig. 114 of Lepidosteus). The primordium of the Obliquus superior and Rectus externus, correspondingly, passes at first horizontally inwards or upwards from the dorsal end of the mandibular muscle-plate to the præmandibular somite, and not forwards as in Acipenser, where the mandibular muscle-plate is almost vertical in position. (2) The primordium of the Obliquus superior and Rectus externus is solid from the first. (3) The eye is relatively larger.

Amia.—In a 4-mm. embryo (figs. 57 to 59, from transverse sections, and figs. 60 and 61, from horizontal ones) a process of the dorsal end of the mandibular muscle-plate extends inwards to the præmandibular somite. It is situated beneath the hinder part of the eye and extends over a distance of five sections = 0·025 mm. In a 4·5-mm. embryo (fig. 62) this process has become separated both from the mandibular muscle-plate and the præmandibular somite. It has extended upwards and slightly outwards behind the eye. In a 5-mm. embryo (figs. 63 to 66 and 67) it has extended farther up behind the eye. Fig. 63, from the horizontal series, depicts the upper end of the primordium. In a 6-mm. embryo (figs. 68 to 70) the primordium has separated into an upper part—the primordium of the Obliquus superior—and a lower—that of the Rectus externus. The former has extended forwards over the eye, though its hind end is still posterior to the eye. (There is only a gap of two 0·005-mm. sections between figs. 68 and 69.) The Rectus externus has extended a little outwards, whilst its inner end has extended backwards and inwards towards the notochord. In a 7-mm. embryo its inner end is attached to the parachordal plate which has now developed. Thus, whilst in Acipenser the Obliquus superior migrates forwards and slightly upwards over the eye, in Amia it migrates upwards behind, and then forwards over the eye. It has, so to speak, to climb up round the relatively large eye to get to its position.

Lepidosteus.—The phenomena in Lepidosteus are so similar to those of Amia that only a very short description need be given. In an embryo of 3 mm. (fig. 106) the præmandibular somites are in process of being proliferated from a point just in front of the anterior end of the notochord and behind the hypophysis. No lumen is present. No definite evidence of the mandibular muscle-plate is visible. In an embryo of 4 mm. (figs. 107 and 108) a large cavity has developed in each præmandibular somite. The mandibular muscle-plate has developed. It is a horizontal structure lateral to the gut. It has an upward projection postero-internal to the eye, the internal edge of which is in contact with the external wall of the præmandibular somite. In an embryo of 6 mm. (figs. 109 and 110) the upward projection has separated from the mandibular muscle-plate. In an embryo of 8 mm. (fig. 111) it is still single. In one of 9 mm. (figs. 112 and 113) its upper end has extended slightly over the eye, and the primordium has separated into the Obliquus superior and Rectus externus. There is a gap of five sections (= 0·025 mm.) between these two structures.

The above-described observations show that the development of the external ocular muscles in Dipnoi, Urodela, Anura, Ganoids and Plagiostomi, can be summarised as follows :—

1. The præmandibular somite is, at first, continuous posteriorly with the upper end of the mandibular muscle-plate, and subsequently separates from it. It is solid from the first in Dipneumona, Anura, and generally in Urodela.* It is an epithelium-lined vesicle in Plagiostomi, Teleostomi and Ceratodus. Except in Dipneumona and Anura it is connected with its fellow across the middle line by a transverse canal or epithelial tract. It is the source of all the ocular muscles in Dipnoi, Urodela and Anura. It is the source of the Recti superior, inferior and internus and of the Obliquus inferior in Teleostomi and Plagiostomi.
2. In Acipenser, Amia, Lepidosteus and Plagiostomi, after separation of the præmandibular somite, an anterior or medial projection of the upper end of the

---

* It is solid in Menopoma, Necturus and Hynobius, a vesicle in Triton.

mandibular muscle-plate is left. The distal end of this projection gives rise to the Obliquus superior. The proximal end gives rise to the Rectus externus in Teleostomi, to muscle E in Plagiostomi. The primordium of the Obliquus superior is a vesicle in Acipenser and Plagiostomi. It is solid in Lepidosteus and Amia.

The primordium of the Rectus externus has a small cavity in Acipenser which is soon obliterated. It is solid in Lepidosteus and Amia.

3. Muscle E of Plagiostomi fuses with an anterior projection of the dorsal end of the hyoid muscle plate to form the Rectus externus. The anterior projection represents the original continuity between the dorsal end of the hyoid muscle-plate with that of the mandibular muscle-plate.
4. There is no homologue of the 2nd and 3rd præotic myotomes of v. WIJHE present in Dipnoi or Amphibia, nor any homologue of the 3rd in Teleostomi.
5. The innervation of the Obliquus superior by the IVth nerve and that of the Rectus externus by the VIth, remains constant in all groups whatever be the derivation of the muscles.

These phenomena lead to the following conclusions: The primary source of all the ocular muscles is the præmandibular somite. This is retained in Dipnoi, Urodela and Anura.

In Ganoidei and Plagiostomi the development is modified, in that the origins of the Obliquus superior and Rectus externus have been shifted back. This is most marked in the case of the Rectus externus of Plagiostomi. In Ganoidei the ocular muscles are thus derived from two segments,* in Plagiostomi from three. Muscle E is either homologous or homoplastic† with the Rectus externus of Ganoidei—according to the assumed ancestry of the latter.

These conclusions are in harmony with those drawn from comparison of the development of the Palato-quadrate and masticatory muscles in the above phyla. In Dipnoi and Amphibian larvæ‡ the Palato-quadrate is fixed to the chondrocranium and the masticatory muscles are Levatores mandibulæ, passing from the chondrocranium to Meckel's cartilage. In Ganoidei and Plagiostomi the Palato-quadrate is at first fixed to the chondrocranium and subsequently becomes movable, and the primordium of the masticatory muscles separates into Constrictor i dorsalis and Adductor mandibulæ. In Dipnoi and Amphibian larvæ there are thus both a primary method of development of the ocular muscles and a primary condition of the Palato-quadrate and the masticatory

---

* I may add that the developmental phenomena in Sphenodon are similar to those of Ganoidei, in that the Obliquus superior and abducens primordium are developed from the vesicle at the upper end of the mandibular muscle-plate.

† Similar structures may be regarded as homologous if the evidence suggests that they have been inherited from common ancestors, and homoplastic if the evidence suggests that they have been independently acquired.

‡ The evidence for Dipnoi, Amphibia, Teleostomi and Plagiostomi was published in 1925.

muscles. In Ganoidei and Plagiostomi there are secondary methods of development of the Obliquus superior and Rectus externus and secondary conditions of the Palatoquadrate and the masticatory muscles.

The theory of v. WIJHE that the primordia of the Obliquus superior and Rectus externus in Selachii are præotic myotomes, serially homologous with postotic spinal myotomes, will not account for all the above phenomena, will not—in the phrase of JOHN LOCKE the philosopher—" carry us quite through,"* and is therefore untenable.

If this be accepted it would follow that the IVth and VIth nerves are not segmental nerves, but separated portions of the IIIrd nerve, and their motor nuclei in the mid-brain separated portions of the IIIrd motor nucleus. The motor nucleus of the IVth nerve has migrated obliquely across the middle line, with a resulting trochlear chiasma. This migration across the middle line is in many genera not complete—the IVth nerve containing uncrossed as well as crossed fibres.† The VIth nerve has migrated backwards.

The existence of the IVth and VIth nerves in Dipnoi and Amphibia suggests that the individualisation of these nerves and of their motor nuclei took place anterior in time and independently of the changes in the derivation of the muscles they innervate.

This theory affords an explanation of the close similarity between the IVth and VIth nerves and the branches of the IIIrd nerve to external ocular muscles, in that they have sensory-nerve endings, but no separate ganglionated roots. The cell-origins of the muscle-sensory fibres are probably to be found in scattered groups of cells in the roots and peripheral course of these nerves. The external ocular muscles, whether derived from one or several sources, thus form a morphological unit with distinct and exceptional characters.

Theories as to the morphological nature of the external ocular muscles have, I think, been based too exclusively on the conditions in Selachian embryos. Whatever be the ultimate value of the opinions expressed above, this, at any rate, is certain—that no theory will be found satisfactory which does not also take into account the phenomena in Dipnoi, Urodela and Ganoids, and this without any underlying supposition that the conditions in Selachii are necessarily the most primitive, and others found are modifications of them.

I said above that muscle E of Plagiostomi was probably either homologous or homoplastic with the Rectus externus of Teleostomi. If Teleostomi are descended from some primitive Elasmobranch stock, or if the reverse be true, then the structures are probably homologous. It is to be pointed out, however, that Levatores arcuum branchialium,

---

* The passage is so good and so apt to the occasion that I venture to transcribe it: " Hypotheses . . . often direct us to new discoveries. But . . . we should not take up any one too hastily . . . till we have very well examined particulars and made several experiments in that thing which we would explain by our hypothesis and see whether it will agree to them all; whether our principles will carry us quite through, and not be as inconsistent with one phenomenon of nature as they seem to accommodate and explain another."

† A summary of the evidence hitherto available was given by KIDD in 1922.

Subarcuales recti (see pp. 72–76), Transversi ventrales (see pp. 72–76), and a Sphincter œsophagi (see pp. 77–79) are cranial muscles which are present in both Dipnoi and Teleostomi but are absent in all Elasmobranchii, and that a ventral larynx with a Constrictor laryngis is present in Polypterus (see p. 77) as well as in Dipnoi. Further, the primitive innervation of Coraco-branchialis v (Teleostomi) and of Coraco-branchiales ii, iii, iv and v (Dipnoi) has been retained, whereas in Elasmobranchii the Coraco-branchiales have a secondary innervation from spinal nerves.

Such close resemblances* point to a common ancestry, and I think it probable that Teleostomi branched off from a primitive monimostylic Dipnoan stock—at some period anterior in time to the development of an ascending process of the Palato-quadrate, and to the loss of a Hyomandibula.†

It is probable then, that muscle E of Plagiostomi is only homoplastic with the Rectus externus of Teleostomi. Another instance of homoplasty referred to later (pp. 63–66) is that between the Adductores arcuum branchialium of Selachii and Teleostomi.

The Mandibular and Hyoid Bars of Polypterus senegalus.

Mandibular Bar.—In a 6·75-mm. embryo (figs. 40 and 41) the mandibular bar is a continuous L-shaped procartilaginous structure. There is a vertical portion in front of the first gill-cleft. The ventral end of this turns forwards horizontally. It may be inferred, from their position relative to the masticatory muscles (*vide infra*), and from comparison with the conditions present in the 8-mm. embryo, that these two portions are the Quadrate and Meckel's cartilage. No material between this 6·75-mm. embryo and the one of 8 mm. was available.

In an embryo of 8 mm. (figs. 51 and 52) the Palato-quadrate and Meckel's cartilage are fully formed and chondrified. The hind end of Meckel's cartilage articulates with the quadrate portion of the Palato-quadrate. The palatal process is a long horizontal rod which is parallel with and close to the Trabecula, and its anterior end is in contact with it. There is no basal process of the Trabecula or basal process of the Palato-quadrate. Behind the articulation of Meckel's cartilage the Quadrate has an incomplete ascending otic process, the upper end of which is separated by a very small gap of 0·02 mm. from the auditory capsule. In the 9·3-mm. embryo (figs. 53 and 54) the conditions are similar.

In the 30-mm. embryo, described and depicted by BUDGETT, the now small otic process projects backwards horizontally. In the adult stage, as depicted by v. WIJHE and ALLIS, the process is much less marked.

---

* The list given above refers solely to cranial muscles. There are also other resemblances, *e.g.*, the presence of external gills with correlated branchial aortic arches in embryonic stages of some Teleostomi and some Dipnoi, but not in any Elasmobranchii, and the development of the branchial bars on the inner side of the muscle-plates, whilst in Plagiostomi they are developed within the middle of the plates (*vide* pp. 63–66).

† *Vide* 'Jour. of Anat.,' vol. lix, and 'Trans. R. Soc. Edin.,' vol. liv.

On comparison with the developmental phenomena in other Ganoids, as determined for Acipenser by PARKER and HENDERSON,* for Amia by PEHRSON, and Miss HAGUE, and for Lepidosteus by PARKER and VEIT, it appears that:—

1. In Amia, Lepidosteus and Acipenser, the Palato-quadrate bar is formed as a whole—in one piece. In Polypterus the Quadrate portion is formed first and the palatal portion subsequently, but whether by forward extension from the Quadrate, or independently and then extending back to join the Quadrate, as in Clupea, could not be determined. Examination of embryos between the lengths of 6·75 and 8 mm. would decide the question, but such were not available.
2. The articulation of the anterior end of the Palato-quadrate of Amia and Lepidosteus with the cranium is preceded by a procartilaginous or cartilaginous continuity. In Polypterus the structures are in contact but not continuous.
3. No basal process of the Palato-quadrate is present in embryos of Polypterus. A small one is present in embryos of *Acipenser ruthenus* and Amia, and there is also a small basal process of the Trabecula. In Lepidosteus there is a joint between the basal process of the Trabecula and the Palato-quadrate—a joint which is preceded by a cartilaginous continuity between the two cartilages.
4. No otic process is present in embryos of Lepidosteus (*vide infra*). A small one is present in embryos of *Acipenser ruthenus* and Amia, and possibly there is a relic of one in the adult stage of Polyodon. A large otic process nearly reaching the auditory capsule is present in young embryos of Polypterus. This diminishes in subsequent stages and forms a slight posterior process of the Palato-quadrate. As regards Lepidosteus, PARKER described an otic process in embryos from his third stage (= 15 or 16 mm.) onwards. But it is doubtful whether this is really an otic process, for he described it as triangular and projecting horizontally backwards towards the Hyomandibula and not as ascending towards the auditory capsule. Further, VEIT did not describe any otic process in the embryos he investigated, the oldest of which was one of 20 mm. Nor have I seen one in embryos up to the stage of 22 mm. Thus the post-articular process of the Palato-quadrate of the adult stage of Polypterus is a relic of an otic process, that of Lepidosteus not.

Hyoid Bar.—In the 6·75-mm. embryo (fig. 40) the hyoid bar is a fairly straight procartilaginous tract. Its dorsal end is continuous with the procartilaginous otic capsule. Its lower end is free, there being as yet no Basibranchiale.

In the 8-mm. embryo (figs. 51 and 52) the hyoid bar is separated into parts and partially chondrified. It consists, from above downwards, of the Hyosymplecticum, Interhyale and Keratohyale. The upper end of the Hyosymplecticum articulates with the auditory capsule. It has a posterior opercular process. Its lower end is not continuous with the Palato-quadrate. The lower end of the Keratohyale is free, there being no Basibranchiale.

---

* Unpublished.

In the 9·3-mm. embryo (figs. 53, 54 and 55) the lower end of the Hyosymplecticum is cartilaginously continuous with the Palato-quadrate. A Hypohyale is now separated from the lower end of the Keratohyale.

In the 30-mm. embryo, as described by BUDGETT, the Hyosymplecticum is again free from the Palato-quadrate. I have previously (1926) described the subsequent stages in the development of the Hyosymplecticum.

Comparison of the developmental stages of the hyoid bar in Polypterus with these in Acipenser, Amia and Lepidosteus shows that whereas the Hyosymplecticum persists in Polypterus and Amia, it separates into Hyomandibula and Symplecticum in Acipenser and Lepidosteus. HENDERSON* has found that the lower end of the Hyosymplecticum of embryonic stages of Acipenser, Amia and Lepidosteus is temporarily continuous with the Palato-quadrate, just as in Polypterus, and KINDRED found the same condition in embryos of Syngnathus.

The Masticatory Muscles of Polypterus, Amia and Lepidosteus.

Polypterus.—The masticatory muscles of the adult stage of Polypterus were first described by POLLARD (1892), subsequently by LUTHER (1913), and lastly by ALLIS (1922), but nothing has been published concerning their development.

The synonyms are as follows:—

In this paper,	
Constrictor i dorsalis	Separated, in the adult, into Spiracularis Dilatator operculi and Levator arcus palatini (LUTHER). ALLIS additionally described a Protractor hyomandibularis.
Adductor mandibulæ of	
Adductor m. externus	Masseter, POLLARD, LUTHER, 1913. Adductor m. externus and Adductor m. posterior, LUTHER, 1914. Adductor mandibulæ, ALLIS.
Adductor m. medius	Temporalis, POLLARD, LUTHER, 1913, ALLIS. Pseudo-temporalis, LUTHER, 1914.
Adductor m. internus	Pterygoideus, POLLARD, LUTHER, ALLIS.
Adductor m. intramandibularis	*Sic*, LUTHER. Mandibular division of Adductor mandibulæ, ALLIS.

LUTHER included the Adductores m. medius and internus of my nomenclature as parts of his Adductor m. internus. These and the Adductor m. externus were held to

---

* Unpublished.

be differentiations of an Adductor mandibulæ. He stated that "der nahe Anschluss des Palatoquadratbogens an das Kranium gab dem M. adductor mandibulæ Gelegenheit einen Teil seines Ursprungs auf das Kranium zu verlegen." By "Adductor m. posterior" he indicated fibres of the Adductor m. externus which, posterior to the N. mandibularis v, pass from the Quadrate to the lower jaw partly directly, partly via insertion into the tendon of (his) Adductor m. internus. He added that these fibres are continuous with those of the Adductor m. externus, so that no division is possible.

In a 6·75-mm. embryo (figs. 40 and 41) the primordium of the masticatory muscles has separated into the Constrictor i dorsalis and Adductor mandibulæ. Neither muscle has any "origin." The former is inserted into the Quadrate portion of the mandibular bar and the latter into its Meckelian portion.

In an 8-mm. embryo (figs. 42, 51 and 52) the Constrictor i dorsalis passes from the auditory capsule to the Quadrate. The Adductor mandibulæ is partially separated into external, middle and internal parts. Its lower part, near its insertion into Meckel's cartilage, is single, no distinction being possible. As the muscle is traced upwards it separates into three parts. The Adductor m. externus part extends upwards and backwards—as far as the otic process of the Quadrate. The Adductor m. medius part extends upwards and outwards outside the Gasserian ganglion. The Adductor m. internus part extends upwards, outside the Palato-quadrate and Trabecula.

In a 9·3-mm. embryo (figs. 53 and 54) the Constrictor i dorsalis has extended backwards to the Hyosymplecticum, but is as yet not separated into parts. The Adductores m. externus, medius and internus are fully separated. The upper end of the Adductor m. externus has extended backwards nearly to the Hyosymplecticum. The Adductor m. medius has, as yet, no origin. The Adductor m. internus arises from the Trabecula. The lower ends of these two muscles unite and pass downwards and forwards, as the Adductor m. intramandibularis, to Meckel's cartilage.

The earliest stage above described shows that the primordium of the masticatory muscles separates into Constrictor i dorsalis and Adductor mandibulæ before the palatal process develops—an occurrence which suggests that the delay in the development of the process is a secondary phenomenon.

Amia.—The masticatory muscles of Amia were first described by McMurrich (1885), then by Allis (1897), and subsequently by Luther (1913 and 1914).

The synonyms are :—

In this paper,

Constrictor i dorsalis of		
Levator arcus palatini ..	.. *Sic*, Allis, Luther	L.A.P.^{1}, McMurrich.
Dilatator operculi ..	.. *Sic*, Allis, Luther	
Adductor mandibulæ of		
Præorbitalis	.. *Sic*, Luther. L.A.P.^{4}, McMurrich. L.M.S.^{3}, Allis.	

Adductor mandibulæ of	
Nasalis	*Sic*, Luther. L.A.P.^{5}, McMurrich. L.M.S.^{4}, Allis.
Parabasalis	*Sic*, Luther. L.A.P.^{3} and L.A.P.^{2}, McMurrich. L.M.S.^{1} and L.M.S.^{2}, Allis.
Adductor m. internus	A_3, Allis, Luther.
Adductor m. medius	A_2'' and A_2''' Allis, Luther.
Adductor m. externus	A. M.^{1}, McMurrich. A_2', Allis. Masseter, Luther.
Intramandibularis	*Sic*, Luther. $A\omega$, Allis.

(In the above table L.A.P. = Levator arcus palatini, L.M.S. = Levator maxillæ superioris), A.M. = Adductor mandibulæ.

In the following year (1914) Luther stated that the Præorbitalis, Nasalis and Parabasalis were to be regarded as parts of an Adductor m. internus, the Masseter as an Adductor m. externus, and A_2'', A_2''' and A_3 of Allis as, in part, an Adductor m. posterior.

In a 6-mm. embryo (fig. 71) there is no definite evidence of the Palato-quadrate or Meckel's cartilage. The mandibular muscle-plate is a very oblique dorso-ventral structure, in which the future Constrictor i dorsalis, Adductor mandibulæ and Intermandibularis can be distinguished.

In a 7-mm. embryo (figs. 72 to 74) the Palato-quadrate and Meckel's cartilage are formed as a continuous procartilaginous mass. The mandibular muscle-plate is nearly separated into Constrictor, Adductor and Intermandibularis. The upper edge of the Adductor shows an inward projection or ridge. The R. mandibularis V (= V_3) passes down outside the Adductor.

In an 8-mm. embryo (figs. 77 to 79) the Palato-quadrate and Meckel's cartilage are beginning to chondrify. The Constrictor i dorsalis is separated from and lies behind the Adductor mandibulæ. Its lower edge is inserted into the Palato-quadrate. It has spread back, ventro-external to the 1st gill-cleft, to the Hyomandibula. The inward projection of the upper edge of the Adductor has separated and forms a longitudinal column of cells, the Palato-mandibularis. A little behind its front end (fig. 78) it shows a ventral process towards, but not yet reaching, Meckel's cartilage. The anterior end of the Adductor is single. For the greater part of its length it is separated into Adductor m. medius and Adductor m. internus.

The Constrictor i dorsalis begins to separate into Levator palato-quadrati and Dilatator operculi in the 11-mm. stage (figs. 83 and 84). They both arise from a ventro-external process of the external auditory capsule. The former passes downwards and is inserted into the posterior end of the Palato-quadrate, and additionally (in the 15-mm. stage) into the Hyomandibula. The latter passes backwards, externally to the hyomandibular part of the hyoid bar, to the skin.

The Levator mandibulæ externus grows backwards and upwards from the lower edge of the Adductor m. medius, external to the R. mandibularis V in the 9-mm. stage (fig. 82).

The Adductor m. medius at first arises exclusively from the Palato-quadrate. It begins to extend backwards, external to the Levator palato-quadrati in the 10·25-stage, and in the 12-mm. stage (figs. 85 to 88) its dorsal end is attached to the Hyomandibula posterior to the Levator palato-quadrati. There is but little evidence, even in the 20-mm. stage, of its separation into inner and outer parts such as are described by ALLIS in the adult (A_2'' and A_2''').

The Adductor m. internus arises exclusively from the Palato-quadrate up to the 20-mm. stage. In the adult, according to ALLIS, some fibres arise from the Hyomandibula.

The lower ends of the Adductores m. medius and internus do not separate, and this portion forms the Adductor m. intramandibularis of the adult, but up to the 20-mm. stage it is not marked off from the rest of the muscles by any tendinous tract.

The Palato-mandibularis remains unchanged up to the 12-mm. stage. In an embryo of 12·5 mm. (figs. 89 and 90) its hind end is attached to the Palato-quadrate. It has an anterior projection, external to the Palato-quadrate, and the muscle, Γ-shaped in the 8-mm. stage, has now become T-shaped. The posterior limb is the Palato-mandibularis, the anterior limb is the Præorbitalis. This anterior projection—the Præorbitalis—has just begun to be formed in the 8-mm. stage (*vide* figs. 77 to 79, though not very obvious in the model (figs. 96 to 98). Its great development occurs between the 9- and the 10·25-mm. stages. In an embryo of 15 mm. the hind end of the Palato-mandibularis has grown backwards to the floor of the auditory capsule, internal to the Levator palato-quadrati, and the muscle has become the Parabasalis (figs. 91 to 93). The common, ventrally directed tendon of the Parabasalis and Præorbitalis now reaches Meckel's cartilage (fig. 94). The Nasalis is being proliferated from the anterior end of the Præorbitalis. In the 20-mm. stage the Præorbitalis and Parabasalis are separate.

Lepidosteus.—The masticatory muscles were described by LUTHER (1913 and 1914).

The synonyms are as follows :—

In this paper,	LUTHER, 1913.
Constrictor i dorsalis	Constrictor i dorsalis of Levator arcus palatini. Protractor hyomandibularis. Dilatator operculi.
Præorbitalis superficialis and profundus.	Pars præorbitalis superficialis and profundus.
Palato-mandibularis major and minor.	Adductor m. anterior major and minor.
Adductor mandibulæ	Pars postorbitalis.

LUTHER described these muscles in 1913 and gave admirable illustrations of them. He depicted the R. mandibularis V (= V_3) as perforating the insertion-tendon of the Pars postorbitalis, so that the lower part of the tendon is external to the nerve.

In the following year he stated that these portions of the Adductor can be separated into three categories:—

1. Adductor m. internus, *i.e.*, his Pars præorbitalis and Adductor m. anterior, major and minor.
2. Adductor m. posterior—the greater part of his Postorbitalis.
3. Adductor m. externus, *i.e.*, the part of the insertion-tendon of his Postorbitalis which lies external to the R. mandibularis V.

The initial stages of the development of the masticatory muscles of Lepidosteus are similar to those of Amia (*cp.* figs. 71 and 114). In a 10·25-mm. embryo (figs. 116 to 121) the Palato-quadrate is formed in a procartilaginous state. Meckel's cartilage is continuous with it. The primordium of the masticatory muscles is a very oblique, almost horizontal, position. The Constrictor i dorsalis is continuous with the Adductor mandibulæ and extends back ventro-external to the 1st gill-cleft. The Adductor mandibulæ is not separated into parts. It shows an internal projection from its dorsal edge. The R. mandibularis V passes down outside the Adductor. The condition is thus similar to that of a 7-mm. embryo of Amia. The internal projection or ridge of the upper end of the Adductor is slightly more marked in its anterior part.

In a 13·5-mm. embryo (figs. 127 and 128) the cartilages are chondrified and Meckel's cartilage is separated from the Palato-quadrate. The Constrictor i dorsalis is separate from the Adductor mandibulæ. It is partially separated into an anterior part, the Levator arcus palatini inserted into the Palato-quadrate, and a posterior part, which spreads back as a flat plate external to the Hyomandibula. This posterior part is the primordium of the Protractor hyomandibulæ and Dilatator operculi. The ridge of the upper edge of the Adductor mandibulæ is separate and forms a longitudinal flat structure. Its hinder part is dorsal to the Adductor. Its anterior end has extended forwards outside and slightly above the level of the Palato-quadrate, so that the muscle has become T-shaped. The posterior limb is the primordium of the Palato-mandibularis, the anterior that of the Præorbitalis. The R. mandibularis V (= V_3) passes obliquely downwards and forwards outside the Adductor mandibulæ.

In an 18·5-mm. embryo (figs. 131 to 137) the Adductor mandibulæ is inserted on the inner side of the coronoid process of Meckel's cartilage and the dorsal surface of Meckel's cartilage. These insertions are continuous. The T-shaped muscle has separated into the Præorbitalis and Palato-mandibularis. The apex of the Præorbitalis has extended upwards to the chondrocranium. It is inserted into Meckel's cartilage internal to the insertion of the Adductor mandibulæ. The Palato-mandibularis arises from the Palato-quadrate and is inserted into the apex of the coronoid process of Meckel's cartilage. The R. mandibularis passes obliquely downwards on the outer surface of the Adductor mandibulæ.

In an adult specimen of the fish, measuring 8 cm. in length, examined by serial transverse sections, the state of the Adductor mandibulæ is similar to that of the 18·5-mm. embryo, and the R. mandibularis V similarly passes downwards external to the muscle. It does not perforate either the muscle or its insertion-tendon. The Præorbitalis has greatly extended. Its origin reaches back to the auditory capsule. It has separated into a superficial and deep portion. The Palato-mandibularis has separated into major and minor portions. The condition is thus similar to that described by LUTHER, except that the R. mandibularis V does not perforate either the Adductor mandibulæ or its insertion-tendon.

The evidence adduced shows that the opinion of ALLIS that the Adductores m. medius and internus of Polypterus, and the Præorbitalis, Nasalis and Parabasalis of Amia, are derivatives of the Constrictor i dorsalis is not tenable, and it confirms that of LUTHER. It further shows that there is no Adductor m. externus in Lepidosteus.

No evidence was found to confirm LUTHER'S attempt to establish the existence of an Adductor m. posterior. It is a theoretical concept without any objective reality behind it. The muscles lie across the course of the R. mandibularis V and are continuous structures.

In Amia and Lepidosteus, but not in Polypterus, an internal ridge develops from the upper edge of the Adductor mandibulæ, separates off, and becomes the Palato-mandibularis. Its anterior end grows downwards to Meckel's cartilage in Amia, gains attachment to the coronoid process of Meckel's cartilage in Lepidosteus. The primary origin from the Palato-quadrate is retained in Lepidosteus, and the muscle subsequently separates into two. The primary origin is lost in Amia, the hind end of the muscle grows backwards to the floor of the auditory capsule and it becomes the Parabasalis. The Præorbitalis is an upward and forward growth from the anterior end of the Palato-mandibularis in Lepidosteus, a forward growth in Amia. The origin of the Præorbitalis from the chondocranium in Lepidosteus subsequently extends backwards. The Nasalis of Amia is subsequently separated from the anterior end of the Præorbitalis.

The Adductor mandibulæ of Lepidosteus remains simple; that of Polypterus and Amia separates into Adductores m. medius and internus, and the Adductor m. externus is proliferated from the lower edge of the former and grows upwards and backwards outside the R. mandibularis V. The Adductor m. medius of Polypterus remains small, whilst that of Amia enlarges and extends backwards to the Hyomandibula. The Adductor m. intramandibularis of Polypterus and Amia is the partially separated ventral portions of the Adductores m. medius and internus.

The Ventral Mandibular and Hyoid Muscles.

The adult anatomy of these muscles was investigated by DANFORTH and LUTHER in Polyodon; by VETTER, RUGE, ALLIS, LUTHER and KURZ in Acipenser; by POLLARD, HOLMQVIST, LUTHER and ALLIS in Polypterus; by MCMURRICH, ALLIS and HOLMQVIST in Amia, and by HOLMQVIST in Lepidosteus.

Differences of opinion have arisen in regard to the derivation of a muscle which occurs in Teleostei and was called "Genihyoïde" by Cuvier, and which is also present in Polypterus and Amia. In these two Ganoids I call it "Interhyoideus."

According to Holmqvist (1911) the Interhyoideus is derived from the hyoid portion of the primitive Constrictor ventralis. On the other hand, Allis (1919) was of opinion that it is derived from the primitive Intermandibularis. This muscle, according to him, underwent a longitudinal cleavage from its dorsal end downwards, the dorsal end of one of these two parts acquiring insertion on the mandible and the dorsal end of the other part insertion on the Keratohyale.

Neither writer made any observations on the development of the muscle. Their expressions of opinion were merely inferences from adult anatomy, without any verification. Allis's account of the development, quoted above, was purely hypothetical and not based on observation.

It will be seen later that the phenomena of development show that the theory of Holmqvist is correct. I do not, however, follow his nomenclature exactly, for he employed the name "Protractor hyoidei" in two senses—to denote a simple muscle of hyoid origin (which I call "Interhyoideus"), *e.g.*, in Polypterus, Amia, Albula, Amiurus, Silurus; and also to denote a compound muscle formed from the Interhyoideus and Intermandibularis posterior, *e.g.*, in Blennius, Caranx, Callionymus, Pleuronectes, Gadus. I think it makes matters clearer to employ two names, according to the derivation of the muscle, and to limit that of "Protractor hyoidei" to the compound muscle.

The primary condition of the hyoid musculature in fishes is a dorso-ventral muscle-sheet—the Constrictor hyoideus. This persists in Selachii and Dipnoi, whereas in Teleostomi it becomes partially or fully separated into upper and lower parts. The lower part may be called Constrictor hyoideus ventralis. It may persist as a simple sheet, *e.g.*, in Polyodon and Lepidosteus. In general, however, in Teleostomi, an anterior part—the Interhyoideus—separates off from the remainder. The posterior part may persist as such, and is termed Hyohyoideus, *e.g.*, in Amia, Salmo, Clupea, but in Teleostei it generally separates into a Hyohyoideus superior and Hyohyoideus inferior.

Polyodon.—The synonyms are :—

Danforth ..	Geniohyoid, anterior part of	Geniohyoid, posterior part of.
Luther ..	Intermandibularis (C_1 mv)	Hyohyoideus ($C_{1 \text{ and } 2}$ vh and $C_{1 \text{ and } 2}$ vop).
Norris ..	Intermandibularis	Geniohyoideus.
In this paper	Intermandibularis	Constrictor hyoideus ventralis.

In Polyodon the Intermandibularis and Constrictor hyoideus ventralis do not overlap. The former is attached laterally to Meckel's cartilage and the dentary bone, and passes inwards to a median raphé. The Constrictor hyoideus ventralis arises from the Keratohyale, Interhyale and the skin beneath the ventral margin of the branchiostegal ray. The fibres pass downwards and forwards to the middle line.

Innervation.—The Intermandibularis is innervated by the R. mandibularis V, and the Constrictor hyoideus ventralis by the R. hyoideus vii (DANFORTH and NORRIS).

Acipenser.—The synonyms are :—

VETTER ..	Mylohyoideus Cs$_6$	Cs 1, 2, 3 ..	Cs$_5$	Cs$_4$.
RUGE ..	.. ..	C$_2$ mv	C$_2$ hv.	
ALLIS ..	Cs$_6$ ..	Cs$_{1 \text{ and } 2}$ s. Geniohyoideus superior	Hyohyoideus inferior (in part at least)	
LUTHER ..	Intermandibularis (C$_1$ mv)	Cs$_{1 \text{ and } 2}$ s. Constrictor 1 and 2 ventralis anterior	C$_{1 \text{ and } 2}$ vh s. Protractor hyoidei	Cs$_{3 \text{ and } 4}$ s. Constrictor 1 and 2 ventralis posterior.
In this paper	Intermandibularis	Interhyoideus ..	Interhyoideus dorsalis	Hyohyoideus.

The *Intermandibularis* is attached laterally to the jaw and passes inwards to the fascia covering the anterior end of the Geniobranchialis. The *Interhyoideus* and *Hyohyoideus* form a continuous sheet ventrally. They are slightly separable laterally. The lateral edge of the Interhyoideus is attached by fascia to the Suborbitale and the subcutaneous tissue at the side of the head. The Hyohyoideus is attached to a fascia covering the Symplecticum and Hyomandibula and the inner side of the 3rd opercular plate. The *Interhyoideus dorsalis* is a narrow muscle dorsal to the Interhyoideus. It is attached laterally to the Keratohyale and passes inwards to the middle line. There is a ventral median raphé common to all three muscles.

Innervation.—The Intermandibularis is innervated by R. mandibularis V. The Interhyoideus, Interhyoideus dorsalis and Hyohyoideus are innervated by branches from an anastomosis between the Vth and VIIth nerves (LUTHER).

I find that in an 11-mm. embryo of *Acipenser ruthenus* the Intermandibulare and Constrictores hyoidei ventrales form a nearly continuous sheet of transverse fibres on the ventral side of the head, extending from just behind Meckel's cartilages backwards into the opercular folds.* It has no definite lateral attachments.

In a 15-mm. embryo (figs. 33–36) the Intermandibularis and Constrictor hyoideus ventralis are separate and distinct. The lateral edge of the former is attached to Meckel's cartilage and the dentary bone, which has now developed. Its inner end partly abuts against the side of the Geniobranchialis and is partly continuous with that of its fellow. The lateral edge of the anterior part of the Interhyoideus extends outwards

---

* It is possible that this condition is the persisting one in *Acipenser ? dabryanus* from the Yangtse River, for KURZ stated that there is no separate Intermandibularis in that species, and that the Constrictor superficialis is innervated by both Vth and VIIth nerves.

towards the lateral edge of the Symplecticum. A little farther back a layer of fibres is partially separated from the dorsal surface of the sheet and forms the Interhyoideus dorsalis. Its lateral edge is attached to the Keratohyale. The Interhyoideus dorsalis is delaminated from nearly the whole antero-posterior length (= 0·34 mm.) of the Constrictor hyoideus ventralis, there being only a short portion (0·04 mm.) in front, and a longer portion (0·09 mm.) behind, in which the constrictor fibres consist of only one layer. The posterior fibres of the Constrictor hyoideus ventralis spread upwards in the opercular fold (Hyohyoideus).

In a 30-mm. embryo the lateral edge of the fore part of the Constrictor hyoideus ventralis spreads upwards outside Meckel's cartilage and the hind end of the Palatoquadrate, but as yet there is no Suborbitale developed. The primordium of the opercular plates has developed in the opercular fold.

The Interhyoideus is thus the partially separated anterior portion of the Constrictor hyoideus ventralis. The Interhyoideus dorsalis is delaminated from the greater part of the Constrictor hyoideus ventralis, and is not separated from either its anterior or posterior edge, as the names given to it by LUTHER and by ALLIS suggest—hence this new name.

In *Polypterus* the synonyms are :—

POLLARD ..	Intermaxillaris anterior	Intermaxillaris posterior	Mantle muscle. Muscle of jugular plate.
HOLMQVIST (1910).	Intermandibularis ..	Protractor hyoidei	Hyohyoideus.
LUTHER ..	Intermandibularis (C_1 mv).	C_2 vh.	
ALLIS ..	Geniohyoideus inferior	Geniohyoideus superior	Hyohyoideus inferior.
In this paper	Intermandibularis ..	Interhyoideus ..	Hyohyoideus.

The muscles have been described and figured by the above authors. The *Intermandibularis* is attached laterally to Meckel's cartilage and the Spleniale. It passes inwards and slightly backwards to a median raphé. The *Interhyoideus* is attached laterally to the Keratohyale, and passes inwards and forwards, dorsal to the Intermandibularis, to a median raphé. The *Hyohyoideus* arises in the gill-cover and passes inwards and forwards at the postero-median edge of the Interhyoideus to a median raphé.

Innervation.—The Intermandibularis is innervated by the R. mylohyoideus v. The branch which innervates the Interhyoideus either anastomoses with, or lies close to, the R. hyoideus vii. The Hyohyoideus is innervated by the R. hyoideus vii (ALLIS).

In an 8-mm. embryo* (fig. 52) the Intermandibularis is attached to Meckel's cartilage and passes inwards and slightly backwards to a median raphé. The Constrictor hyoideus

---

* A slightly younger embryo, *e.g.*, one of 7·5 mm., was, unfortunately, not available.

ventralis forms a continuous sheet. Its posterior part (Hyohyoideus) spreads upwards in the opercular fold. Its anterior part (Interhyoideus) is attached laterally to the Keratohyale. Its front edge just overlaps the posterior edge of the Intermandibularis—by eight 5-μ sections = 0·04 mm.

In a 9·3-mm. embryo the conditions are similar but for the fact that the overlap of the Interhyoideus part of the Constrictor hyoideus ventralis and the Intermandibularis is greater. It amounts to 23 sections = 0·115 mm.

In a 75-mm. embryo the Interhyoideus and Hyohyoideus have become separated. The overlap of the Intermandibularis by the former is 1·6 mm.

In *Amia* the synonyms are :—

McMurrich	Intermandibularis	Superficial portion of Geniohyoid	Posterior portion of Geniohyoid	Hyohyoideus.
Allis ..	Intermandibularis	Geniohyoideus inferior	Geniohyoideus superior	Hyohyoideus inferior.
Holmqvist	Intermandibularis i	Intermandibularis ii	Protractor hyoidei	Hyohyoideus.
Norris ..	Intermandibularis i	Intermandibularis ii	Geniohyoideus.	
In this paper	Intermandibularis anterior	Intermandibularis posterior	Interhyoideus	Hyohyoideus.

The anatomy of these muscles was given in detail by McMurrich and by Allis. The only points to which attention may be called are (1) the Intermandibularis consists of two portions—anterior and posterior ; (2) the anterior portions of the Interhyoidei are dorsal to the Intermandibulares posteriores ; (3) the median edge of the Interhyoideus overlaps superficially that of the right one ; (4) the anterior portion of the Hyohyoideus is dorsal to the Interhyoideus.

Innervation.—The Intermandibularis anterior and posterior are innervated by the R. mandibularis V, the Interhyoideus by branches given off from an anastomsis between the R. mandibularis V and the R. hyoideus vii, and the Hyohyoideus by the R. hyoideus vii (Norris).

In a 6·5-mm. embryo (fig. 99) the ventral ends of the mandibular and hyoid muscle-plates are continuous. In one of 7·5 mm. (fig. 100) they have become separated, and the ventral portion of the mandibular muscle-plate (the future Intermandibularis) has spread out a little.

In one of 8 mm. (fig. 101) Meckel's cartilage and the hyoid bar have developed. They are in a procartilaginous condition. The ventral portion of the mandibular muscle-plate has separated from the portion above (the Adductor mandibulæ) and forms the Intermandibularis. The hyoid muscle-plate has separated into upper and lower portions—the lower is the Constrictor hyoideus ventralis. The ventral end of this forks—the anterior portion is the primordium of the Interhyoideus and the posterior portion is that of the Hyohyoideus.

In an embryo of 9 mm. (fig. 102) the Intermandibularis has separated into Intermandibularis anterior and posterior. The median ends of the Interhyoideus and Hyohyoideus have grown inwards and each meets its fellow in the middle line. The Interhyoideus is posterior to the Intermandibularis posterior.

In an embryo of 10·5 mm. (fig. 103) the Interhyoideus overlaps the Intermandibularis posterior, and the condition approximates to that of the adult.

Lepidosteus.—The synonyms are as follows :—

HOLMQVIST	Intermandibularis	Protractor hyoidei	Hyohyoideus.
NORRIS	Intermandibularis	Geniohyoideus	Hyohyoideus.
In this paper	Intermandibularis	Constrictor hyoideus ventralis	

In the adult the Intermandibularis is attached to the whole length of the jaw and passes inwards to a median raphé. The Constrictor hyoideus ventralis arises partly in the opercular fold and partly from the Keratohyale. The posterior fibres pass downwards and inwards almost transversely, those in front more and more obliquely forwards, so that the most anterior fibres are almost longitudinal in direction. Most fibres are inserted into the median raphé, but some of the anterior ones pass to the floor of the mouth.

HOLMQVIST, followed by NORRIS, applied two names to the Constrictor hyoideus ventralis (*vide* list of synonyms given above) ; but the former described and depicted a continuous sheet of muscle-fibres, and I also find this. NORRIS did not describe the muscle—only the innervation.

Innervation.—The Intermandibularis by the R. mandibularis V, the Constrictor hyoideus ventralis from an anastomosis between the R. hyoideus vii and a branch of the R. mandibularis V (NORRIS).

In a 9-mm. embryo (fig. 115) the mandibular and hyoid bars are not yet formed. The mandibular muscle-plate is a continuous structure. The hyoid muscle-plate is separated into dorsal and ventral parts. The lower ends of the mandibular muscle-plate and the Constrictor hyoideus ventralis are continuous.

In a 10·5-mm. embryo (fig. 124) the primordia of the Palato-quadrate, Meckel's cartilage and the hyoid bar are developed. The Intermandibularis is separated from the Adductor mandibulæ and its inner end is in contact with that of its fellow, so that there is a sheet of transverse fibres between the two Meckel's cartilages. The lower end of the Constrictor hyoideus ventralis is separated from the Intermandibularis. Its lower end does not meet that of its fellow. Its front edge overlaps the Intermandibularis by four sections = 0·02 mm.

In a 12-mm. embryo (fig. 126) the ventral end of the Constrictor hyoideus ventralis meets that of its fellow. Its anterior edge overlaps the posterior edge of the Intermandibularis by a distance of 0·11 mm. In an embryo of 19 mm. the overlap has increased to 0·39 mm. This indicates that the overlap of the two structures begins to occur before the Constrictor hyoideus ventralis meets its fellow.

The above-described observations show that :—

1. The most primitive condition of the ventral mandibular and hyoid muscles of Ganoids is present in Polyodon, where both Intermandibularis and Constrictor hyoideus ventralis are simple and do not overlap.
2. In Acipenser, similarly, there is no overlapping of the Intermandibularis and Constrictor hyoideus ventralis. There is a partial separation of the latter into Interhyoideus and Hyohyoideus. An Interhyoideus dorsalis is proliferated from the dorsal surface of the Constrictor hyoideus ventralis. This muscle has no homologues in other Teleostomi.
3. In Lepidosteus, Polypterus and Amia the Intermandibularis and Constrictor hyoideus ventralis at first do not overlap, *i.e.*, the condition is similar to that of Polyodon and Acipenser. They subsequently do so. This overlapping is brought about by the Constrictor hyoideus ventralis extending forwards dorsal to the Intermandibularis. Of these three Ganoids the simplest condition is present in Lepidosteus, where both Intermandibularis and Constrictor hyoideus ventralis are undivided. In Polypterus and Amia the anterior part of the Constrictor hyoideus ventralis forms the Interhyoideus whilst the posterior part forms the Hyohyoideus.
4. The Intermandibularis is simple and of considerable antero-posterior length in Polyodon and Lepidosteus. It is very short in Acipenser, in relation to the almost transversely directed jaws. In Amia it separates into an Intermandibularis anterior (without any median raphé) and an Intermandibularis posterior (with a median raphé). In Polypterus it is simple. Comparison of Polypterus with other Ganoids suggests that the muscle is possibly homologous with only the posterior part of the Intermandibularis of Polyodon and Lepidosteus and with the Intermandibularis posterior of Amia. In the 8·0- and 9·3-mm. embryos there is, however, no evidence of any (subsequently atrophying) Intermandibularis anterior, but this is not conclusive evidence against its existence in ancestors.*

The innervation of these muscles appears nearly or quite constant. The Intermandibularis, whether simple or separated into two parts, is innervated by the R. mandibularis V ; the Constrictor hyoideus ventralis or Interhyoideus and Hyohyoideus, by either the R. hyoideus vii (Polyodon) or from an anastomosis between the R. hyoideus vii and the R. mandibularis V (Acipenser, Polypterus, Lepidosteus).

* A good instance of how a muscle can disappear without leaving any trace even during developmental stages is found in Lepidosteus. No trace of a Geniobranchialis (Branchio-mandibularis of VETTER) is present in embryos. I may add that I have practically a complete set of embryos of the stages in which it would be present if developed at all. The presence, however, of the muscle in Polyodon, Acipenser, Polypterus and Amia shows that it must almost certainly have been present in ancestors of Lepidosteus.

The Interhyoideus of Teleostei.

Admirable descriptions of the many varieties of the Interhyoideus and Protractor hyoidei of Teleostei were given by Holmqvist and added to by Dietz. The problem is as to the development of this muscle. The case of the two Siluroids, Silurus and Amiurus, is taken first. In them there is a simple Interhyoideus, not a Protractor hyoidei.

The synonyms for these two fish are :—

McMurrich	Intermandibularis	Geniohyoideus	Lower or anterior portion of Hyohyoideus	Upper or posterior portion of Hyohyoideus.
Juge ..	M. intermandibulaire	M. geniohyoïdien	Hyohyoïdien inférieur	Hyohyoïdien supérieur.
Holmqvist	Intermandibularis i	Intermandibularis	Protractor hyoidei.	
Allis ..		Geniohyoideus	Hyohyoideus superficialis	Hyohyoideus superior and inferior.
In this paper	Intermandibularis anterior	Intermandibularis posterior	Interhyoideus	Hyohyoideus superior and inferior.

The *Intermandibularis anterior* is a small muscle just behind the symphysis of the jaw. The *Intermandibularis posterior* is attached anteriorly to the jaw and a median aponeurosis. It passes backwards and outwards and is attached posteriorly to the Kerato- and Epi-hyale. In Amiurus it lies lateral to the Interhyoideus, in Silurus lateral and ventro-lateral to it. The *Interhyoideus* arises in Amiurus from the Kerato- and Hypohyale, in Silurus from the Kerato- and Epi-hyale. It passes inwards and forwards to a median aponeurosis separating it from its fellow, in Silurus also by a tendon to the Hypohyalia of the same and opposite sides. The *Hyohyoideus* arises from the inner surface of the Operculum and Interoperculum and passes down behind the hyoid bar. It is interrupted, or segmented, by attachment to the branchiostegal rays. From the last ray the fibres pass to a median ventral aponeurosis, *i.e.*, it consists of a Hyohyoideus superior and inferior. In Silurus the postero-median edge of the Interhyoideus is not fully separated from the Hyohyoideus inferior.

Holmqvist stated that the Juge's "Hyohyoïdien supérieur," in that it passes to the ventral median line, is equivalent to the Hyohyoideus superior and Hyoideus inferior of Vetter's terminology, so that Juge's "Hyohyoïdien inférieur" was wrongly so named. He came to the conclusion that the "Geniohyoideus" of McMurrich and Juge is really an Intermandibularis posterior, and that the muscle called "lower or anterior portion of the Hyohyoideus" by McMurrich and "Hyohyoïdien inférieur" by Juge is a Protractor hyoidei.

Innervation.—The Intermandibulares anterior and posterior are innervated by the R. mandibularis V, the Interhyoideus and Hyohyoideus by the R. hyoideus vii (McMurrich, Juge, Allis). The Interhyoideus of Silurus is innervated by a branch of the R. hyoideus vii which passes down internal to the upper branchiostegal rays and then forwards between the 6th and 7th (Juge) or between the 7th and 8th (Allis) rays, counting from below upwards. The exact course of the R. hyoideus vii in Amiurus was not given either by Wright or by Allis. The former merely stated that it runs along the posterior border of the Keratohyale.

In regard to the development of the Interhyoideus, Allis stated that it is a most improbable assumption that the primitive Hyohyoideus separates into superficial and deeper portions before the branchiostegal rays are developed, and as "quite certain that but a single section of the primitive constrictor of the hyal arch passed outwards between the branchiostegal rays to form the Hyohyoideus superficialis" (my Interhyoideus).

In regard to this I would remark: (1) No embryological investigations were made by Allis to ascertain whether this method of development really occurs. (2) The path of the R. hyoideus vii found by Juge and Allis in Silurus is not constant in Teleostei. Holmqvist (in a paper, too, quoted by Allis) had depicted the nerve in Gymnarchus passing down internal to all the branchiostegal rays and then forwards to the muscle. I find a similar course of the nerve in a 12-mm. embryo of Amiurus. These observations on Gymnarchus and Amiurus undermine the very foundations on which Allis's theory was based. (3) Investigations on the development of the muscles show that the theory does not hold for Amiurus. The branchiostegal rays are present in embryos of that fish from the stage of 9 mm. onwards. In an embryo of 8 mm. they are absent. In this 8-mm. embryo (figs. 138 to 143) the Hyohyoideus inferior passes to the middle line below and a little in front of the lower portion of the hyoid bar. (In this bar the Hypohyale is not yet separated from the Keratohyale.) The Interhyoideus passes forwards and inwards, and ends in a fine tendon which joins its fellow in the middle line.

The Intermandibularis is separated into anterior and posterior portions. The former passes transversely inwards and joins its fellow. The Intermandibularis posterior is fan-shaped. The most anterior fibres pass inwards and slightly backwards, and join its fellow in a median raphé. Those next behind pass to the tendon of the Interhyoideus. The most posterior fibres pass backwards and outwards. They do not yet meet the hyoid bar. In the 9-mm. embryo the most posterior fibres of the Intermandibularis posterior have extended backwards to the Keratohyale.

These phenomena show that (1) the Interhyoideus (Hyohyoideus superficialis of Allis) is developed before the branchiostegal rays, and (2) the portion of the Intermandibularis posterior which passes to the hyoid bar is developed relatively late. It follows from this that the Interhyoideus of Amiurus is not developed as Allis so confidently asserted, but by separation of the anterior portion of the Constrictor hyoideus ventralis, exactly as in Polypterus and Amia, and it is therefore an homologous muscle.

As stated above, the Protractor hyoidei of many Teleostei is a compound muscle, being an Intermandibularis posterior + Interhyoideus,* and the question arises whether the Interhyoideus constituent of such a muscle is developed similarly to, and is homologous with, the Interhyoideus of Amiurus. There is such a Protractor hyoidei in *Caranx trachurus,* and the development is as follows :—

In a 3·5-mm. embryo† (figs. 144 to 146) the lower end of each hyoid bar consists of Kerato- and Hypo-hyale cartilaginous elements. In front of the latter is a median basihyale. There is a ventral diverticulum or groove of the buccal cavity in front of and at the sides of the basihyale and hyoid bars. The Intermandibularis is separated into Intermandibularis anterior and posterior. The former, with its fellow, forms a transverse muscle between the anterior ends of Meckel's cartilages. The latter is a longitudinal muscle close to its fellow. It passes from Meckel's cartilage backwards to below the diverticulum above mentioned. The Constrictor hyoideus ventralis is not yet separated into the parts it will form. It passes forwards and downwards, ventrolateral to the hyoid bar. Its lower end does not meet that of its fellow, but abuts against the posterior end of the Intermandibularis posterior.

In a 5-mm. embryo (figs. 147 and 148) the Constrictor hyoideus ventralis has partially separated into an (anterior) Interhyoideus and a (posterior) Hyohyoideus. The ventral end of the former muscle meets that of its fellow in the middle line. The posterior end of the Intermandibularis posterior is attached to the ventral end of the Interhyoideus, so that a Protractor hyoidei is formed. The ventral end of each Hyohyoideus is attached by a slender tendon to the Hypohyale of the same and of the opposite side. There are no branchiostegal rays, nor are any developed in a 9-mm. embryo.

The above-described observations show that the Interhyoideus of Teleostomi, whether a simple muscle or the posterior part of a Protractor hyoidei, has a similar development from the Constrictor hyoideus ventralis, and is therefore an homologous muscle throughout the group. The theory of HOLMQVIST is thus confirmed.

The Adductores and Attractores arcuum branchialium.

The Adductores are small muscles on the inner side of the branchial bars passing from the Epi- to the Kerato-branchial cartilages. They are developed in all five branchial segments of Plagiostomi. They are not developed in Polypterus. An Adductor iv is present in *Acipenser ruthenus* and *fulvescens,* Amia and Lepidosteus. In *Acipenser sturio* they occur in the first three arches, in Polyodon in the first four.

---

* No Intermandibularis anterior was described or depicted by HOLMQVIST in Anguilla, and it seemed possible that the Protractor hyoidei of that fish was formed from an Intermandibularis and Interhyoideus. Examination of sections of 17- and 31-mm. larvæ, however, showed that an Intermandibularis anterior is present. This persists to the adult state. The Protractor hyoidei of Anguilla is thus formed, as usually, by an Intermandibularis posterior and Interhyoideus. The Hyohyoideus forms a constrictor muscle of the branchial region.

† I did not succeed in cutting exactly horizontal sections of any one of five embryos of this stage.

The problem arises as to how these muscles are developed, and whether they are homologous structures in Selachii and Ganoids. SEWERTZOFF (1923) stated that in Selachii the primordia of the branchial bars develop medial to the already-formed muscle-plates. The primordia of the bars split vertically, and the inner edges of the muscle-plates spread inwards through the clefts, which subsequently close. The parts of the muscle-plates which have so come to lie on the medial side of the bars form the Adductores.

This statement arose, I think, from employing only transverse sections to investigate the matter. The phenomena, when examined in horizontal sections, show that a different interpretation is required. In a 12·5-mm. embryo of *Scyllium canicula* the branchial muscle-plates are cylindrical epithelial columns, which are continuous below with the cœlom.* In one of 16 mm. (figs. 4 and 5) the first four columns have flattened into approximately transverse plates.

To simplify the following description I describe the occurrences in the first branchial arch; those in the second, third and fourth are similar. The afferent branchial vessel passes up behind the plate and the efferent vessel in front of it. The afferent vessel gives off capillaries which pass to the gill-filaments and return to a horizontal vessel which pierces the muscle-plate and joins the efferent vessel. There is no direct cross-channel between the afferent and efferent vessels. In an 18-mm. embryo the primordium of the branchial bar is formed on the inner side of the cross-capillary, at about the middle third of the dorso-ventral extent of the muscle-plate. The bar interrupts the continuity of the muscle-plate from within outwards. Above and below the primordium of the bar the muscle-plate is a continuous structure. The portion of the muscle-plate on the inner side of the bar is the Adductor arcus branchialis. The bar is a little more sharply defined in an embryo of 22·5 mm., and fig. 6 is taken from this.

In embryos of 28 and 32 mm. (figs. 7 to 14) the still procartilaginous bar has extended dorsally and ventrally. The dorsal extension is on both sides of the upper end of the Adductor and then upwards, inwards and backwards as a single structure. The upper end of the Adductor joins the outer part of the muscle-plate through the cleft, and a branch of the branchial nerve (in this case the IXth) passes through it downwards and inwards to the Adductor. This bifid portion of the bar corresponds to the future Epibranchial cartilage, and the part above this to the Pharyngobranchial element. The ventral extension of the bar downwards and inwards similarly occurs on either side of the ventral portion of the muscle-plate. The Arcualis dorsalis is developed from the inner edge of the upper part of the muscle-plate (figs. 7 and 8). The middle portions of the branchial bars are thus the first to develop, and in the centre of the plates. They subsequently extend dorsally and ventrally. They have a sharper, more concave, curve than the muscle-plates, and consequently—having been formed in the centre of the plates—in their dorsal and ventral extensions cut across the inner edge of the plates. They do so by extending

---

* *Vide* 'Jour. of Anat.,' vol. lx.

on both sides, front and back, of the plates, and then joining together internal to them. The Adductores are formed from the portions of the muscle-plates, which lie internal to the bars. They are not formed by the inner edges of the muscle-plates passing through longitudinal clefts in the bars.

The development of the first four branchial bars and of the related Adductores in *Acanthias vulgaris* and *Raja clavata* is similar to that of Scyllium.

The branchial bars are thus developed in the middle of the transversely broadened muscle-plates, and not on their inner sides as in Teleostomi and Dipnoi.

An Adductor v is present in Scyllium, Acanthias, Torpedo and Raja, but its development is quite different, and the muscle is not serially homologous with those of the first four arches. It is developed from the lateral edge of the anterior part of the Constrictor œsophagi. The fore part of the Constrictor œsophagi is dorso-ventrally flattened. It extends slightly farther forwards ventrally than it does dorsally in Scyllium, Acanthias (*vide* fig. 17) and Torpedo. In Raja the Constrictor extends slightly farther forwards laterally than it does above and below (*vide* fig. 18). In all four genera the Adductor v is proliferated from the outer surface of the lateral edge of the Constrictor. It passes from Epibranchiale v to Keratobranchiale v. The branch of the Vagus to the muscle does not penetrate the Epibranchial cartilage as is the case in the first four Adductores, but enters from within.

No embryos of Chlamydoselachus were available, but in a young adult of 10·1 cm. the 6th (most caudal) Adductor arc. br. is still partially continuous with the anterior end of the Constrictor œsophagi, and its nerve—a branch of the Vagus—enters it from within. The nerves to the first five Adductores perforate the epibranchial cartilages.

In a 58-mm. embryo of Heptanchus (the youngest available) the 7th (most caudal) Adductor is continuous with the anterior end of the Constrictor œsophagi, and is innervated by a branch of the Vagus which enters it from within. The nerves to the first six Adductores do not perforate the Epibranchial cartilages, but, being given off a little further ventrally, enter the muscles from without just in front of the junction of the Epi- and Kerato-branchial cartilages.

In a 13-mm. embryo of *Acipenser ruthenus* (figs. 31 and 32) the fourth branchial bar is not as yet separated into the elements it will form. Its lower part is chondrified, its upper part in a procartilaginous condition. The 4th branchial muscle-plate is separated into upper and lower portions. The former passes down into the arch and separates into external and internal fasciculi. The external fasciculus is the primordium of the Constrictor branchialis iv. The internal fasciculus, which is posterior to the upper, non-chondrified, portion of the bar, is the primordium of the Levator arcus branchialis iv and Adductor branchialis iv.

In a 15-mm. embryo (fig. 38) the Kerato- and Epi-branchialia iv are chondrified and distinct from one another. Pharyngo-branchiale iv is not yet formed. The muscles are more developed. Levator arcus branchialis iv is inserted into Epibranchiale iv, whilst Adductor branchialis iv is partly continuous with this muscle and partly arises from

Epibranchiale iv. It is inserted into Keratobranchiale iv. The Adductor branchialis iv of Amia and Lepidosteus has a similar development.

The above evidence shows that Adductor branchialis iv of Acipenser, Amia and Lepidosteus is a derivative of the Levator of that arch, and is developed behind the primordium of the Epibranchial cartilage. The development is thus quite different from that occurring in Scyllium, Acanthias, Raja and Torpedo.

The different development affords an explanation of the differences in the paths of the innervating branches of the R^{i} posttrematici of the branchial nerves. In the case of the first four Adductores of Plagiostomi (first five of Chlamydoselachus and first six of Heptanchus) the nerve enters from without, either perforating the Epibranchial cartilages or entering between the Epi- and Kerato-branchialia. In Ganoidei the nerve passes downwards behind the bar.

It results from the foregoing observations that the last (most caudal) Adductor of Plagiostomi is not serially homologous with the more anterior Adductores, and neither kind is homologous with the Adductores of Ganoidei. This is an interesting example of convergence resulting in homoplasty, as distinguished from homology, both within the group of Plagiostomi and between Plagiostomi and Ganoidei.

To mark the difference between Ganoidei and Plagiostomi, I have called the muscles of Ganoidei "Attractores."

On the Number of Branchial Segments in Polypterus.

As is well known, Polypterus has only four branchial segments, whereas other Teleostomi and Dipnoi have five. The question arises as to the explanation of this difference. In a paper published in 1920 I pointed out that the number of branchial segments may be lessened by one of two methods :—

(1) The structures of the ultimate branchial segment may be lost, *i.e.*, not fully developed or not developed at all. Evidence was given that this is the explanation of the occurrence of only four branchial segments in the majority of Amphibia, whereas there are five in Dipnoi.

(2) The branchial region may be separated into a less number of segments without the loss of any one individual segment. Evidence was given that this is the explanation of the occurrence of only three branchial segments in Necturus, whereas there are four in most other Amphibia. The same explanation probably applies to Proteus and Spelerpes.

I learnt subsequently, from the paper of VERSLUYS (1922), that a similar theory had been advanced by WELKER (1878) to account for variations in the number of spinal vertebræ. I do not know of any instance in which there is evidence of a diminution of the number of branchial segments during early stages of development by suppression of a segment between the first and last, or by fusion of any two segments.

Now, in Polypterus (1) the number of gill-clefts is only five, the last being between the

3rd and 4th branchial segments (KERR), whereas in other Teleostomi and in Dipnoi there are six, the last being between the 4th and 5th. (2) The musculature of the last (4th) branchial segment of Polypterus is similar to that of the last (5th) branchial segment of other Teleostomi and Dipnoi, and different from that of the penultimate (4th) segment of other Teleostomi and Dipnoi. Thus in Polypterus the only Coraco-branchialis is developed in the 4th branchial segment, and the Sphincter œsophagi is developed by backgrowth from Transversi ventrales iv. In other Ganoids the only Coraco-branchialis is developed in the 5th branchial segment, and the Sphincter œsophagi is developed by backgrowth from Transversi ventrales v. (3) In 6·75-, 8- and 9·3-mm. embryos of Polypterus there is no evidence of the suppression of a gill-cleft and fusion of any two segments. These phenomena suggest that the number of branchial segments in Polypterus, as compared with other Teleostomi, has been lessened by the second method mentioned above.

Similar problems arise in the case of Selachii. They were the subject of an interesting paper by VERSLUYS (1922). He came to the conclusion that the most primitive Selachian condition is one—*e.g.*, in Heptanchus—in which seven branchial bars are present, and that the change (Umbildung) from seven to six and then to five bars cannot have taken place from behind forwards, for the complex of the last two bars, musculature and shoulder-girdle, remains unchanged.* The transformation must have occurred in the middle portion of the branchial region, either by a not specially differentiated bar disappearing, or by the development of three arches, and finally two arches, in place of four.

The phenomena may, I think, be explained by a very different theory. It is to be observed that Holocephali, Teleostomi other than Polypterus, and Dipnoi have five branchial segments, and that each of these phyla is more primitive than Selachii in various particulars, *i.e.*, did not arise from Selachii. This gives rise to the supposition that the primitive Selachian stock also had only five branchial segments, and that when, as in Chlamydoselachus, Hexanchus and Heptanchus, more are present, this is a secondary condition.

Now the observations of VERSLUYS render it very improbable that additional segments have been added on to the hind end of the branchial region in these Selachii. The theory which I have advanced to account for the diminished number of branchial segments in Polypterus, as compared with other Teleostomi, and in Necturus (and probably also Proteus and Spelerpes), as compared with other Urodela, may be applied in inverse fashion to account for the increased number of branchial segments in Chlamydoselachus, Hexanchus and Heptanchus, *i.e.*, that no individual segment has been intercalated, but that the whole branchial region, which—as shown by BALFOUR—is at first part of a continuous plate of mesoderm, separates into six or seven segments instead of the usual five. This method of increase or decrease in the number of branchial

---

* To the observations of VERSLUYS may be added that the ultimate Adductor is developed from the anterior end of the Sphincter œsophagi, and not from the ultimate branchial muscle-plate (*vide* p. 65).

segments is obscured by the cephalocaudal differentiation which occurs here as in other regions of the body.*

It should be added that VERSLUYS, though taking the opposite view, admitted, at the end of his paper, the possibility, at all events in theory, of an increase in the number of branchial arches in Notidanidæ and Pliotrema.

The general problem of branchiomerism has been recently discussed by KINGSBURY (1926). It is to be noted that he only speaks of the possibility of a lessening of the number of segments by the first-described method. "It would seem necessary to assume that pouches, clefts and arches have been dropped from the caudal end of the series." Such a theory, however, does not account for the similarities between the ultimate segmental structures of related genera with different numbers ot segments.

I think that the possibility of variation in the number of branchial segments by both methods mentioned above must be admitted.

On the Mesoblast and Segmentation of the Head.

The above considerations on the number of branchial segments and the phenomena of the various methods of development of the external ocular muscles lead to a theory of the mesoblast of the head which is at variance with that which is usually accepted. It is a slightly modified version of the view which I advanced in 1911.

I may summarise v. WIJHE's theory as follows: There is in the head a series of myotomes which are serially homologous with those of the body. Each is continuous below with a lateral plate of mesoblast (Seitenplatt), and the ventral end of this with the pericardium. There is little occasion to go into details as the theory was admirably stated, with the modifications necessitated by his own investigations, by GOODRICH in 1918. But without questioning the accuracy of any of his observations, I am of opinion that a very different interpretation can be given to them.

I have shown above (pp. 45–46) that the theory will not hold for the mandibular and hyoid segments, and now pass on to consider the branchial segments. It might be expected, if the branchial muscle-plates are the lateral plates of the postotic somites or myotomes, that they would be innervated by the same nerves, but this is not so. The muscles developed from the branchial muscle-plates (with exception of the Coracobranchiales of Selachii) are innervated by the IXth and Xth cranial nerves, while the muscles developed from postotic spinal myotomes are innervated by spinal nerves.

Again, it might be expected that the branchial muscle-plates would be continuous with the postotic spinal somites or myotomes, at least in early stages, just as are the mandibular and hyoid muscle-plates of Selachian embryos with the primordia of Obliquus superior and Rectus externus.

Now GOODRICH stated that "the fourth somite," *i.e.*, the first postotic somite, "is at first distinctly connected with the mesoblast of the first branchial arch, the fifth somite

---

* If segmentation were imagined to occur simultaneously in the whole extent of the branchial region, the theory suggested above becomes easier of comprehension.

with the mesoblast of the second branchial arch, and so on." He did not state—nor had any previous investigator done so—that the first postotic somite is continuous with the first branchial muscle-plate. I, too, have failed to find any continuity between the branchial muscle-plates and the postotic somites below which they lie, at any stage of Scyllium.

The conditions are very easy to determine in Selachian embryos where the branchial muscle-plates are columns of epithelial cells. I give, for instance, a figure (fig. 3) taken from a sagittal series of sections, each 5 μ thick, through a 15-mm. embryo of Scyllium in which the somite and muscle-plate are quite distinct.* Every cell visible in the part depicted is drawn. The space between the first postotic somite and the upper end of the first branchial muscle-plate is filled with loose mesenchyme.

The above statement also holds good for all the Teleostoman, Dipnoan and Amphibian embryos I have examined. It may be concluded that the postotic somites or myotomes and the branchial muscle-plates are two distinct and unrelated structures. All that GOODRICH'S statement really means is that the first branchial muscle-plate lies below the first postotic somite, and so on.

If the branchial muscle-plates were the lateral plates of postotic cephalic somites or myotomes, it might be expected that each one would constantly lie beneath a certain postotic somite, *e.g.*, that the 3rd would always lie beneath the 3rd postotic somite, and that their number would agree. Now this is not so. Thus in Ceratodus the 5th branchial muscle-plate lies beneath the 3rd postotic somite, in Scyllium it lies beneath the 5th. In Torpedo (FRORIEP) the 3rd branchial muscle-plate lies beneath the 4th postotic somite.† As regards the number, I cannot do better than quote GOODRICH: "Thus in Scyllium there would be seven cranial and eight visceral segments, in Siredon six cranial and seven visceral segments, while in Petromyzon there would be ten visceral but only four cranial segments." No explanation of these incongruities was offered by GOODRICH. The differences in number might be explained by the assumption that the hinder branchial muscle-plates are the lateral plates of myotomes not taken up into the head, but the absence of dorso-ventral agreements are inexplicable on v. WIJHE'S theory.

In the body, behind the region of the head, there is in early stages a series of myotomes each of which is continuous ventrally with a corresponding section of the cœlom. There are dorsal and ventral nerve roots for each segment. There are intersegmental skeletal elements.

Now, in Scyllium, as described by GOODRICH, there are four occipital somites. As these are traced forwards they are less and less developed and the foremost never develops muscle-fibres, never becomes a myotome, and subsequently disappears. This first somite has no corresponding nerve root, and the second, third and fourth only ventral roots. Only two occipital arches are developed, one between the fourth and fifth somites and

---

* The upper extremity of the muscle-plate has extended backwards a little. This is the beginning of the T-shaped extension which helps to form the primordium of the Cucullaris, as I have already pointed out.

† *Vide* fig. 26 in HERTWIG'S 'Handbuch,' vol. 3, part i.

the other between the third and fourth. Similar phenomena occur in the developmental stages of other vertebrates. Some instances are given in the tabular statement below.

These phenomena are related to the assimilation of spinal segments to the cranium from before backwards, in the formation of a neocranium from a palæocranium. There are other phenomena which cannot be so explained. The hypobranchial spinal musculature is not developed from the most anterior spinal somite, but from more posterior somites. Instances are given in the accompanying table showing that the first, or first two, or first three, postotic somites may take no part in the formation of this musculature. Their origin has been shifted back. The myotomic buds, or downgrowths, are not vertical. They grow in a curve concave forwards—first downwards and backwards, then downwards, and then forwards. They have, so to speak, to get round the branchial region.

Further, the most anterior somites have no corresponding section of the cœlom. Thus in Scyllium the first five, in Ceratodus the first three, postotic somites have no cœlomic portion. All these phenomena suggest that the branchial region was primitively in front of the spinal region, and subsequently extended back into it. Such posterior extension is unrelated, and was probably anterior in time, to the assimilation of somites and their skeletal elements to the cranium.

In the following table I employ a slight modification of FÜRBRINGER'S nomenclature. The capital letters signify spinal somites. The terminal ones signify occipital somites, and the initial ones occipito-spinal somites if present. The small letters signify corresponding spinal nerves, with ventral or ventral and dorsal roots.

		Occipital somites.	Occipital nerves.	Derivation of hypobranchial spinal musculature.
(SEMON, GREIL, E.)	Ceratodus	$\textcircled{VW}\,XYZ$	$\textcircled{w_v}\,x_v\,y_{v\textcircled{d}}\,z_{v\textcircled{d}}$	XYZA.
(AGAR) ..	Dipneumona	$\textcircled{X}\,YZ$	$y_v\,z_v$	YZA.
(Miss PLATT)	Necturus	$\textcircled{X}\,YZ$	Nil*	Z12 {? a few cells from Y).
(GOODRICH & E.)	Scyllium	$\textcircled{W}\,XYZ$	$x_v\,y_v\,z_v$	Z1234.
(OSTROUMOFF)	Acipenser	$\textcircled{VW}\,XYZ$	$\textcircled{w_v}\,x_{v\textcircled{d}}\,y_{v\textcircled{d}}\,z_{v\textcircled{d}}$	XYZA.

The circles indicate the somites and nerves which atrophy after formation.

(This table also illustrates the fact that, though FÜRBRINGER'S nomenclature of

---

* In Menopoma and Megalobatrachus occipital nerve z_v is formed.

assimilated spinal segments, employed above, is most useful in comparing related genera, yet it is probably misleading when different phyla are compared. Thus somite W of Scyllium is probably homologous with V of Ceratodus and Acipenser, and with X of Dipneumona and Necturus. All these somites lie under the IXth nerve.)

It has been shown above that the primitive number of branchial segments in gnathostome Vertebrates was probably five. The number may, however, undergo fluctuations, and one kind of fluctuation is by separation of the branchial region into a greater or less number of segments than usual, without the intercalation or dropping out of any one individual segment (*vide supra*).

It is not probable that a branchial region wholly in front of the body consisted of five segments, and it is possible that it was of only two segments, one innervated by the N. glossopharyngeus and the other by the N. vagus. The subsequent extension backwards into the body and increase in the number of branchial clefts and branchial segments was probably due to respiratory needs.

It may be imagined, therefore, that the mesoblast of the head was primarily separated into four or five segments—four, if only the mandibular, hyoid, 1st branchial and 2nd branchial be counted; five, if the præmandibular section be given segmental value. To each segment passed a segmental nerve, *i.e.*, the V, VII, IX, X, or these and the IIIrd. There were, correspondingly, three intersegmental gill-clefts.

Balfour showed that the mesoblast of the head of Selachian embryos becomes split into somatic and splanchnic layers, and then, by the development of gill-clefts, into a series of muscle-plates in the arches. He stated that "the fact that the walls become developed into the muscular system of the head renders it almost certain that we must regard them as equivalent to the muscle-plates of the body, which originally contain, equally with those of the head, sections of the body cavity." He also recognised the existence of postotic somites, stating that "not far behind the auditory involution there are visible at the end of period K a few longitudinal muscles, forming about three or four muscle-plates, the ventral part of which is wanting. I have not the means of deciding whether they properly belong to the head, or may not really be a part of the trunk system of muscles which has to a certain extent overlapped the back part of the head, but am inclined to accept the latter view."

These quotations, the second of which was not given by Goodrich, show that Balfour's theory is not identical with v. Wijhe's. Balfour's head-myotomes include v. Wijhe's præotic myotomes and all his Seitenplatten. The primordia of the Obliquus superior and Rectus externus of Selachii are, on Balfour's theory, merely the upper ends of the mandibular and hyoid myotomes.

If Balfour's theory be modified, as I have suggested above, by the supposition that the mesoblast of the head was originally wholly in front of that of the body, and subsequently extended backwards below the anterior spinal myotomes and separated into a greater number of segments, it will, I think, afford an adequate explanation of all the above-mentioned phenomena.

There is, however, no developmental stage in any gnathostome vertebrate in which there is no overlapping of cephalic and body mesoblast. Thus, in Scyllium (fig. 3), the foremost spinal somite lies beneath the IXth nerve. The overlapping is evident, too, in the central nervous system. The anterior occipital nerves—as shown by FÜRBRINGER—are antero-ventral or ventral to the Vagus. It must be inferred that there has been some slight forward migration of spinal myotomes as well as the much greater, though varying, backward extension of cephalic mesoblast, bringing about the overlap of these two originally serial structures.

A difference between the head and body must be shortly referred to. The myotomes of the head are at first continuous with the pericardium (*vide* fig. 1), just as are the myotomes of the body with the body cœlom. This cephalic cœlom is only ventral to the gut, whereas the body cœlom is ventral and lateral to it. The myotomes of the head extend farther ventrally, and not so far dorsally. These differences are related to the formation of intersegmental gill-clefts and to the development of the chondrocranium. The dorsal extension of the myotomes of the body is of late occurrence, does not take place in the most anterior myotome or myotomes, and is related to the development of vertebral arches. When first formed, their upper edges are not more dorsal than are those of the mandibular and hyoid myotomes.

It has been customary among recent writers to speak of the muscles of the head, other than the ocular and hypobranchial spinal muscles, as "visceral," and their motor nerves as consisting of "visceral" fibres. On the above theory this is incorrect. The muscles and their nerves are as truly somatic as are those of the body. The above statement holds for all the head-muscles other than the Constrictor pharyngis of Mammals. (The Constrictor œsophagi and the laryngeal muscles are also "visceral," but do not strictly belong to the head.)

The Ventral Muscles of the Branchial Region.

Writers on the adult anatomy of Ganoids have described the ventral muscles of the branchial region in terms of "Obliqui ventrales" s. "Interarcuales ventrales" and "Transversi ventrales." In the paper published in 1911 I followed this terminology. Since then, however, I have examined these muscles in Amphibia (1920), Ceratodus (1923), and Protopterus and Lepidosiren (1926), and, with this added knowledge and re-investigation of Ganoids, find that the name "Obliquus ventralis" s. "Interarcualis ventralis" has been applied to two morphologically different muscles: (1) To a longitudinal muscle passing from the branchial bar of its segment of formation to one in front. Following the terminology employed in describing such a muscle in Dipnoi and Amphibia, I now call it "Subarcualis rectus."* (2) To a transverse muscle the inner end of which, instead of meeting its fellow in a mid-ventral raphé, is inserted into either the Basibranchiale or to the Hypobranchiale of its own side. This is, in reality, a transverse muscle which has become oblique in direction and given up its union with its fellow, in correspondence with the oblique position of the branchial bar.† In the table (*vide infra*) it is called "Obliquus ventralis."

In general, the front end of a Subarcualis rectus becomes attached to the bar next in front (in the case of Subarcualis rectus i to the hyoid bar). There are two exceptions to this in Ganoids: (1) Subarcualis rectus iv of Polypterus grows forwards to the 2nd branchial bar; such an occurrence, however, is found in many Teleostei and in Dipnoi. (2) The hind end of Subarcualis rectus iv of Amia, between the stages of 13 and 17 mm., grows back to the 5th branchial bar. I do not know of any similar occurrence. An additional longitudinal fasciculus is subsequently separated from the medial edge of the anterior part of the muscle. This is paralleled by a similar event in regard to Subarcualis rectus i of Rana.

No Subarcuales recti are developed in the first three branchial segments of Amia, or in any of the five branchial segments of Lepidosteus. The longitudinal tendons between the ventral ends of the bars (figured by v. WIJHE and by ALLIS) possibly represent the muscles, but, as far as I can see, the cellular primordia of these tendons are not muscle-cells.

An Obliquus ventralis may be formed either from a fully developed Transversus ventralis, *i.e.*, from one which meets its fellow in the mid line, *e.g.*, in the case of Obliquus ventralis iii of Acipenser and Amia, or from an incomplete one, *i.e.*, from one which passes inwards towards but does not actually join its fellow, *e.g.*, in the case of Obliquus ventralis ii of Acipenser and Amia. In the latter case it is, of course, possible that I have missed just the exact stage in which the muscle met its fellow, or this stage may be slurred

---

* The synonyms of the Subarcuales recti of Ganoids are as follows:—

Subarcualis rectus i	
of Polyodon	Most anterior Interarcualis ventralis, DANFORTH. Ventral interarcual (iav^1), NORRIS.
of Acipenser	Interarcualis ventralis (Jav$_1$), VETTER, KURZ. Ventral interarcual (iav^1), NORRIS.
of Polypterus	First interarcualis ventralis, POLLARD. Interarcualis ventralis i, ALLIS.
Subarcualis rectus iv	
of Polypterus	Described, not named, POLLARD. Interarcualis ventralis of fourth arch, ALLIS.
of Amia	Interarcualis ventralis of fifth arch (iav$_5$), McMURRICH. Parts (Ov iv^2 and Ov iv^3) of fourth Obliquus ventralis, ALLIS. Ventral interarcual, NORRIS.

† If the branchial bars were imagined to join the Basibranchiale at a right angle, the relationship of Obliqui ventrales to Transversi ventrales becomes obvious.

over in the process of formation of the Obliquus. The second suggestion is, I think, the more probable, as I have many embryos of both fish at the stages of formation of the muscle.

Changes, other than the above, take place in some of the muscles. In *Polypterus senegalus* (*vide* figs. 55 and 56), between the stages of 9·3 and 75 mm., the anterior end of Subarcualis rectus iv loses its attachment to the 2nd branchial bar and gains one to Transversus ventralis ii,* and Transversus ventralis ii, though still connected with its fellow across the mid line by a few fibres, joins Subarcualis rectus i. In Amia, between the stages of 11 and 13 mm. (*vide* figs. 104 and 105), Transversus ventralis iv becomes separated into an Obliquus ventralis iv and a Transversus ventralis iv. Such an occurrence—the separation of a primary simple Transversus ventralis into a Transversus ventralis and an Obliquus ventralis—is apparently quite common in Teleostei.

I would sum up the above by the statement that the branchial muscle-plates of Ganoids are at first continuous with the cœlomic epithelium below. On separation, their ventral ends either grow forwards, forming Subarcuales recti, or inwards, forming Transversi ventrales, or in both directions.

With the above explanatory remarks I hope that the following tables and figures will be moderately clear. Fig. 39 shows the condition in a 15-mm. embryo of Acipenser; fig. 55 that in a 9·3-mm. embryo, and fig. 56 that in a 75-mm. embryo of Polypterus; fig. 104 that in an 11-mm. and fig. 105 that in a 13-mm. embryo of Amia; and fig. 130 that in a 17-mm. embryo of Lepidosteus.

Subarcuales recti.

	Polyodon.	Acipenser.	Polypterus.	Amia.	Lepidosteus.
i	+	+	+	0	0
ii	0	0	0	0	0
iii	0	0	0	0	0
iv	0	0	+ {extends to 2nd bar}	+ {extends back to 5th bar}	0
v	0	0		0	0

Transversi ventrales.

	Polyodon.	Acipenser.	Polypterus.
i	0	0	0
ii	+ → Obliq. vent.	+ → Obliq. vent.	+
iii	+ → Obliq. vent.	+ → Obliq. vent.	+ → Obliq. vent.
iv	+ → Obliq. vent.	+	+
v	+	+	

The arrow indicates "develops into."

---

* This loss of the primary anterior attachment of Subarcualis rectus iv does not occur in all species of Polypterus, for Allis described it as attached to the 2nd bar in *P. ornatipinnis*.

Transversi ventrales—continued.

	Amia.	Lepidosteus.
i	+ → Obliq. vent.	+ → Obliq. vent.
ii	+ → Obliq. vent.	+ → Obliq. vent.
iii	+ → Obliq. vent.	+ → Obliq. vent.
iv	+ → { Obliq. vent. Trans. vent. }	+ → Obliq. vent.
v	+	+

The arrow indicates "develops into."

The condition in embryonic stages of Polyodon is not known, so that it is not certain, though probable, that Obliqui ventrales ii, iii and iv have developed from Transversi ventrales. On comparison of these muscles with their homologues in Teleostei, Dipnoi and Amphibia, it would appear that :—

(1) The number of Subarcuales recti is scanty. They are, in general, much more numerous in Teleostei and Amphibia.

(2) The number of Transversi ventrales may, as in Amia and Lepidosteus, be complete. Many become Obliqui ventrales. The most posterior one never does so. In Dipnoi no Obliqui ventrales are formed, but fusions occur. In Amphibia the number is less.

The figures also show Coraco-branchialis v (iv in Polypterus). This muscle, as I showed in 1911, is developed by backward growth from the junction of Transversus v (or iv) with Constrictor branchialis v (or iv). The anterior end of the muscle is at first attached to the last branchial bar. The primary attachment is preserved in Polypterus and Lepidosteus. In Amia the muscle becomes separated into two fasciculi, one attached to the last branchial bar and the other to the Basibranchiale. In Polyodon and *Acipenser ruthenus* it becomes exclusively attached to the Basibranchiale.

Coraco-branchiales occur in Elasmobranchii, Teleostomi and Dipnoi, and difficult problems arise in regard to their innervation and homologies.

Coraco-branchialis v of Teleostomi is innervated by the corresponding branchial nerve X_4 (Coraco-branchialis iv of Polypterus by X_3). The four Coraco-branchiales, *i.e.*, ii, iii, iv and v of Dipnoi, are innervated by the Vagus, though the details are not quite uniform. In Ceratodus all four are innervated by X_4, whereas in Protopterus and Lepidosiren Coraco-branchialis v is innervated by X_4, and the more anterior ones by X_3. The Coraco-branchiales of Elasmobranchii are all innervated by the Plexus cervicalis s. N. hypobranchialis.

As the development of the muscles is uniformly from the ventral ends of the branchial muscle-plates in all three phyla, it follows that the spinal innervation in Elasmobranchii is secondary. It appears possible that the number of Coraco-branchiales in Teleostomi has become lessened to one muscle developed in the most caudal branchial arch, but this muscle has retained its primitive innervation.

The Œsophageal Muscles.

Constrictor fibres surrounding the œsophagus have been described in Plagiostomi, Teleostomi, Dipnoi and Amphibia. The name "Constrictor œsophagi" has generally been applied to these fibres. WIEDERSHEIM used the term "Constrictor pharyngis" in Polypterus, Amia, Lepidosteus and Dipnoi, under the theory that it represented the musculature of lost branchial arches.

Investigation of the development of these constrictor fibres shows that they can be separated into two groups, which I call "Sphincter œsophagi" and "Constrictor œsophagi." A Sphincter œsophagi is present in Teleostomi and Dipnoi, but not in Plagiostomi or Amphibia. A Constrictor œsophagi is present in Plagiostomi, Dipnoi and Amphibia, but not in Teleostomi. Dipnoi have thus both a Sphincter and a Constrictor œsophagi. The Sphincter œsophagi is developed as a backward growth or extension of the last Transversi ventrales (4th in Polypterus, 5th in other Teleostomi and in Dipnoi). In Dipnoi there is an added myotome constituent to this Sphincter (*vide* AGAR, 1907, EDGEWORTH, 1923 and 1926). The Constrictor œsophagi is developed from cells budded off from the cœlomic epithelium underlying the œsophagus.

Constrictor œsophagi.

In Plagiostomi there is a Constrictor œsophagi. The development in Scyllium is as follows: In 23- and 25-mm. embryos (fig. 15) the interval between the œsophagus (which at this stage is solid) and the splanchnic layer of cœlomic epithelium is packed with more or less spherical cells—the splanchnic mesoblast—which have been budded off from the cœlomic epithelium. In one of 30 mm. (fig. 16) a Constrictor œsophagi has developed in this mesoblast. The cells have become oval in shape, with their long axes parallel with the surface of the œsophagus. In an embryo of 35-mm. the cells are still more markedly spindle-shaped. In one of 53-mm. the anterior edge of this Constrictor œsophagi is attached to the 5th branchial bars, and the hind end of the Basibranchiale and the Adductores arcuum branchialium v are proliferated from its lateral edges (*vide* p. 65).

Such a Constrictor œsophagi is generally present in Plagiostomi. It certainly occurs in embryos of Scyllium, Acanthias, Mustelus, Heterodontus, Heptanchus, and *Raja clavata*, and is present in the adult state of Chlamydoselachus.

There is no Constrictor œsophagi in Teleostomi. The only muscle developed in the splanchnic mesoderm is the Constrictor laryngis of Polypterus.

The larynx of Polypterus, with its muscle and nerves, was described by WIEDERSHEIM, who stated that the Rima glottidis opens into the floor of the œsophagus a little behind the last (4th) branchial bars. His description of the Sphincter œsophagi is given below (p. 78). The larynx, he said, is surrounded by a Constrictor laryngis,* which is

---

* Sphincter glottidis, WIEDERSHEIM.

continued back as a cross-striped muscle-layer on the walls of the lungs. The edges of the Sphincter œsophagi, as the larynx passes through it, radiate inwards through the Constrictor laryngis and form a Dilatator laryngis.

The development of the larynx was described by KERR, who stated that the first trace is present in an 8-mm. embryo (stage 33) as an open longitudinal groove on the ventral side of the pharynx, *i.e.*, œsophagus. In a 9·3-mm. embryo (stage 36) the groove is deeper. Posteriorly, the bottom of the groove spreads out laterally, and these lateral projections are continued backwards as the rudiments of the lungs. KERR did not describe the development of the laryngeal musculature, which is as follows:—

In the 8-mm. embryo (fig. 46) the slit-like diverticulum, 0·045 mm. long, is situated in the middle line of the floor of the fore part of the œsophagus, its anterior edge being 0·14 mm. behind the ventral ends of the 4th branchial bars. Just in front of, and at the level of the laryngeal diverticulum, the cœlomic epithelium is proliferating cells which extend up on either side of the laryngeal diverticulum.

In the 9·3-mm. embryo (figs. 48 to 50) the laryngeal diverticulum is 0·10 mm. long, *i.e.*, it has increased in antero-posterior length. Its front edge is 0·145 mm. behind the 4th branchial bars. There is thus no backward migration of the laryngeal diverticulum such as occurs in Dipnoi. The cells, which in the 8-mm. embryo were being proliferated from the cœlomic epithelium, cluster round the larynx and form the primordium of the Constrictor laryngis. The cells have also extended backwards on the walls of the lungs.

In a 75-mm. embryo the Constrictor laryngis is well developed, and extends back on the walls of the lungs, as described by WIEDERSHEIM. The Dilatator laryngis is well developed. In Polypterus, as in Protopterus and Lepidosiren, there is a median plate of dense connective tissue beneath the prælaryngeal portion of the œsophagus, and within the Sphincter œsophagi. It is probably formed from the cells budded off from the splanchnic layer of the cœlomic epithelium.

Dipnoi.—In Ceratodus and the Dipneumona (1923 and 1926) cells are budded off from the pericardio-peritoneal ducts, and form the laryngeal muscles and the Constrictor œsophagi.

Amphibia.—In Urodela and Anura (1920) cells are budded off from the cœlomic epithelium, and spread round the œsophagus and developing larynx. This splanchnic mesoblast forms the laryngeal muscles and cartilages and the Constrictor œsophagi.

Sphincter œsophagi.

Acipenser.—In embryos up to the stage of 9·5 mm. there are no Transversi ventrales v. In one of 10 mm. (figs. 29 and 30) the ventral ends of the 5th branchial muscle-plates have separated from the cœlomic epithelium and grown inwards, forming Transversi ventrales v, and there is an inward growth above the gut, which is the commencement of the Sphincter œsophagi. The Sphincter has extended backwards to 0·12 mm. behind the 6th gill-clefts. It is more marked ventrally than dorsally. The Sphincter extends farther backwards in succeeding stages—in an embryo of 11 mm. to 0·16 mm. behind the 6th gill-clefts, in one of 13 mm. to 0·58 mm. behind, and in one of 15 mm. to 0·67 mm. behind.

Polypterus.—In an 8-mm. embryo of Polypterus (figs. 43 to 46), the slit-like laryngeal diverticulum is present in the floor of the œsophagus 0·14 mm. behind the ventral ends of the 4th branchial bars (*vide supra*, p. 77). The Sphincter œsophagi is present and extends backwards from Transversi ventrales iv as far as the anterior edge of the laryngeal diverticulum. In the first third of the prælaryngeal portion of the œsophagus the Sphincter œsophagi is, like the Transversi ventrales v, only ventral to the gut. Behind this point the lateral edges wrap round the lateral edges of the œsophagus and form a complete Sphincter.

In the 9·3-mm. embryo (figs. 47 to 50) the fore part of the Sphincter is situated only ventral to the œsophagus, as in the younger specimen. A little farther back (fig. 47) its lateral edges wrap round the œsophagus and extend into inward-projecting folds of the epithelial wall. Farther back (fig. 48) it forms a complete Sphincter, which extends posteriorly a little farther than in the 8-mm. specimen. It is interrupted ventrally by the laryngeal diverticulum and, behind this, forms an incomplete Sphincter (figs. 49 and 50).

In a 75-mm. specimen the anterior part of the Sphincter surrounds the œsophagus, *i.e.*, has spread up round it. Its anterior edge of its dorsal part slightly overlaps the branchial region, but the transversely directed fibres are not attached to any branchial bars. The inward-projecting folds of the œsophageal wall have disappeared. The Sphincter extends right down the œsophagus. The larynx passes through it and the edges of the Sphincter penetrate the fibres of the Constrictor laryngis, forming the Dilatator laryngis of WIEDERSHEIM.

Amia.—In a 7-mm. embryo of Amia (figs. 75 and 76) the lower end of the 5th branchial muscle-plate has separated from the cœlomic epithelium and begun to spread inwards. This is the commencement of Transversus ventralis v. The Transversus has spread backwards along the œsophagus to a distance of 0·045 mm. and laps round its dorsal edge. This is the commencement of the Sphincter œsophagi.

In an 8-mm. embryo (figs. 80 and 81) the Transversi ventrales v are complete, and the Sphincter is also complete, lapping completely round it both dorsally and ventrally. The Sphincter now reaches to a distance of 0·19 mm. behind the 6th gill-clefts.

Lepidosteus.—In a 10·25-mm. embryo (figs. 125 and 126) the ventral end of the 5th branchial muscle-plate has begun to spread inwards below the hind end of the branchial region. This is the commencement of the Transversi ventralis v. The muscle-plate is connected to its fellow by a narrow tract of cells above the branchial region. This transverse tract is continued backwards above the œsophagus to a distance of 0·12 mm. This is the first-formed portion of the Sphincter. In an 11-mm. embryo (fig. 127) the Sphincter œsophagi has extended ventrally on either side of the œsophagus, and in a 13·5-mm. embryo (fig. 129) completely encircles it.

The above observations show that the Sphincter œsophagi of the above Ganoids is developed by backward extension of the last Transversi ventrales (*i.e.*, IVth in Polypterus, Vth in the other genera) along the œsophagus. The initial stages of its formation vary a little. In Polypterus extension first occurs below the œsophagus and the Sphincter is completed by upward growth round it. In Acipenser the extension is more marked ventrally than dorsally. In Amia it is of about equal extent dorsally and ventrally. In Lepidosteus the extension first occurs above the Sphincter and is subsequently completed by ventral extension. The method followed in Polypterus is probably the primary one, for it is similar to that of the cranial constituent of the Sphincter œsophagi in Dipnoi.

There is a similar Sphincter œsophagi, continuous anteriorly with Transversi ventrales v in embryos of Salmo, Amiurus, Gasterosteus, Caranx and Pleuronectes.

The anterior edge of the Sphincter œsophagi extends forwards over the branchial region. The process is least marked in Polypterus, where the transverse fibres are not attached to any branchial bars. It is more marked in other genera and the lateral edges are attached to the 4th or the 4th and 5th branchial bars. They remain in complete or partial continuity with the rest of the Sphincter. In Polyodon this Transversus dorsalis is attached to Epibranchialia iv; in *Acipenser ruthenus* to Epi- and Kerato-branchialia iv and Branchialia v. In Amia and Lepidosteus it is attached to the pharyngeal plate, and in the former is partially separable into two. Three Obliqui dorsales are separated from the lateral edges of this anterior extension of the Sphincter œsophagi in Amia and Lepidosteus.

In Amia and Lepidosteus the relations of the Sphincter œsophagi become somewhat changed, owing to the development of the dorsal larynx, ductus pneumaticus and air bladder. It was shown by Piper (1902) that in Amia these structures are developed from a dorsal median groove in the wall of the œsophagus and stomach, which is constricted off from behind forwards so as eventually to be continuous only with the anterior end of the œsophagus. He did not describe the development of the Sphincter œsophagi. I have only to add to this that the dorsal median groove is preceded by a dorsa-median ridge in the as yet solid œsophagus, and that the development in Lepidosteus is similar to that in Amia. The Sphincter œsophagi spreads back before the groove is constricted off. The result is that the larynx, ductus pneumaticus and anterior end of the air-bladder are within the Sphincter œsophagi.

The Dilatator laryngis of Amia and Lepidosteus is, as I have previously shown, proliferated from the anterior part of the Sphincter œsophagi. It is seen in fig. 129.

A Retractor arcuum branchialium is developed from the dorsal surface of the anterior part of the Sphincter œsophagi in Amia and Lepidosteus, but not in Polyodon, Acipenser and Polypterus. In Lepidosteus it is developed in an embryo of 11 mm. (fig. 125). It passes backwards and slightly upwards towards the side of the notochord.

Allis stated that the muscle is quite certainly the homologue of a muscle in Chlamydoselachus, which is simply a differentiation of the Constrictor œsophagi. This, however, is not possible as the constrictor muscles of the œsophagus of Selachii and Teleostomi are not homologous structures, so that their derivatives, if present, are not homologous. It may, further, be added that a Retractor dorsalis is an inconstant structure in Plagiostomi. In Chlamydoselachus I fail to find it in a 10·1-cm. specimen examined in serial sections, and it has not been described in any other genera.

The above-described phenomena show that a Constrictor œsophagi is present in Plagiostomi, Dipnoi and Amphibia.* It is absent in Teleostomi. It is developed from cells budded off from the splanchnic cœlomic epithelium.

A ventral larynx—a diverticulum of the hind end of the branchial region or commencement of the œsophagus—is developed in Polypterus, Dipnoi and Amphibia. The anterior portion of the splanchnic mesoderm clusters round it and forms the laryngeal structures—the laryngeal muscles in all, and the laryngeal and tracheal skeleton additionally in Amphibia.

A Sphincter œsophagi is developed in Teleostomi and Dipnoi by extension backwards along the œsophagus of the last Transversi ventrales, *i.e.*, the IVth in Polypterus, the Vth in other genera. In Dipnoi this Sphincter has an added myotomic constituent derived from one or two occipital myotomes. In Teleostomi other than Polypterus the anterior dorsal edge of the Sphincter spreads forwards over the branchial region. In Amia and Lepidosteus and some Teleostei a Retractor dorsalis is separated from the anterior part.

It is not possible to come to any certain conclusion as to whether the Constrictor or the Sphincter œsophagi is the primary structure in gnathostome Vertebrates. The question is intimately associated with that of the Transversi ventrales. If, as seems possible, these are primarily absent in Plagiostomi, *i.e.*, never occurred in their phylogenetic history, then the Constrictor is the primary structure. It would follow from this that Transversi ventrales and a Sphincter œsophagi were developed in common ancestors of Dipnoi and Teleostomi, and led in the latter phylum to the disappearance of a Constrictor œsophagi—the last trace left of this splanchnic mesoderm being the laryngeal muscles of Polypterus. Further evidence in favour of a common ancestry of Teleostomi and Dipnoi is summarised on p. 47.

I may perhaps add that the early stages of these Ganoids are none too easy to investigate. The tissues are very delicate, and the cells apt to be shrunken unless great care is taken in the methods of fixation. The embryos of Amia and Lepidosteus had been fixed in Bouin's fluid. Only a small proportion of the serial sections made was perfect and used for the observations detailed in the above paper. Possibly some other fixative would have given better results.

It is my pleasant duty to thank Professors SCHMALHAUSEN and LIVANOFF for embryos

---

* A Constrictor œsophagi is also present in Holocephali, Sauropsida, and Mammalia.

of *Acipenser ruthenus*, Prof. REED for some of the embryos of Amia and Lepidosteus used, Prof. GRAHAM KERR for permission to examine sections of Polypterus during a visit to Glasgow, Prof. COLE for permission to examine sections of Chlamydoselachus which had been made by my colleague Dr. HENDERSON, and Mr. NORMAN for permission to examine sections of larval and adult stages of Anguilla.

I am also much indebted to the Bristol University Colston Society for grants to purchase material, to Mr. EMERY for great assistance in making the models, and to Miss CROSS for her excellent drawings of them.

I should also mention that a paper on the above-described development of the ocular muscles was given at a meeting of the British Association at Oxford in 1926, and an abstract was published in the Reports issued just before the meeting.

REFERENCES.

AGAR, W. E. (1907). "The development of the anterior mesoderm and paired fins, with their nerves, in Lepidosiren and Protopterus." 'Trans. Roy. Soc. Edin.,' vol. 45.

ALLIS, E. P. (1897). "The cranial muscles and cranial and first spinal nerves in *Amia calva*," 'Journ. Morph.,' vol. 12.

Idem (1917). "The homologies of the muscles related to the visceral arches of the Gnathostome Fishes," 'Q. J. Micr. Sci.,' vol. 62.

Idem (1919). "The innervation of the Mandibularis and Geniohyoideus muscles of the Bony Fishes," 'Anat. Record,' vol. 16.

Idem (1922). "The cranial anatomy of Polypterus, with special reference to *Polypterus bichir*," 'Jour. Anat.,' vol. 56.

ASSHETON, R. (1907). 'The development of *Gymnarchus niloticus*.' The Work of John Samuel Budgett. Cambridge.

BALFOUR, F. M. (1878). 'A Monograph on the Development of Elasmobranch Fishes.'

DE BEER, G. R. (1924). "The Pro-otic Somites of Heterodontus and of Amia," 'Q. J. Micr. Sci.,' vol. 68.

Idem (1926). "Studies on the vertebrate head. (ii) The orbito-temporal region of the skull." 'Q. J. Micr. Sci.,' vol. 70.

BORCEA, I. (1907). "Observatiuni a supra diferentierii si desvoltarii musculaturii branchiostegale la Teleosteeni," 'Acad. Roumana. Public., Fondului Vasile Adamachi,' No. 19.

BUDGETT, J. S. (1902). "On the structure of the larval Polypterus," 'Trans. Zool. Soc.,' vol. 16.

CORNING, H. K. (1899). "Ueber einige Entwicklungsvorgänge am Kopfe der Anuren," 'Morph. Jahrb.,' vol. 27.

DANFORTH, C. H. (1913). "The Myology of Polyodon," 'Jour. Morph.,' vol. 24.

DIETZ, P. A. (1912). 'Vergelijkende Anatomie van de Kaak- en Kieuw-boogspieren der Teleostei,' Leiden.

Idem (1914). "Beiträge zur Kenntnis der Kiefer- und Kiemen-bogenmuskulatur der Teleostier (i) Die Kiefer- und Kiemen-bogenmuskeln der Acanthopterygier," 'Mitt. a. d. Zool. Stat. zu Neapel,' vol. 22.

DOHRN, A. (1904 *a*). "Die Mandibularhöhle der Selachier," 'Mitt. a. d. Zool. Stat. zu Neapel,' vol. 17.

Idem (1904 *b*). "Die Præmandibularhöhle," *ibid.*

EDGEWORTH, F. H. (1911). "On the morphology of the cranial muscles in some Vertebrates," 'Q. J. Micr. Sci.,' vol. 56.

Idem (1913). "On the afferent ganglionated Nerve-fibres of the muscles innervated by the Fifth Cranial Nerve, and on the Innervation of the Tensor Veli palatini and Tensor Tympani," 'Q. J. Micr. Sci.,' vol. 58.

Idem (1916). "On the development and morphology of the Pharyngeal, Laryngeal and Hypobranchial Muscles of Mammals," 'Q. J. Micr. Sci.,' vol. 61.

Idem (1919). "On the development of the Laryngeal Muscles in Sauropsida," 'Jour. Anat.,' vol. 54.

Idem (1920). "On the development of the Hypobranchial and Laryngeal Muscles in Amphibia," 'Jour. Anat.,' vol. 54.

Idem (1923). "On the development of the Hypobranchial, Branchial and Laryngeal Muscles of Ceratodus," 'Q. J. Micr. Sci.,' vol. 67.

Idem (1925). "On the autostylism of Dipnoi and Amphibia," 'Jour. Anat.,' vol. 59.

Idem (1926). "On the development of the Coraco-branchiales and Cucullaris of Scyllium," 'Jour. Anat.,' vol. 60.

Idem (1926). "On the Hyomandibula of Selachii, Teleostomi and Ceratodus," 'Jour. Anat.,' vol. 60.

Idem (1926). "On the development of the Cranial Muscles of Protopterus and Lepidosiren," 'Trans. Roy. Soc. Edin.,' vol. 54.

FÜRBINGER, M. (1897). "Ueber die spino-occipitalen Nerven der Selachier und Holocephalen," 'Festschr. f. Gegenbaur,' III.

GOODRICH, E. S. (1918). "On the development of the segments of the head of Scyllium," 'Q. J. Micr. Sci.,' vol. 63.

HAGUE, Miss F. (1924). "The Chondrocranium of *Amia calva*." 'Jour. of Morph.,' vol. 39.

HOLMQVIST, O. (1910). "Der Musculus Protractor hyoidei (Geniohyoideus Auctt.) und der Senkungsmechanismus des Unterkiefers bei den Knochenfischen." 'Lunds Univ., Arsskrift.,' N.F., Abd. 2, vol. 4.

Idem (1911). "Studien in der von den Nr. Trigeminus und Facialis innervierten Muskulatur der Knochenfische," 'Arsskrift.,' N.F., Abd. 2, vol. 7.

JUGE, M. (1899). "Recherches sur les nerfs cérébraux et la musculature céphalique du Silurus glanis," 'Revue Suisse de Zoologie,' vol. 6.

KERR, J. GRAHAM (1907). 'The development of *Polypterus senegalus* Cuv.' The Work of John Samuel Budgett. Cambridge.

Idem (1910). "On certain features in the development of the alimentary canal in Lepidosiren and Protopterus," 'Q. J. Micr. Sci.,' vol. 52.

KIDD, L. J. (1922). "The fourth cranial nerve," 'Brit. Jour. of Ophthal.'

KINDRED, J. E. (1921). "The chondrocranium of *Syngnathus fuscus*," 'Jour. of Morph.,' vol. 35.

KINGSBURY, B. F. (1926). "Branchiomerism and the theory of head segmentation," 'Jour. Morph.,' vol. 42.

v. KUPFFER, C. (1893). 'Studien zur vergleichenden Entwicklungsgeschichte des Kopfes der Kranioten. 1 Heft. Die Entwicklung des Kopfes von *Acipenser sturio*.' München.

KURZ, —. (1924). "Untersuchungen zur Anatomie des Kopfes des Jangtsestöres" (*Acipenser ? dabryanus*), 'Zeitschr. f. Anat. u. Entwick.,' vol. 75.

LUTHER, A. (1913). "Ueber die vom N. trigeminus versorgte Muskulatur der Ganoiden und Dipneusten," 'Acta. Soc. Fenn.,' vol. 41.

Idem (1914). "Ueber die vom N. trigeminus versorgte Muskulatur der Amphibien, mit einem vergleichenden Ausblick über den Adductor mandibulæ der Gnathostomen," 'Acta. Soc. Fenn.,' vol. 44.

MARSHALL, M. (1881). 'On the Head-Cavities and associated Nerves of Elasmobranchs,' vol. 21.

McMURRICH, J. P. (1885). "The cranial muscles of *Amia calva* L., with a Consideration of the Relations of the Post-Occipital and Hypoglossal nerves in the various Vertebrate groups," 'Studies Biol. Lab. Johns Hopkins Univ.'

NEAL, H. V. (1909). "The morphology of the Eye-muscle nerves," 'Proc. Intern. Cong. Boston (1907).' Separate pub., 1909.

Idem (1914). "The morphology of the Eye-muscle nerves," 'Jour. Morph.,' vol. 25.

Idem (1918). "The history of the Eye-muscles," 'Jour. Morph.,' vol. 30.

NORRIS, H. W. (1825). "Observations on the peripheral distribution of the cranial nerves of certain ganoid fishes (Amia, Lepidosteus, Polyodon, Scaphirhynchus and Acipenser)," 'Jour. Comp. Neur.,' vol. 39.

PARKER, W. K. (1882). "On the development of the skull in *Lepidosteus osseus*," 'Phil. Trans.,' vol. 173.

PEHRSON, T. (1922). "Some points in the cranial development of teleostomian fishes," 'Acta Zoologica,' Arg. 3.

PINKUS, F. (1895). "Die Hirnnerven des *Protopterus annectens*," 'Morph. Arbeiten h. v. Schwalbe,' vol. 4.

PIPER, H. (1902). "Die Entwickelung von Magen, Duodenum, Schwimmblase, Leber, Pankreas und Milz bei *Amia calva*," 'Archiv f. Anat. u. Phys., Anat. Abthlg.,' Suppl.

Pollard, H. B. (1891). "On the anatomy and phylogenetic position of Polypterus," 'Anat. Anz.,' vol. 6.

Ruge, G. (1897). "Ueber das peripherische Gebiet des Nervus facialis bei Wirbelthieren," 'Festschr. f. Gegenbaur,' III.

Scott, W. B., and Osborn, H. F. (1879). "On the early development of the common Newt," 'Q. J. Micr. Sci.,' vol. 19.

Sewertzoff, A. N. (1923). "Die Morphologie des Visceralapparates der Elasmobranchier," 'Anat. Anz.,' vol. 56.

Veit, O. (1911). 'Die Entwickelung des Primordialcranium von *Lepidosteus osseus*,' Wiesbaden.

Versluys, J. (1922). 'Rückbildung der Kiemenbogen bei den Selachii,' Bijdragen Dierkunde, Amsterdam.

Vetter, B. (1877). "Untersuchungen zur vergleichenden Anatomie der Kiemen- und Kiefer-muskulatur der Fische. (ii) Theil," 'Jenaische Zeitschr. f. Naturw.,' vol. 12.

Welcker, H. (1878). "Zur Lehre von Bau und Entwickelung der Wirbelsäule," 'Zoolog. Anz.,' vol. 1.

Wiedersheim, R. (1904). "Ueber das Vorkommen eines Kehlkopfes bei Ganoiden und Dipnoern, sowie über die Phylogenie der Lunge," 'Zool. Jahrb.,' Suppl. 7.

v. Wijhe, J. W. (1880). 'Over het Visceralskelet en de Zenuwen van den Kop der Ganoiden,' Leiden.

Idem (1882). "Ueber die Mesodermsegmente und die Entwickelung der Nerven des Selachierkopfes," 'Natuurk. Verh. d. Koninkl. Akad., Amsterdam,' vol. 22.

Wright, McMurrich, Macallum and McKenzie (1884). "Contributions to the Anatomy of Amiurus," 'Proc. Canadian Institute,' vol. 2.

EXPLANATION OF PLATES.

Abbreviations.

Add. arc. br., Adductor arcus branchialis.
Add. hyomand., Adductor hyomandibulæ.
Add. man., Adductor mandibulæ.
Add. man. ex., Adductor mandibulæ externus.
Add. man. in., Adductor mandibulæ internus.
Add. man. intramand., Adductor mandibulæ intramandibularis.
Add. man. me., Adductor mandibulæ medius.
Air bldr., air bladder.
Arc. dor., Arcualis dorsalis.
At. arc. br., Attractor arcus branchialis.
Au. ca., auditory capsule.
Au. ve., auditory vesicle.
Ba. pl., basal plate.
Br. m. pl., branchial muscle plate.
Bran. bar, branchial bar.
Bran. ray, branchiostegal ray.
Bu. cav., buccal cavity.
Cœl., cœlom.
Cœl. epi., cœlomic epithelium.
Con. br., Constrictor branchialis.
Con. hy. ven., Constrictor hyoideus ventralis.
Con. lar., Constrictor laryngis.
Con. i dor., Constrictor i dorsalis.
Con. œso., Constrictor œsophagi.
Con. sup., Constrictor superficialis.

Co. bran., Coraco-branchialis.
coro. pr. Meck. ca., coronoid process of Meckel's cartilage.
Cuc., Cucullaris.
Dent. b., dentary bone.
Dil. lar., Dilatator laryngis.
Dil. op., Dilatator operculi.
divert., diverticulum of buccal cavity.
dor. ao., dorsal aorta.
duct. pneum., ductus pneumaticus.
epi., epithelium.
epib., epibranchiale.
eth. pl., ethmoid plate.
g., ganglion.
gi. cl., gill cleft.
Gass. g. V, Gasserian ganglion of Vth nerve.
Genic g. VII, geniculate ganglion of VIIth nerve.
Gen. br., Genio-branchialis (Branchio-mandibularis of Vetter).
g. max. man. V, ganglion maxillo-mandibulare V.
Hyo. bar., hyoid bar.
Hyoh., Hyohyoideus.
Hyoh. inf., Hyohyoideus inferior.
hyo. m. pl., hyoid muscle plate.
Hyom., Hyomandibula.
Hyosym., Hyosymplecticum.
Hypb., Hypobranchiale.
Hyphy., Hypohyale.
inf., infundibulum.
intb., Interbranchialis.
Inthy., Interhyoideus.
Inthy. dor., Interhyoideus dorsalis.
Intma., Intermandibularis.
Intma. ant., Intermandibularis anterior.
Intma. post., Intermandibularis posterior.
inthya., interhyale.
Kerb., Keratobranchiale.
Kerhy., Keratohyale.
Kerhypo., Keratohypohyale.
lar., larynx.
lar. div., laryngeal diverticulum.
Lev. arc. br., Levator arcus branchialis.
Lev. pal. quad., Levator palatoquadrati.
man. bar, mandibular bar.
man. m. pl., mandibular muscle-plate.
mast. ms., masticatory muscles.
Meck. ca., Meckel's cartilage.
myot., myotome.
no., notochord.
Nas., Nasalis.
Ob. inf., Obliquus inferior.
Ob. su., Obliquus superior.
Ob. ven., Obliquus ventralis.
Œso., œsophagus.
ot. pro. palquad., otic process of palatoquadrate.
Pal. man., Palato-mandibularis.
pla. pro., palatal process.
palqd., palatoquadrate.
Parab., Parabasalis.
par. cœl. epi., parietal cœlomic epithelium.
parach., parachordal cartilage.
p. cd., pericardium.
phar., pharynx.
phary. pl., pharyngeal plate.
pot. ot. som., postotic somite.
pr. man. som., præmandibular somite.
Præorb., Præorbitalis.
Præoperc., Præopercularis.
Prætr. X_1, prætrematic branch of X_1.
Protract. hyoidei, Protractor hyoidei.
quad., quadrate.
R. buc. VII, Ramus buccalis VII.
R. hyo. VII, Ramus hyomandibularis VII.
R. man. V, Ramus mandibularis V ($= V_3$).
R. mand. ext. VII, Ramus mandibularis externus VII.
R. opht. VII, Ramus ophthalmicus VII.
Rec. cer., Rectus cervicis.
Rec. ex., Rectus externus oculi.
Rec. su., Rectus superior oculi.
Ret. arc. dors., Retractor arcuum branchialium dorsalis.
Sph. œs., Sphincter œsophagi.
Spl. cœl. epi., Splanchnic cœlomic epithelium.
Spl. meso., Splanchnic mesoderm.
sym. pro., symplectic process.
trab., trabecula.
Tra. dor., Transversus dorsalis.
Tra. ven., Transversus ventralis.
tr. my., trunk myotome.
v., *vein.*
vit. v., vitelline vein.
Roman numerals, cranial nerves.

Scyllium canicula. (Figs. 1 to 16—Plates 7 to 9.)

FIGS. 1 and 2.—Drawings of model of embryo 12·5 mm. Fig. 1 shows the right side of the head. The first postotic somite is not depicted. In fig. 2 the brain, notochord and spinal somites have been removed and the remainder of the model is seen from above. It shows the præmandibular somite, the primordia of the Obliquus superior and Rectus externus, and the upper ends of the mandibular, hyoid and branchial muscle-plates.

FIG. 3.—Embryo 15 mm. Part of sagittal section showing 1st postotic somite and 1st branchial muscle-plate, separated by mesenchyme.

FIGS. 4 and 5.—Embryo 16 mm. 2 horizontal sections through 1st branchial arch. 4 is the higher section and separated by 0·06 mm. from the lower.

FIG. 6.—Embryo 22·5 mm. Horizontal section through 1st branchial arch.

FIGS. 7 to 14.—Embryo 32 mm. Horizontal sections through 1st branchial arch. 7 is the highest. There is a distance of 0·024 mm. between 7 and 8, 0·108 mm. between 8 and 9, 0·056 mm. between 9 and 10, 0·108 mm. between 10 and 11, 0·064 mm. between 11 and 12, 0·048 mm. between 12 and 13, 0·056 mm. between 13 and 14.

FIG. 15.—Embryo 25 mm. Transverse section through the anterior end of the œsophagus.

FIG. 16.—Embryo 30 mm. Transverse section through the anterior end of the œsophagus.

Acanthias vulgaris : 28 mm. (Plate 9.)

FIG. 17.—Transverse section through anterior end of œsophagus.

Raja clavata : 52 mm. (Plate 9.)

FIG. 18.—Transverse section through anterior end of œsophagus.

Heterodontus : 30 mm. (Plate 10.)

FIG. 19.—Horizontal section through anterior part of head showing Rectus externus and muscle E.

Acipenser ruthenus. (Figs. 20 to 39—Plates 10 to 13.)

FIGS. 20 to 23.—Embryo 6·5 mm. Four horizontal sections through anterior part of head. 20 is the most dorsal. There is a distance of 0·025 mm. between 20 and 21, 0·035 mm. between 21 and 22, and 0·05 mm. between 22 and 23.

FIG. 24.—Embryo 7·5 mm. Horizontal section.

FIGS. 25 and 26.—Embryo 8 mm. Model of præmandibular and mandibular region. Fig. 25 is of the left side. Fig. 26 is as seen from above, the mid-brain and Gasserian ganglion having been removed.

FIG. 27.—Embryo 9 mm. Horizontal section.

FIG. 28.—Embryo 9·5 mm. Horizontal section.

FIGS. 29 and 30.—Embryo 10 mm. Two transverse sections through 5th branchial segment and commencement of œsophagus. Fig. 29 is the more anterior. There is a distance of 0·1 mm. between 29 and 30.

FIGS. 31 and 32.—Embryo 13 mm. Two horizontal sections of hinder part of branchial region. 31 is the more dorsal. There is a distance of 0·03 mm. between 31 and 32.

FIGS. 33 to 37.—Embryo 15 mm. Five transverse sections through head. 33 is the most anterior. There is a distance of 0·1 mm. between 33 and 34, 0·09 mm. between 34 and 35, 0·21 mm. between 35 and 36, and 0·3 mm. between 36 and 37. (Fig. 37 is at a lower scale of magnification than the others.)

FIG. 38.—Embryo 30 mm. Transverse section through branchial region.

FIG. 39.—Embryo 15 mm. Model of ventral branchial region. (The muscles have been added to a drawing of a model of the hyobranchial region made by my colleague Dr. HENDERSON.)

Polypterus senegalus. (Figs. 40 to 56—Plates 14 to 16.)

FIGS. 40 and 41.—Embryo 6·75 mm. 2 sagittal sections through mandibular region. 40 is the more external. There is a distance of 0·03 mm. between figs. 40 and 41.

FIG. 42.—Embryo 8 mm. Transverse section through Adductor mandibulæ.

FIGS. 43 to 46.—Embryo 8 mm. Four transverse sections through hinder part of branchial region and beginning of œsophagus. Fig. 33 is the most anterior.

FIGS. 47 to 50.—Embryo 9·3 mm. Four transverse sections through œsophagus. 47 is the most anterior. There is a distance of 0·09 mm. between 47 and 48, 0·05 mm. between 48 and 49, and 0·015 mm. between 49 and 50.

FIGS. 51 and 52.—Embryo 8 mm. Model showing mandibular muscles, fig. 51 from the side, fig. 52 from below.

FIGS. 53 and 54.—Embryo 9·3 mm. Model. 2 figs. In 54 the Adductor mandibulæ has been removed.

FIG. 55.—Embryo 9·3 mm. Model showing ventral branchial region.

FIG. 56.—Embryo 75 mm. Model showing ventral branchial region.

Amia calva. (Figs. 57 to 105—Plates 16 to 24.)

FIGS. 57 to 59.—Embryo 4 mm. Transverse sections. 58 is 0·08 mm. behind 57, and 59 is 0·02 mm. behind 58.

FIGS. 60 and 61.—Embryo 4 mm. Horizontal sections. 60 is the higher. There is a distance of 0·005 mm. between 60 and 61.

FIG. 62.—Embryo 4·5 mm. Transverse section.

FIGS. 63 to 66.—Embryo 5 mm. Horizontal sections. 63 is the highest. There is a distance of 0·02 mm. between 63 and 64, 0·035 mm. between 64 and 65, and 0·02 mm. between 65 and 66.

FIG. 67.—Embryo 5 mm. Sagittal section.

FIGS. 68 to 70.—Embryo 6 mm. Horizontal sections. 68 is the highest. There is a distance of 0·01 mm. between 68 and 69, and 0·185 mm. between 69 and 70.

FIG. 71.—Embryo 6 mm. Sagittal section.

FIGS. 72 to 74.—Embryo 7 mm. Transverse sections. 73 is 0·025 mm. behind 72, and 74 0·02 mm. behind 73.

FIGS. 75 and 76.—Embryo 7 mm. Transverse sections. 75 is 0·01 mm. behind the 6th gill-cleft. 76 is 0·04 mm. behind 75.

FIGS. 77 to 79.—Embryo 8 mm. Transverse sections. 78 is 0·035 mm. behind 77, and 79 0·06 mm. behind 78.

FIGS. 80 and 81.—Embryo 8 mm. Transverse sections. 80 is through the 6th gill-cleft. 81 is 0·05 mm. behind 80.

FIG. 82.—Embryo 9 mm. Transverse section.

FIGS. 83 and 84.—Embryo 11 mm. Sagittal sections. 83 is the more external. There is a distance of 0·05 mm. between 83 and 84.

FIGS. 85 to 88.—Embryo 12 mm. Transverse sections. 86 is 0·215 mm. behind 85, 87 is 0·095 mm. behind 86, and 88 is 0·085 mm. behind 87.

FIGS. 89 and 90.—Embryo 12·5 mm. Transverse sections. 90 is 0·14 mm. behind 89.

FIGS. 91 to 93.—Embryo 15 mm. Sagittal sections. 91 is the most external. 92 is 0·03 mm. internal to 91, and 93 is 0·06 mm. internal to 92.

FIGS. 94 and 95.—Embryo 15 mm. Transverse sections. 95 is 0·27 mm. behind 94.

FIGS. 96 to 98.—Embryo 8 mm. Model of masticatory muscles. 96 external aspect, 97 internal aspect, 98 dorsal aspect.

FIGS. 99 to 103.—Ventral aspect of models showing development of ventral mandibular and hyoid muscles. 99 of embryo 6·5 mm., 100 of embryo 7·5 mm., 101 of embryo 8 mm., 102 of embryo 9 mm., 103 of embryo 10·5 mm.

FIGS. 104 and 105.—Ventral aspect of branchial region. 104 of embryo 11 mm., 105 of embryo 13 mm.

Lepidosteus osseus. (Figs. 106 to 137—Plates 24 to 29.)

FIG. 106.—Embryo 3 mm. Transverse section.

FIGS. 107 and 108.—Embryo 4 mm. Transverse sections. Fig. 108 is 0·025 mm. behind 107.

FIGS. 109 and 110.—Embryo 6 mm. Transverse sections. Fig. 110 is the next behind 109. The sections are a trifle oblique, and the left side of the figures is anterior to the right.

FIG. 111.—Embryo 8 mm. Sagittal section.

FIGS. 112 and 113.—Embryo 9 mm. Horizontal sections. Fig. 113 is 0·1 mm. below 112. The sections are a little oblique and the left side is higher than the right.

FIG. 114.—Embryo 8 mm. Sagittal section.

FIG. 115.—Embryo 9 mm. Horizontal section through ventral ends of mandibular and hyoid muscle plates.

FIGS. 116 to 121.—Embryo 10·25 mm. Transverse sections through masticatory muscles. 116 is the most anterior. There is a distance of 0·02 mm. between 116 and 117, 0·015 mm. between 117 and 118, 0·015 mm. between 118 and 119, 0·095 mm. between 119 and 120, and 0·13 mm. between 120 and 121.

FIGS. 122 and 123.—Embryo 10·25 mm. Transverse sections through œsophagus. 122 is 0·025 mm. behind the posterior edge of the 7th gill-clefts, 123 is 0·04 mm. behind 122.

FIG. 124.—Embryo 10·5 mm. Model of Intermandibulares and Constrictores hyoidei ventrales. Ventral aspect.

FIG. 125.—Embryo 11 mm. Transverse section through œsophagus.

FIG. 126.—Embryo 12 mm. Model of Intermandibulares and Constrictores hyoidei ventrales. Ventral aspect.

FIGS. 127 and 128.—Embryo 13·5 mm. Model of masticatory muscles. 127 depicts the lateral aspect and 128 the dorsal.

FIG. 129.—Embryo 13·5 mm. Transverse section through œsophagus.

FIG. 130.—Embryo 17 mm. Model of ventral branchial muscles. Ventral aspect.

FIGS. 131 to 137.—Embryo 18·5 mm. Transverse sections through masticatory muscles. Fig. 131 is the most anterior. There is a distance of 0·045 mm. between 131 and 132, 0·115 mm. between 132 and 133, 0·18 mm. between 133 and 134, 0·195 mm. between 134 and 135, 0·04 mm. between 135 and 136, and 0·135 mm. between 136 and 137.

Amiurus catus. (Figs. 138 to 143—Plate 30.)

FIGS. 138 to 143.—Embryo 8 mm. Horizontal sections. 138 is the most dorsal. There is a distance of 0·048 mm. between 138 and 139, 0·016 mm. between 139 and 140, 0·032 mm. between 140 and 141, 0·08 mm. between 141 and 142, and 0·048 mm. between 142 and 143.

Caranx trachurus. (Figs. 144 to 148—Plates 30 and 31.)

FIGS. 144 to 146.—Embryo 3·5 mm. Horizontal sections through ventral mandibular and hyoid regions. 144 is the most dorsal. There is a distance of 0·03 mm. between 144 and 145, and 0·02 mm. between 145 and 146.

FIGS. 147 to 148.—Embryo 5 mm. Horizontal sections through ventral mandibular and hyoid regions. 147 is the more dorsal. There is a distance of 0·015 mm. between 147 and 148.

Menopoma alleghaniense. (Figs. 149 to 155—Plates 31 and 32.)

FIGS. 149 to 151.—Larva 12 mm. 3 horizontal sections. 149 is the most dorsal. There is a distance of 0·12 mm. between 149 and 150, and of 0·056 mm. between 150 and 151.

FIG. 152.—Larva 15 mm. Horizontal section.
FIG. 153.—Larva 15 mm. Model, from side.
FIG. 154.—Larva 17 mm. Model, from side.
FIG. 155.—Larva 18 mm. Model, from side.

(In these models the eye, represented by dotted outline, has been removed.)

Rana temporaria. (Figs. 156 to 162—Plates 32 and 33.)

FIG. 156.—Larva 7 mm. Transverse section.
FIG. 157.—Larva 8 mm. Transverse section.
FIG. 158.—Larva 8 mm. Horizontal section.
FIG. 159.—Larva 9 mm. Transverse section.
FIGS. 160 to 162.—Larva 9 mm. Three horizontal sections, 160 is the most dorsal. There is a distance of 0·024 mm. between 160 and 161, and 0·12 mm. between 161 and 162.

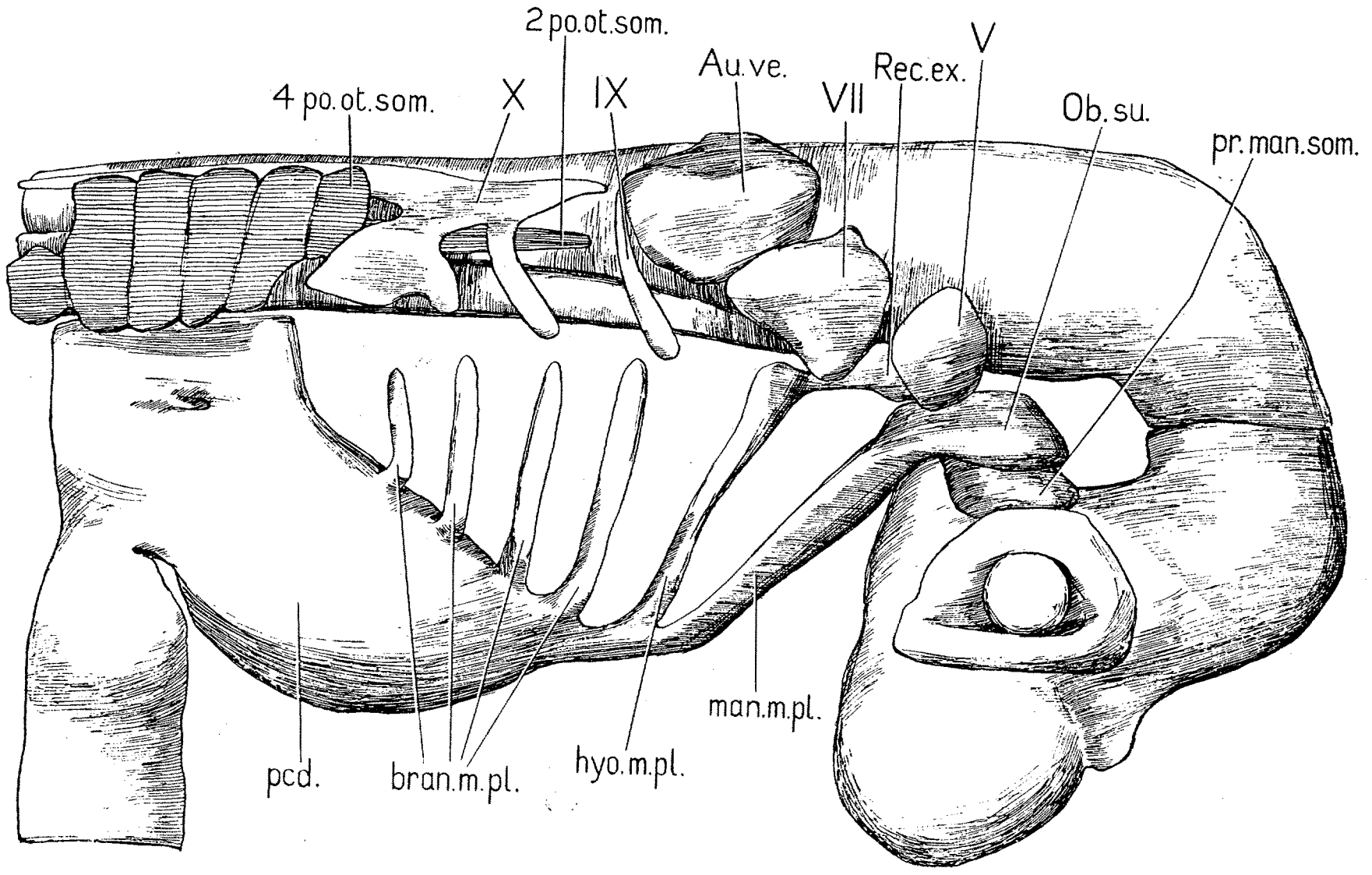
4 po.ot.som.
2 po.ot.som.
X
IX
Au.ve.
VII
Rec.ex.
V
Ob.su.
pr.man.som.
pcd.
bran.m.pl.
hyo.m.pl.
man.m.pl.

1

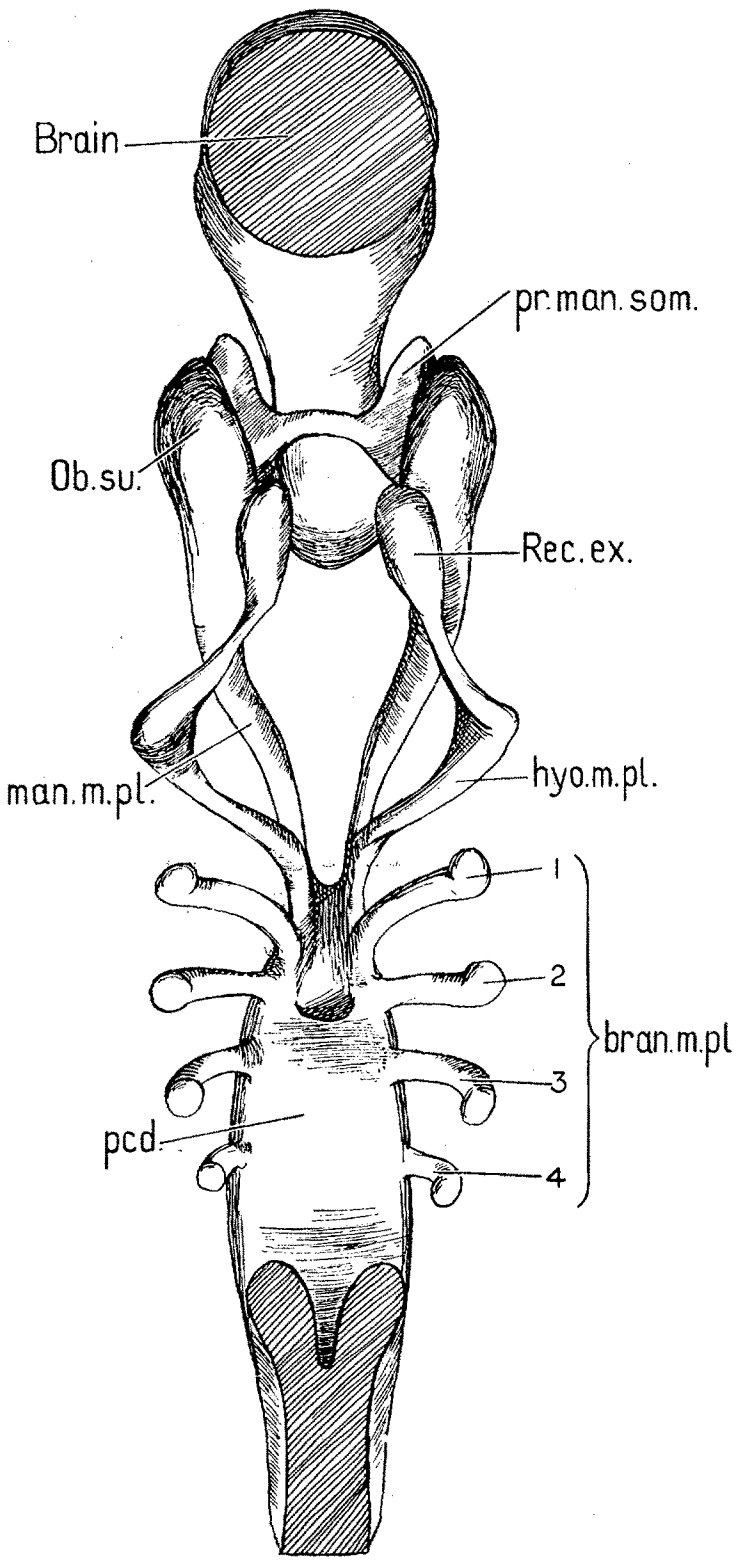
Brain
pr.man.som.
Ob.su.
Rec.ex.
man.m.pl.
hyo.m.pl.
1
2
3
4
bran.m.pl
pcd.

2

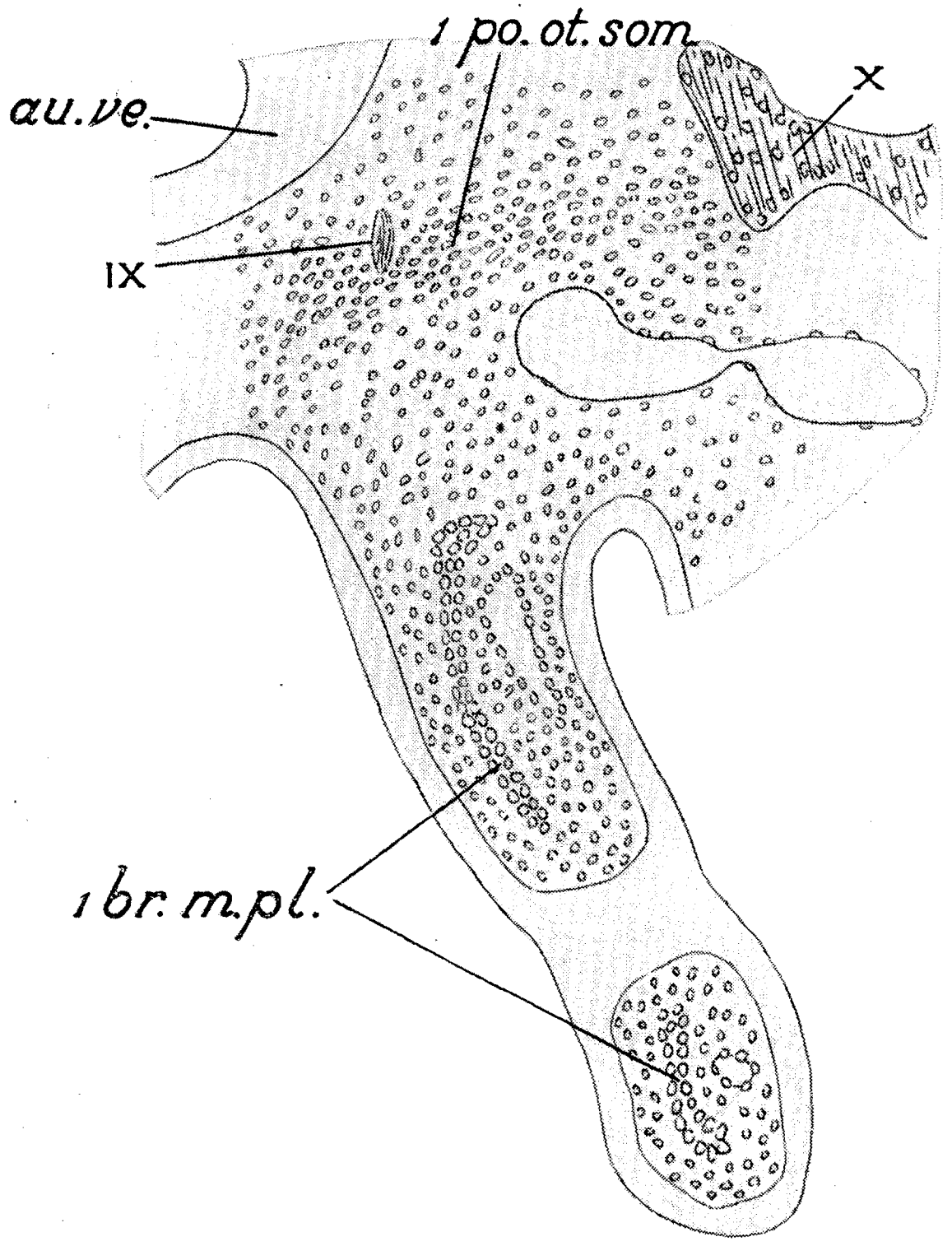
1 po.ot.som.
au.ve.
X
IX
1 br.m.pl.

3

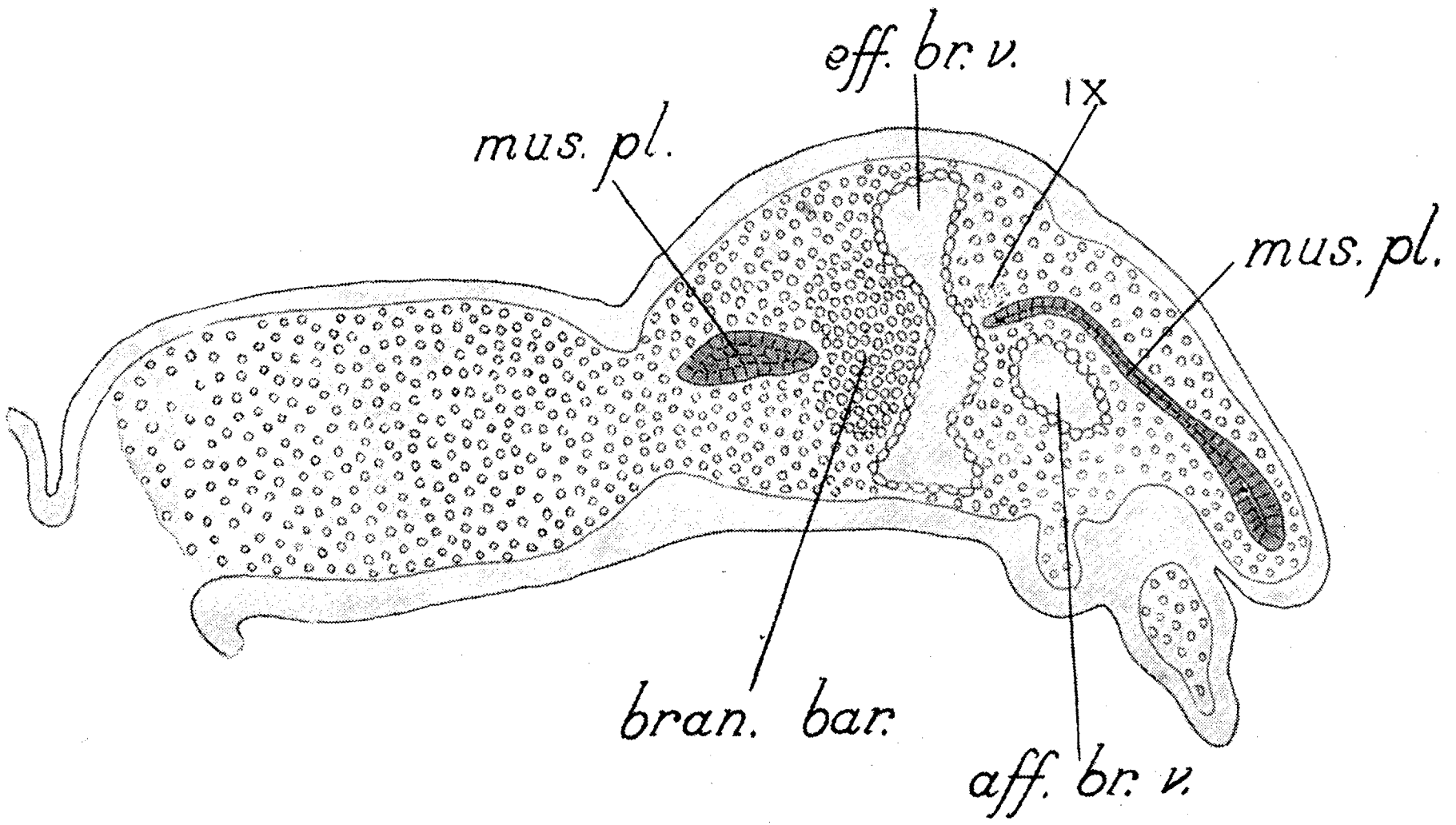
eff. br. v.
IX
mus. pl.
mus. pl.
bran. bar.
aff. br. v.

6

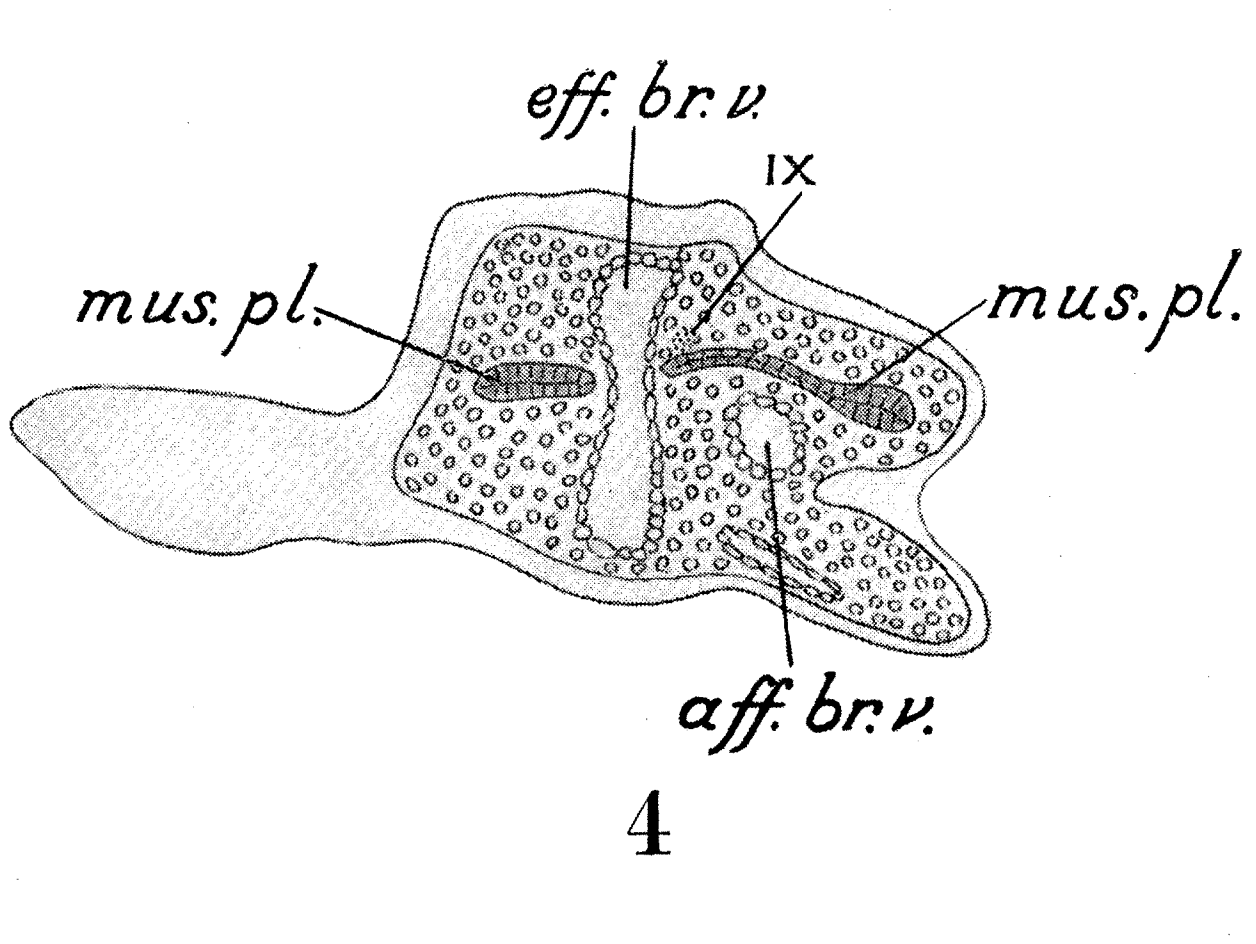
eff. br. v.
IX
mus. pl.
mus. pl.
aff. br. v.

4

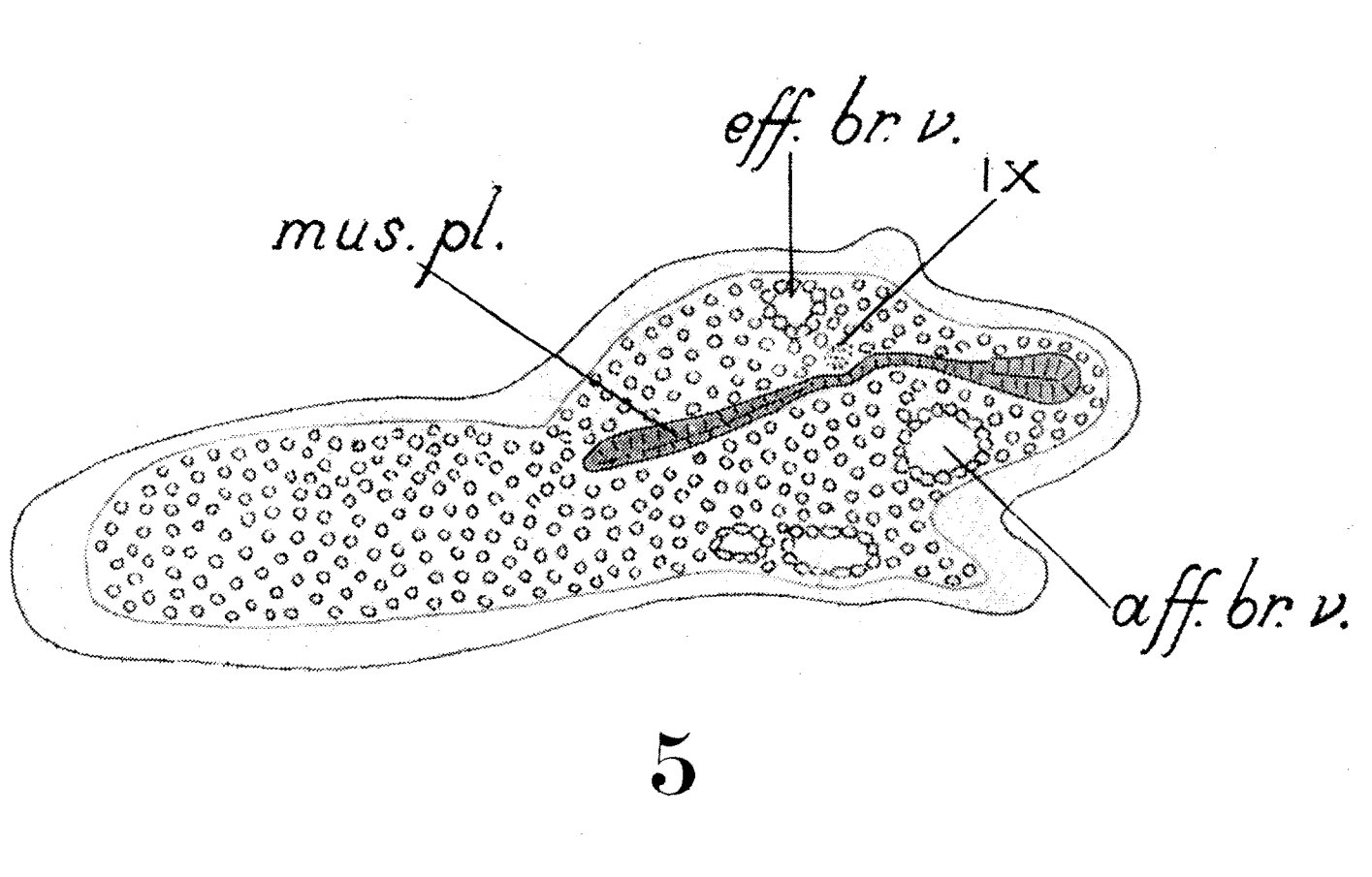
eff. br. v.
IX
mus. pl.
aff. br. v.

5

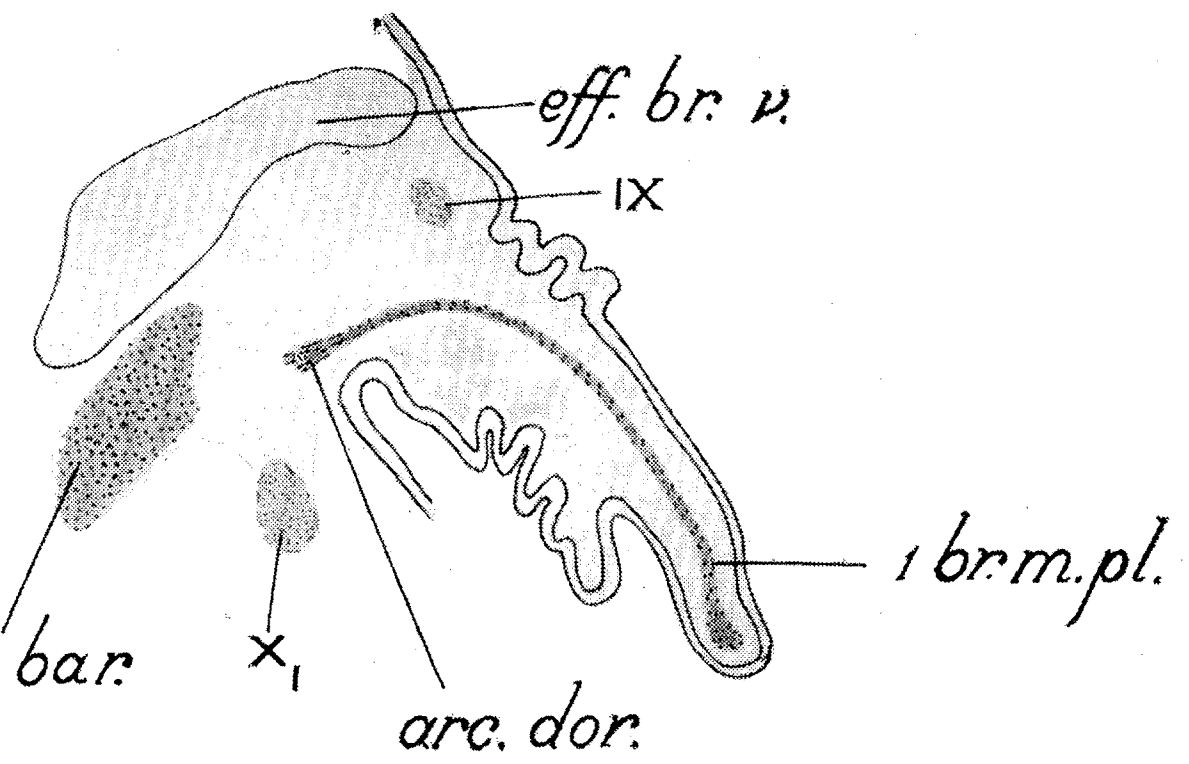
eff. br. v.
IX
1 br. bar.
X1
arc. dor.
1 br. m. pl.

7

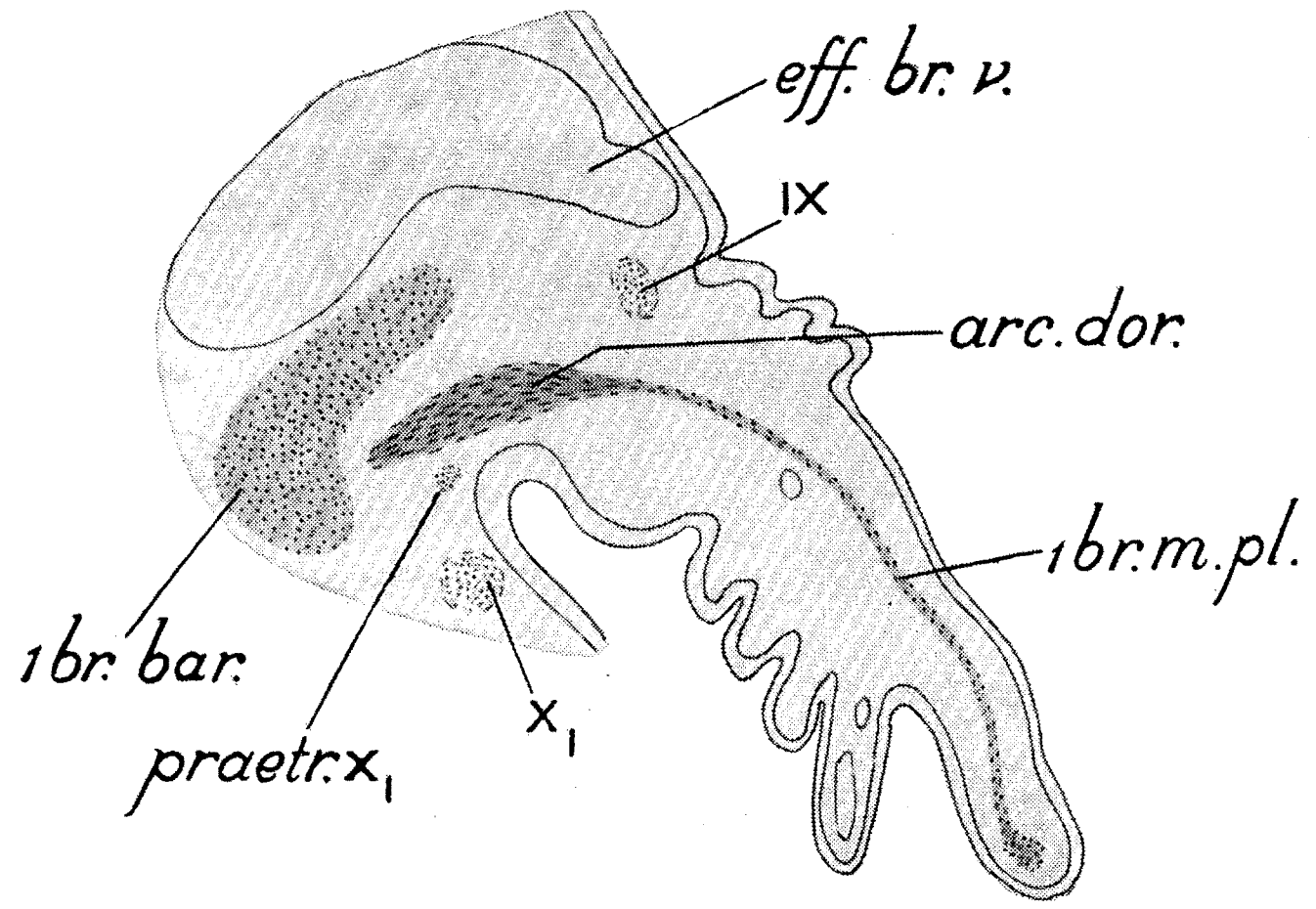
eff. br. v.
IX
arc. dor.
1 br. m. pl.
1 br. bar.
praetr. X1
X1

8

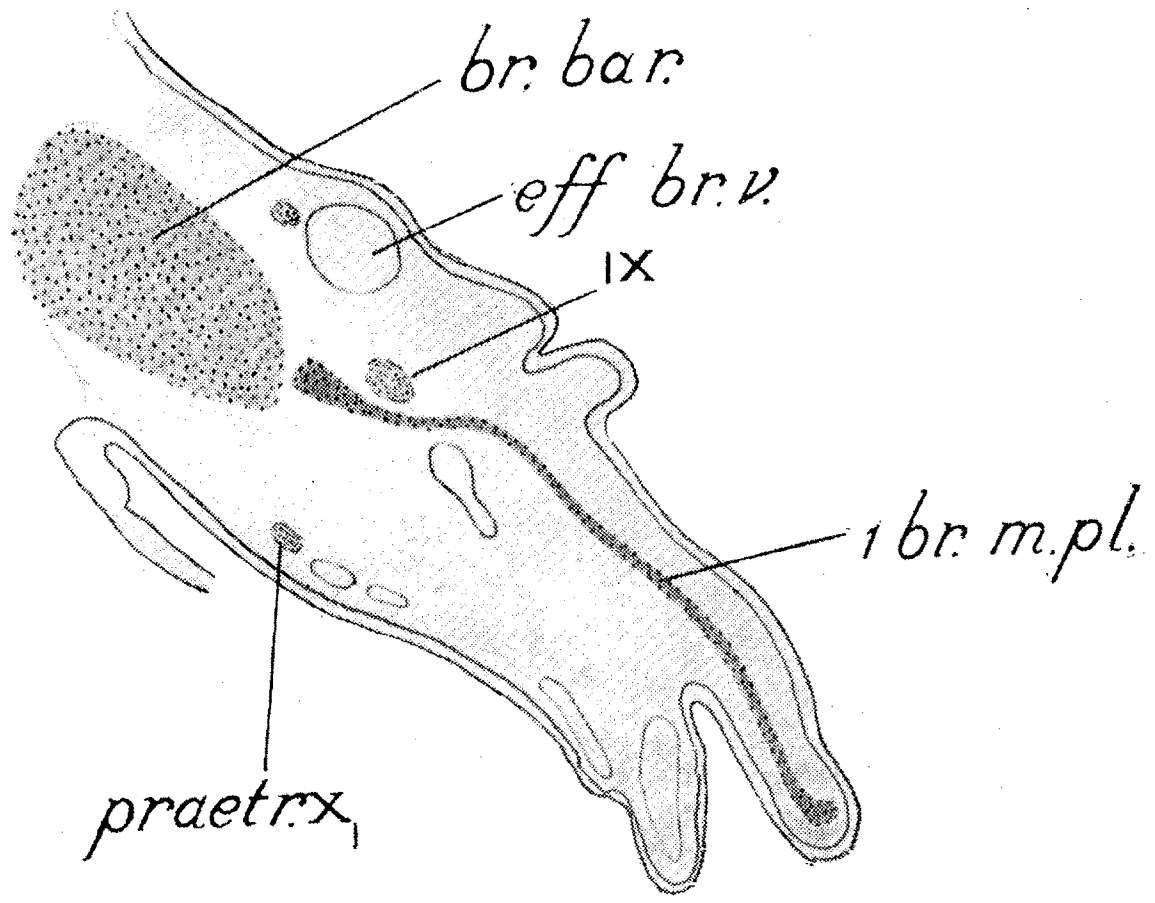
br. bar.
eff. br. v.
IX
1 br. m. pl.
praetr. X1

9

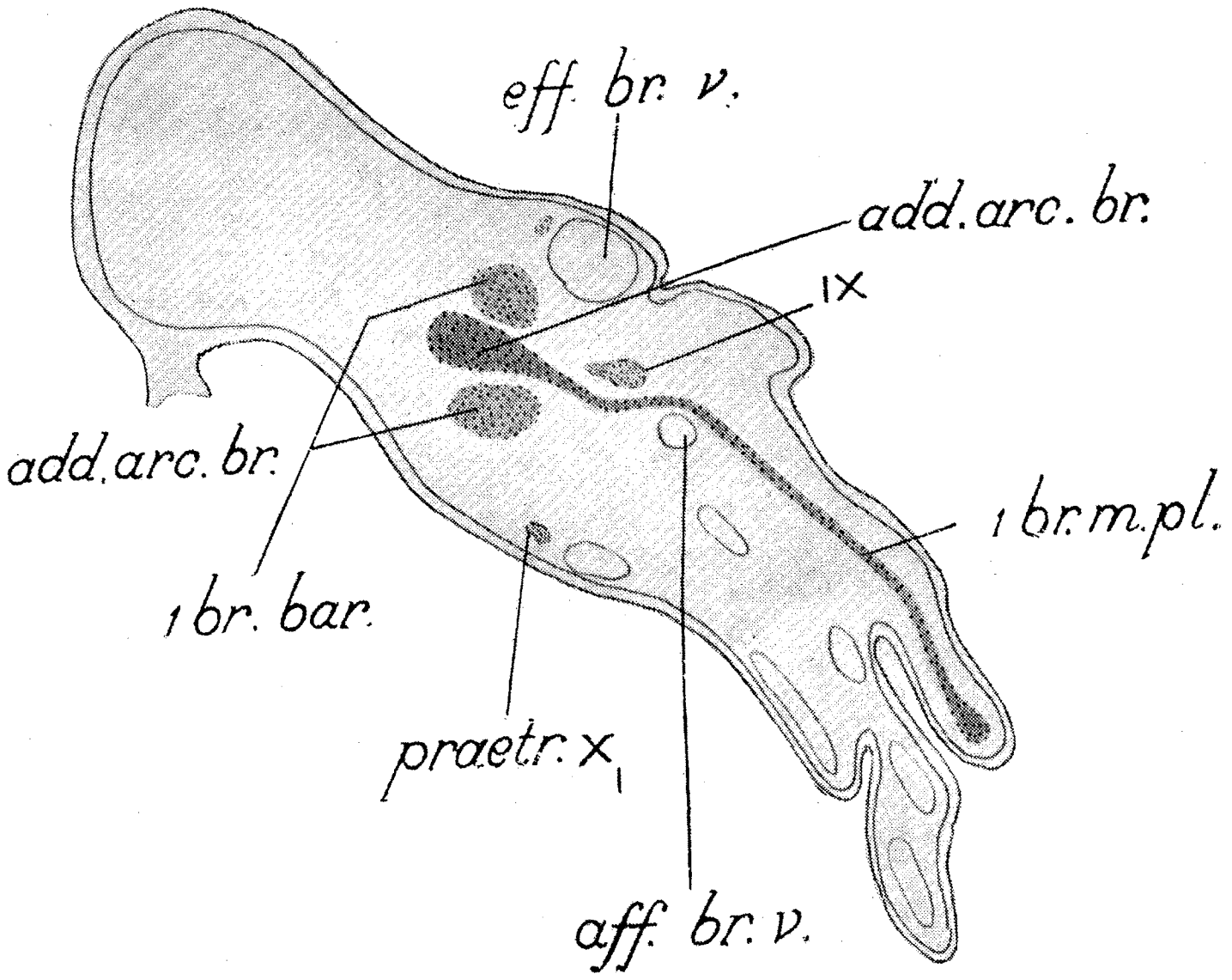
eff. br. v.
add. arc. br.
IX
add. arc. br.
1 br. m. pl.
1 br. bar.
praetr. X1
aff. br. v.

10

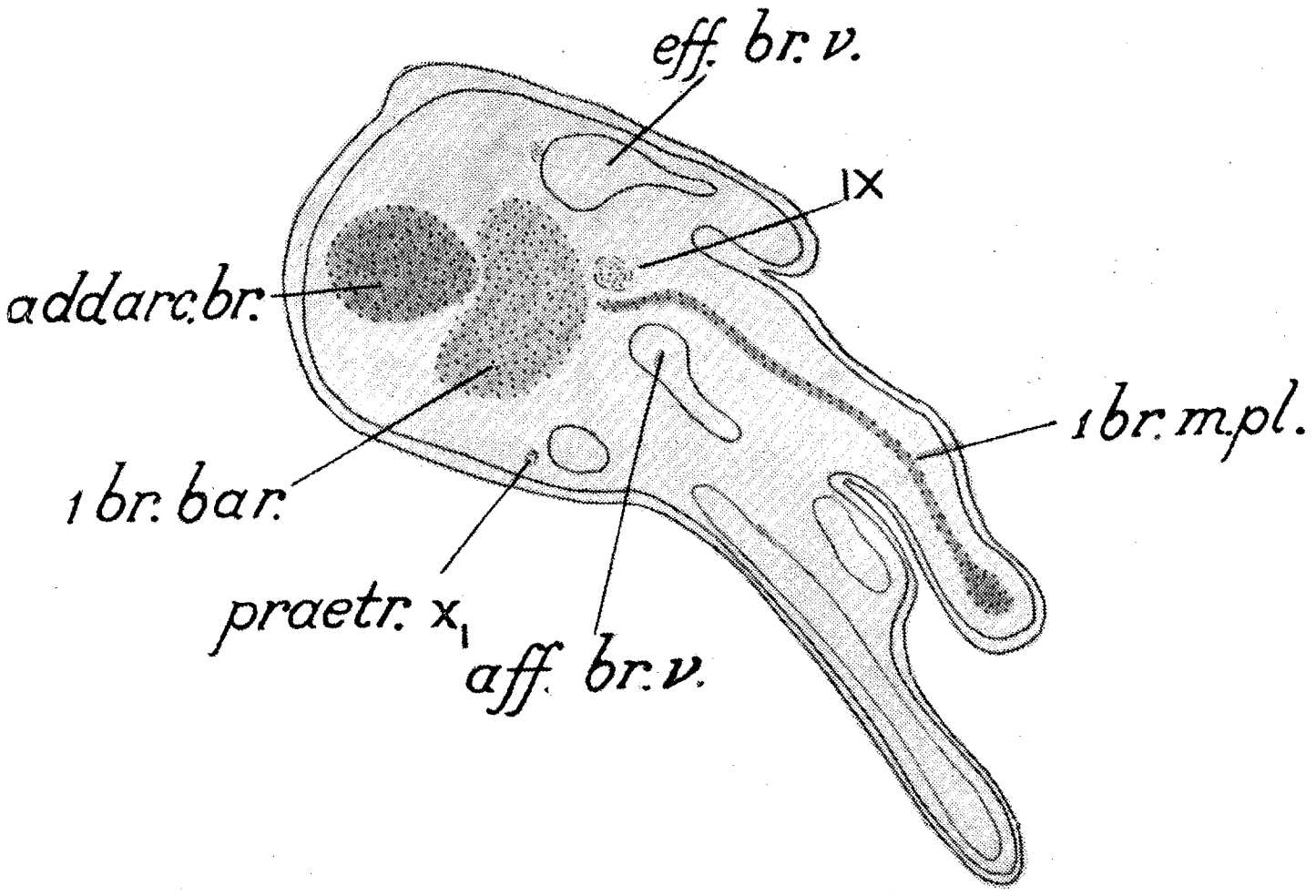
eff. br. v.
IX
add arc. br.
1 br. m. pl.
1 br. bar.
praetr. X1
aff. br. v.

11

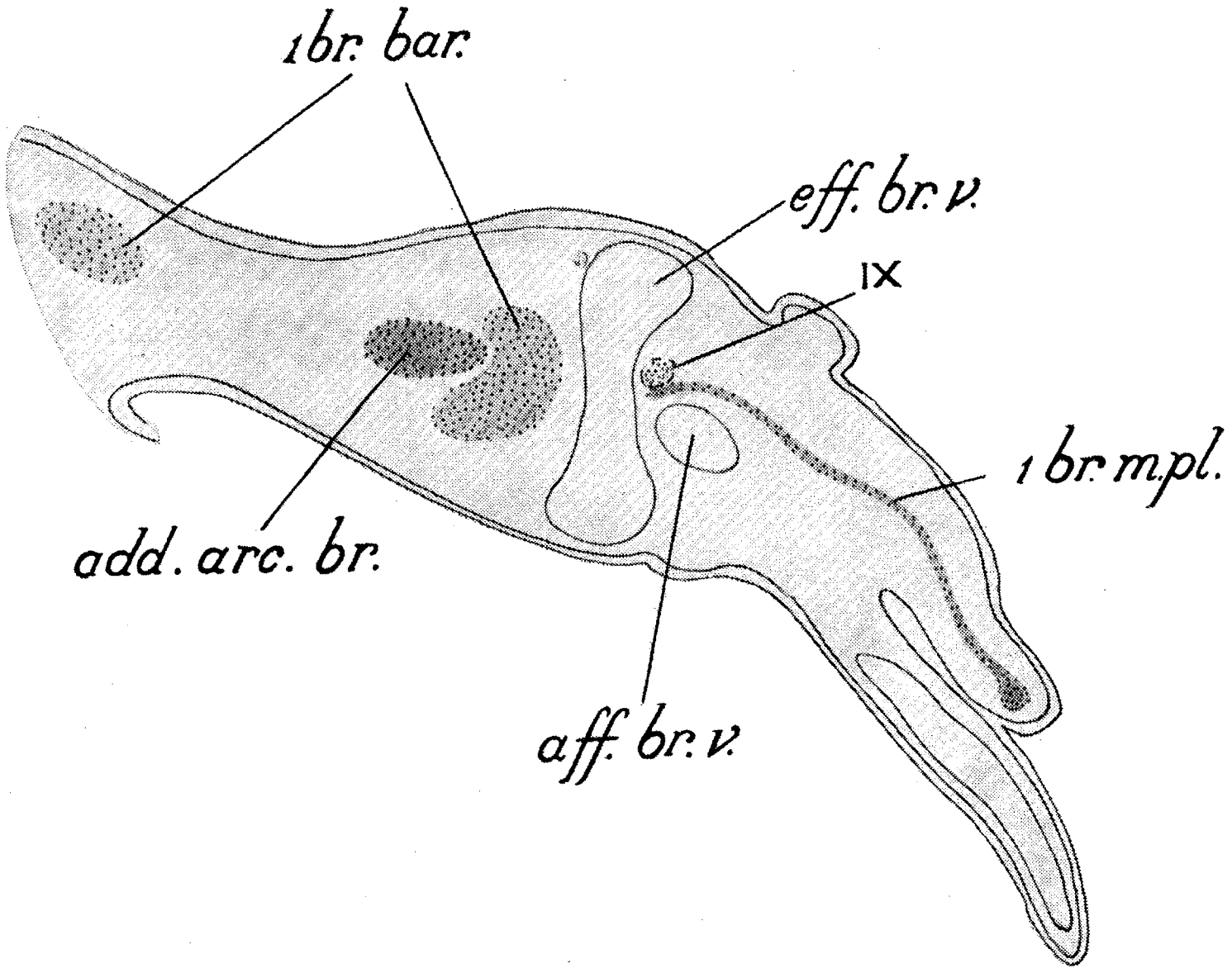
1 br. bar.
eff. br. v.
IX
1 br. m. pl.
add. arc. br.
aff. br. v.

12

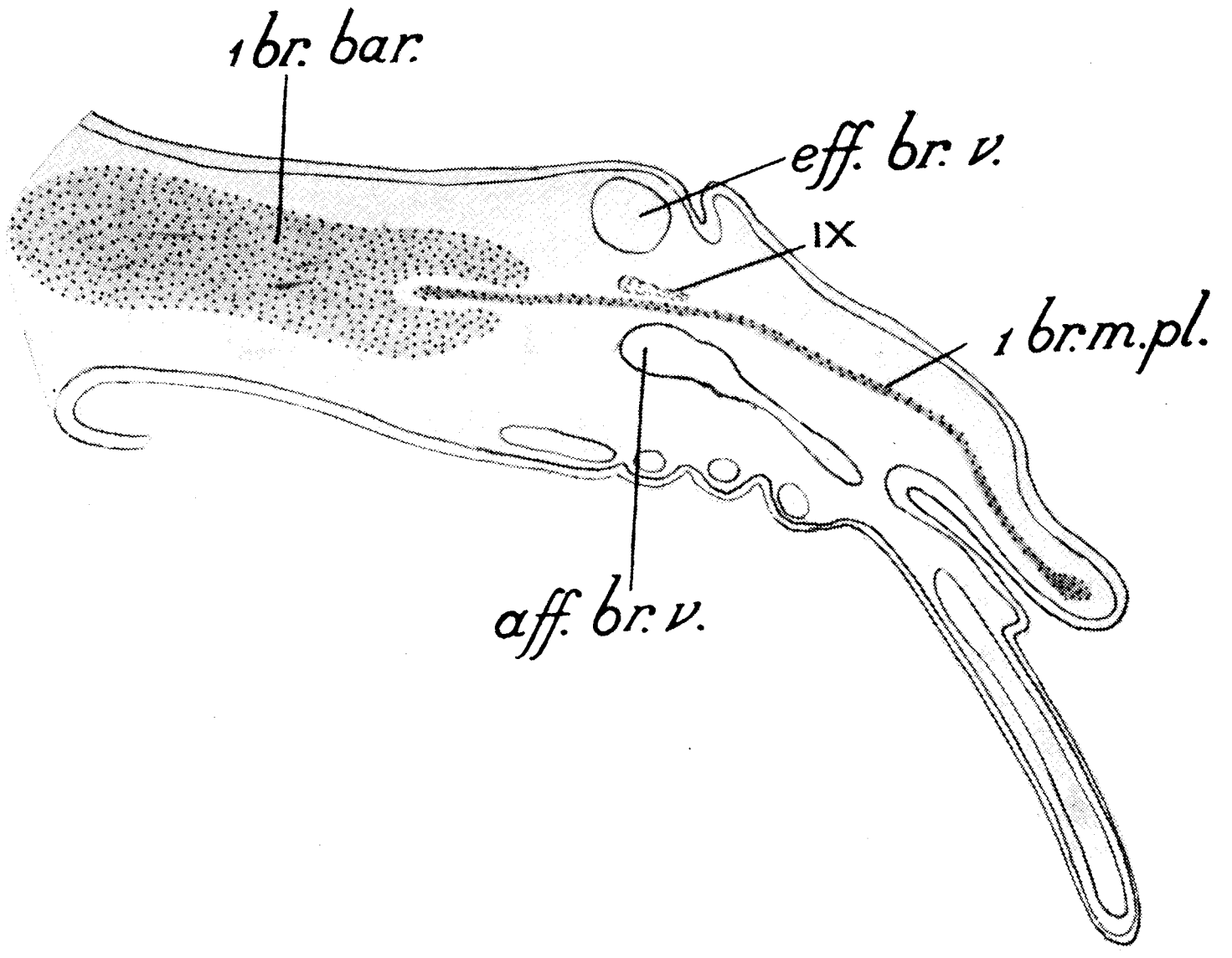

13

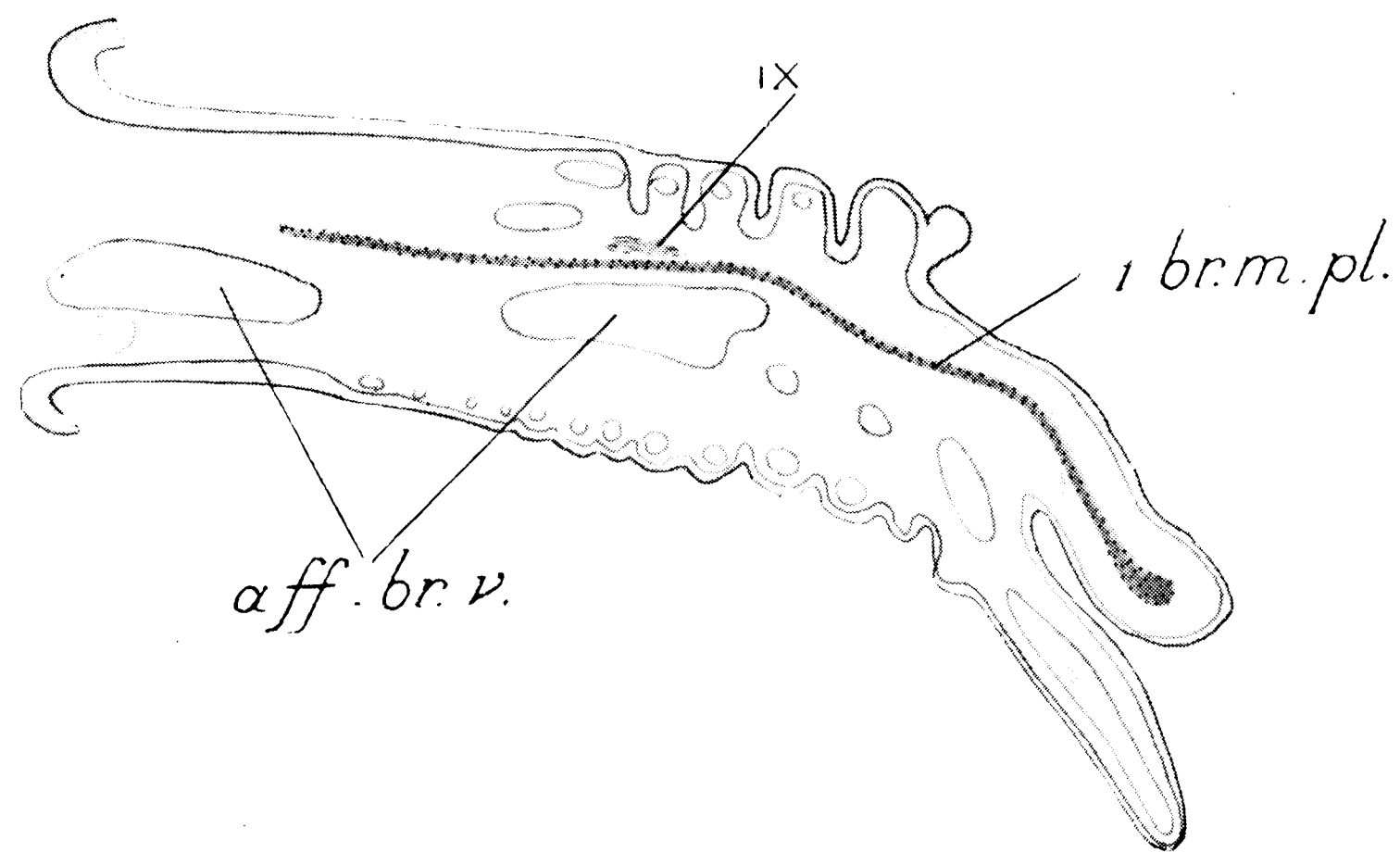

14

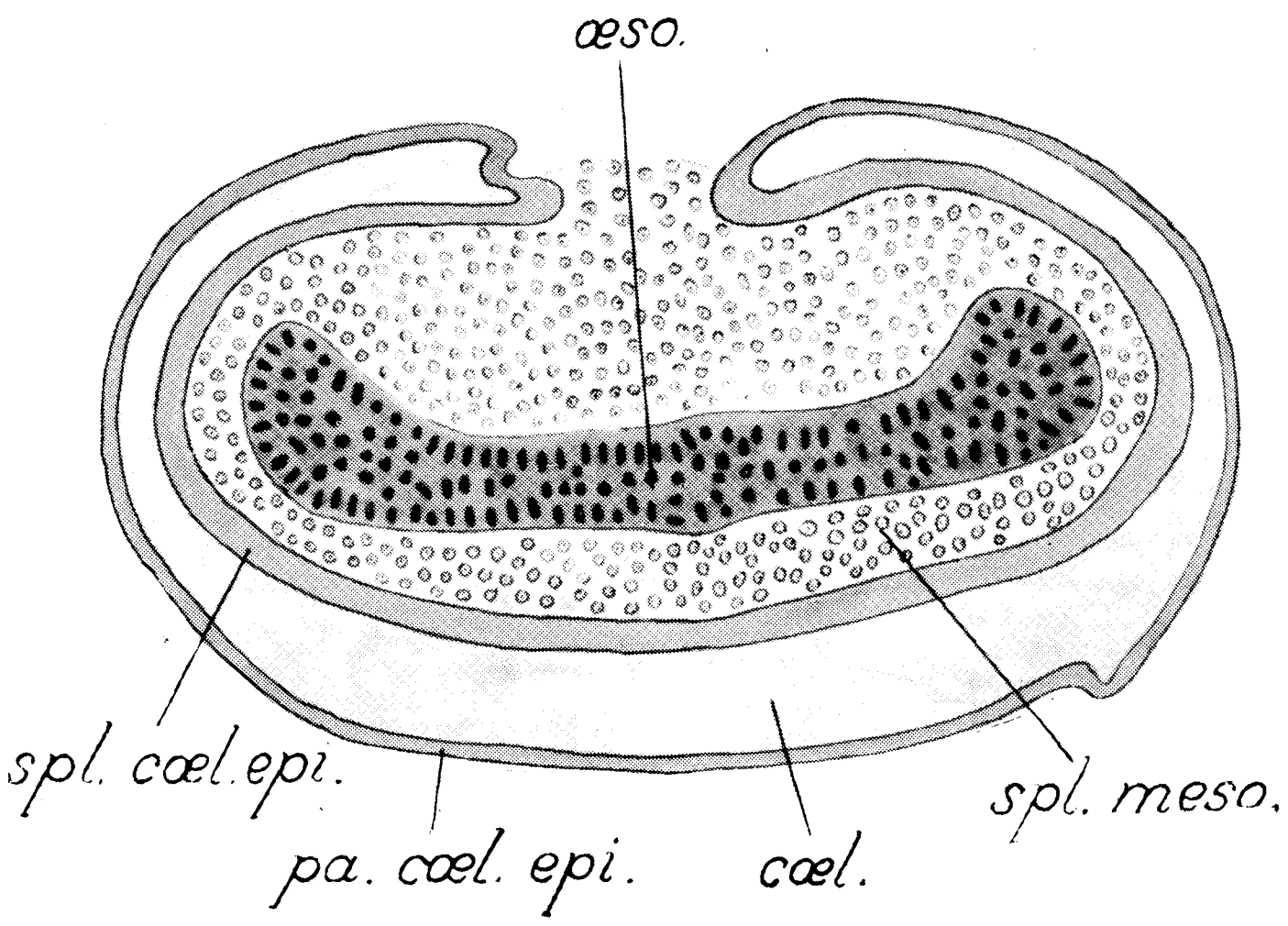

15

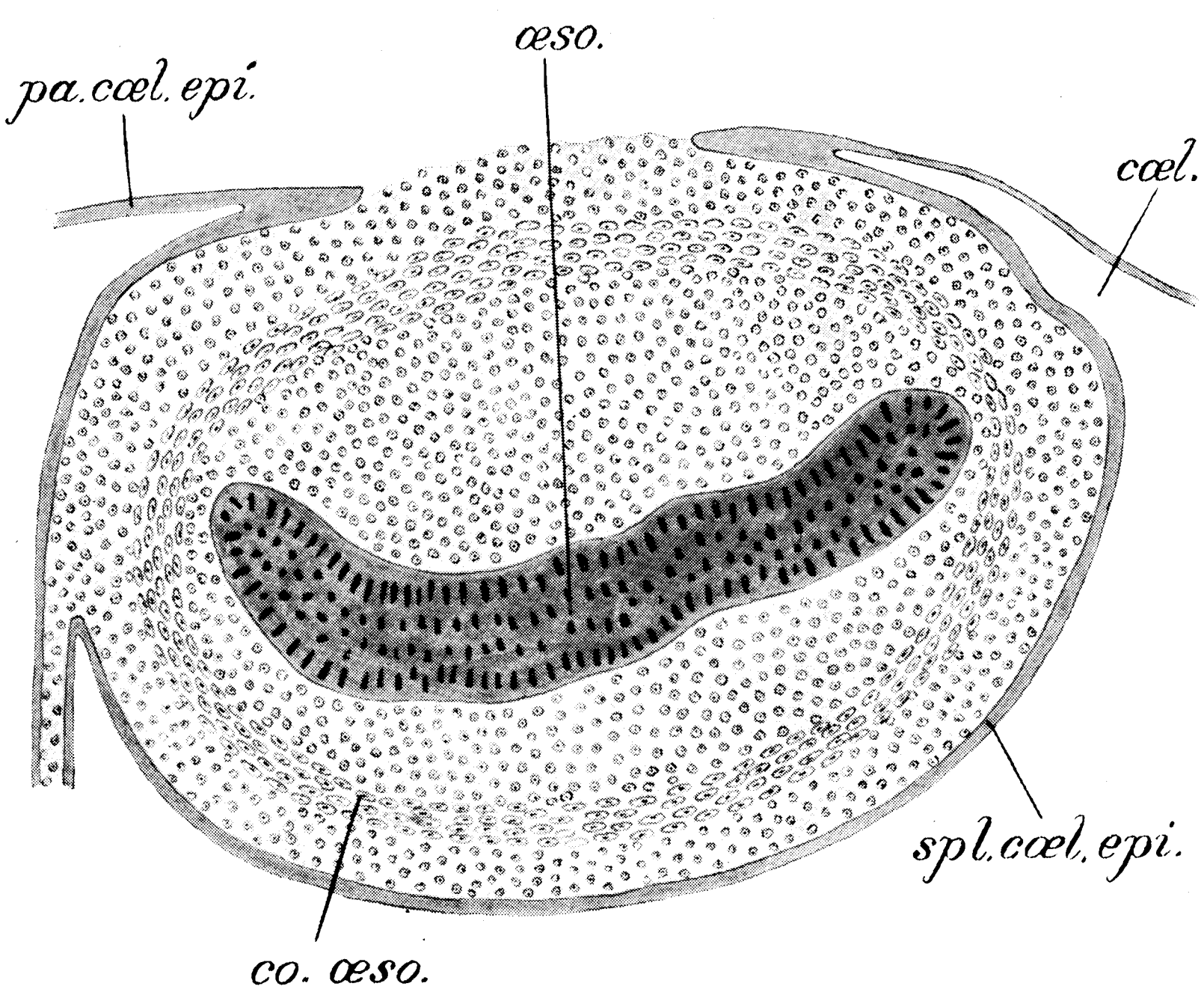

16

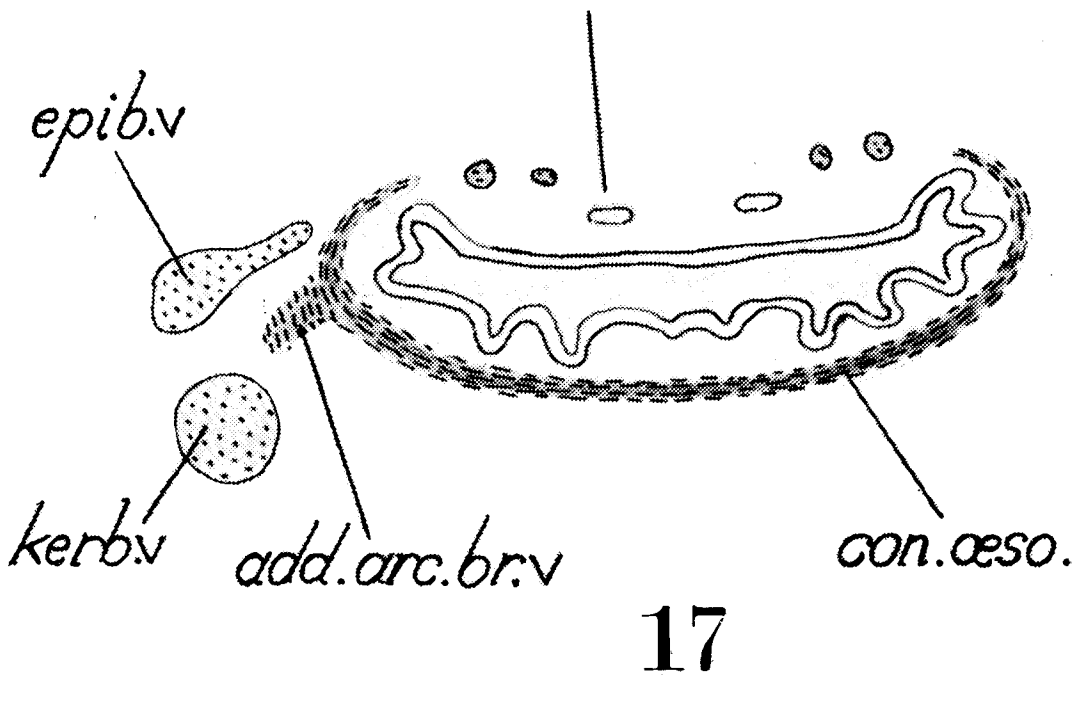

17

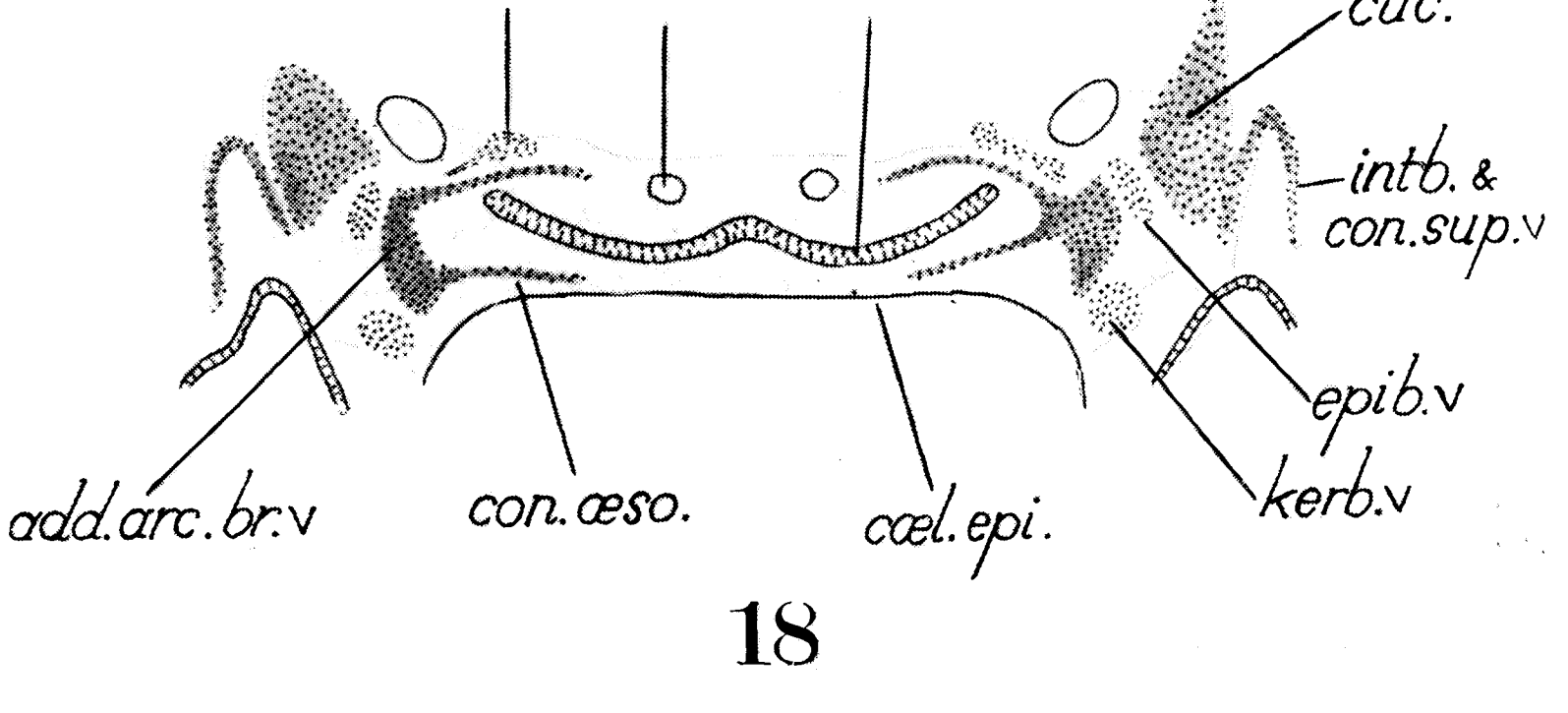

18

19

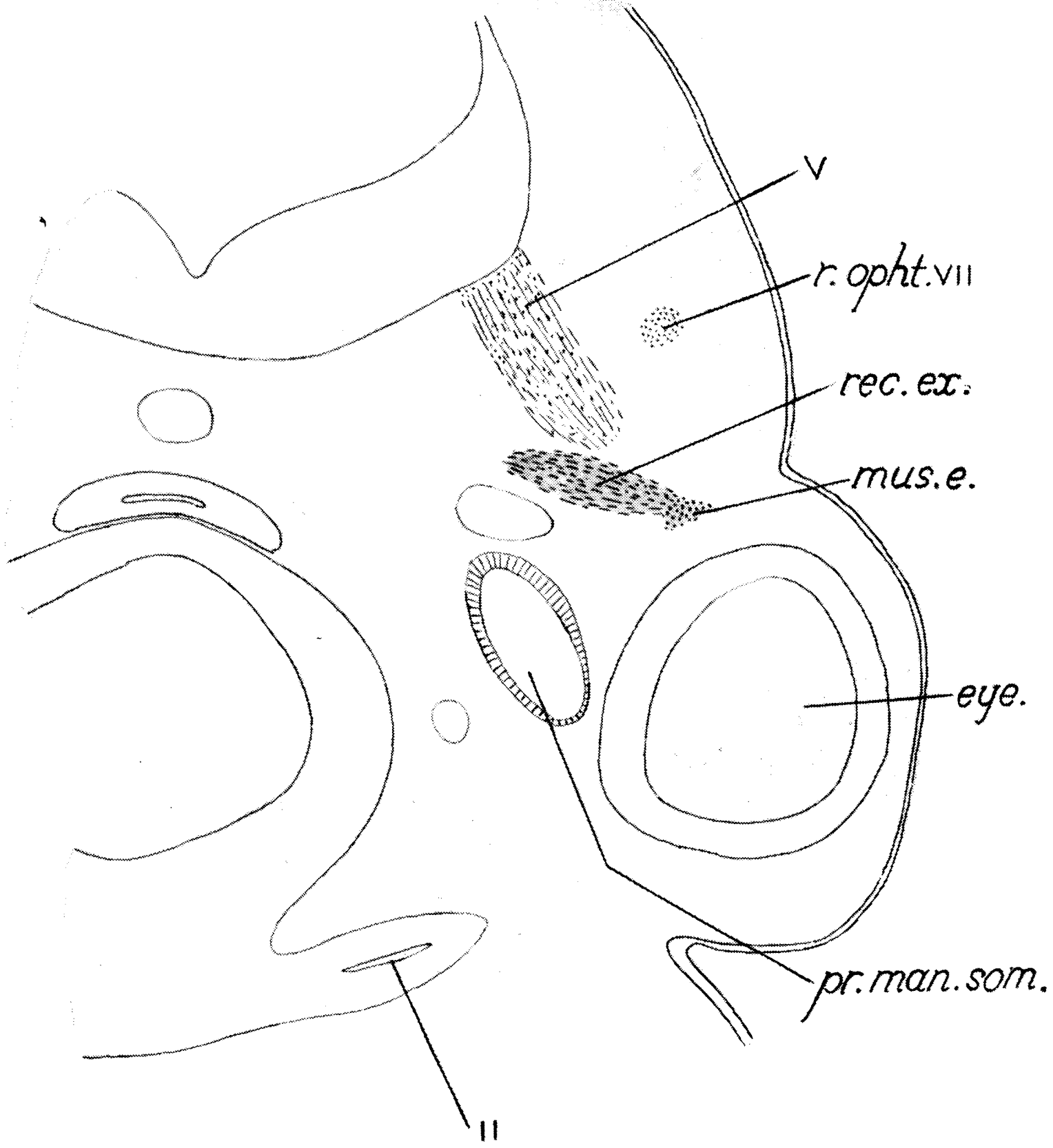

20

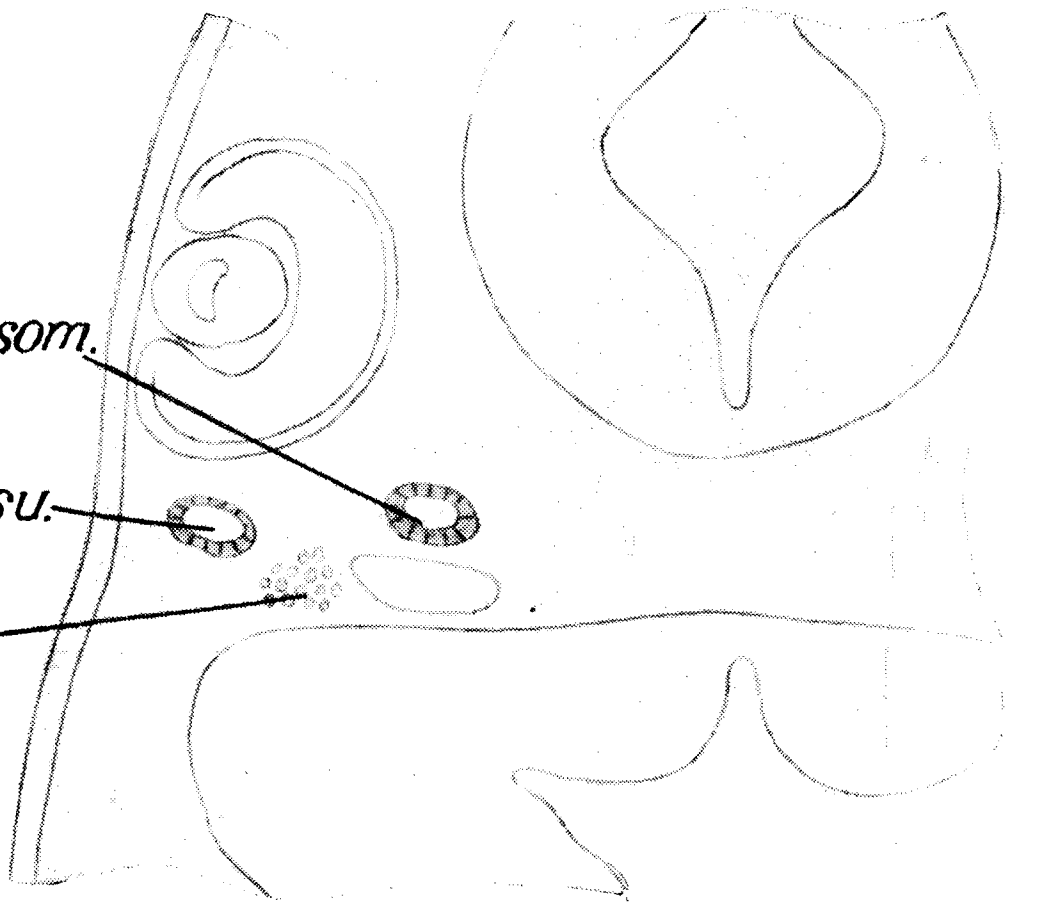

21

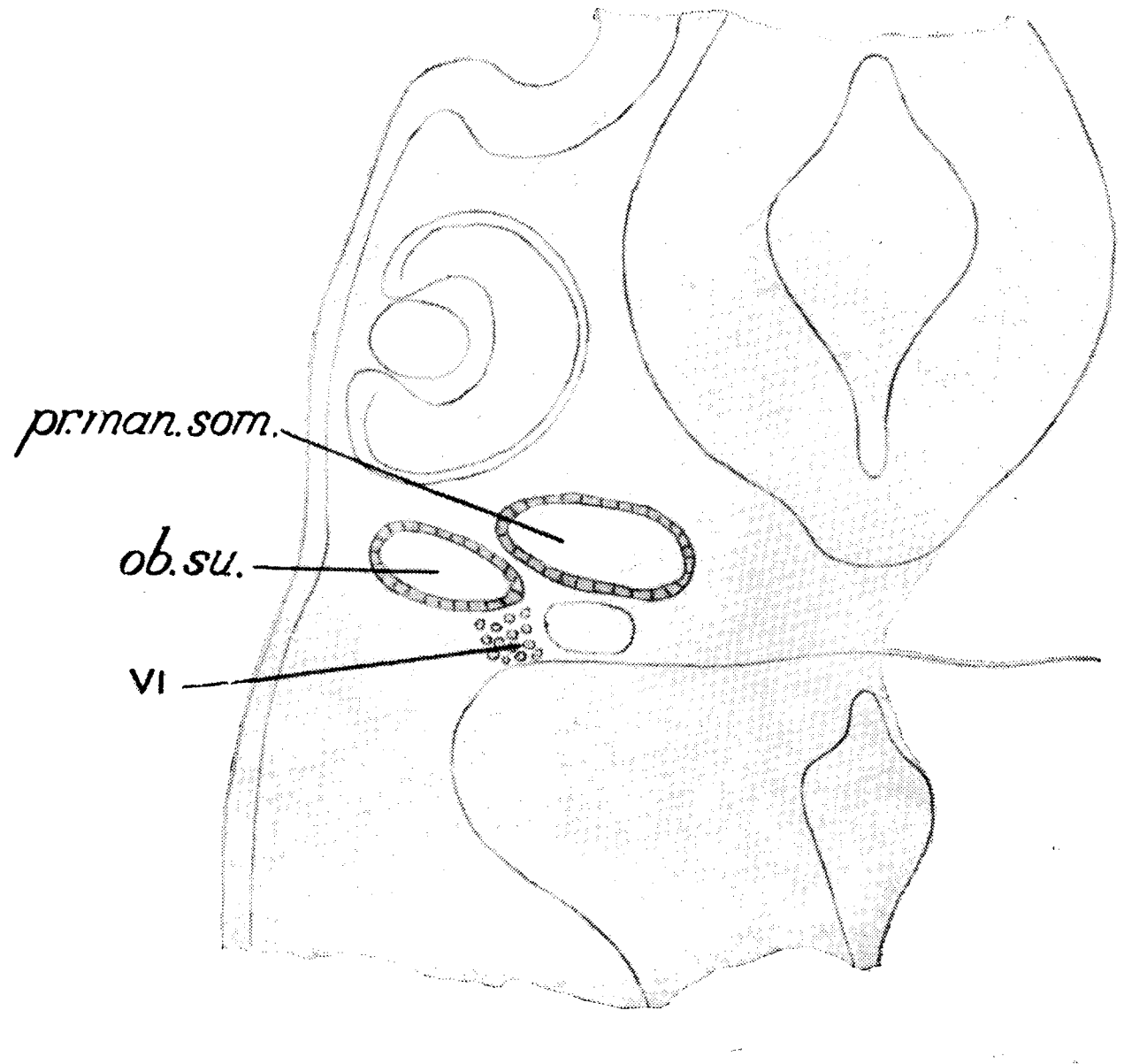

22

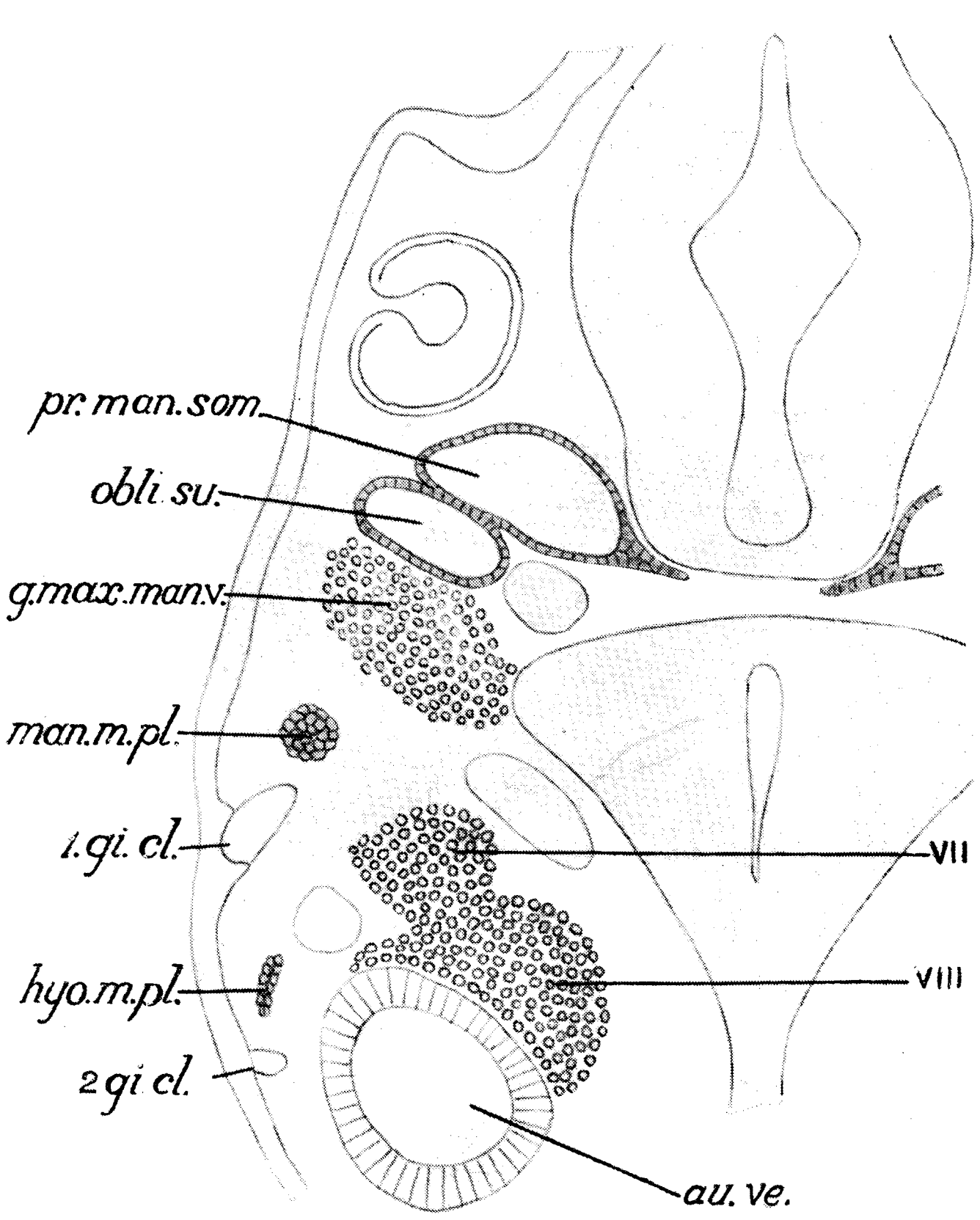

23

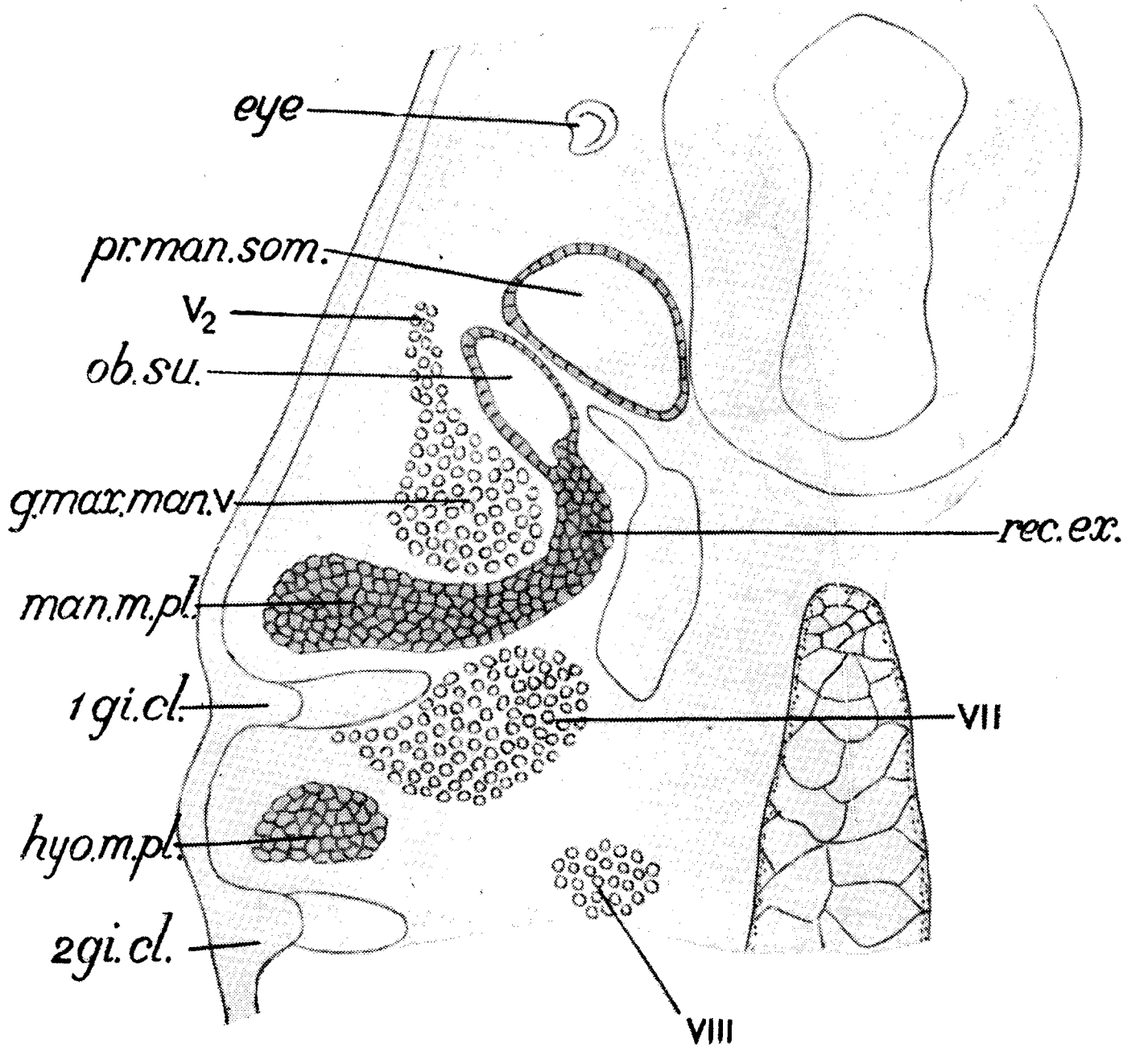

24

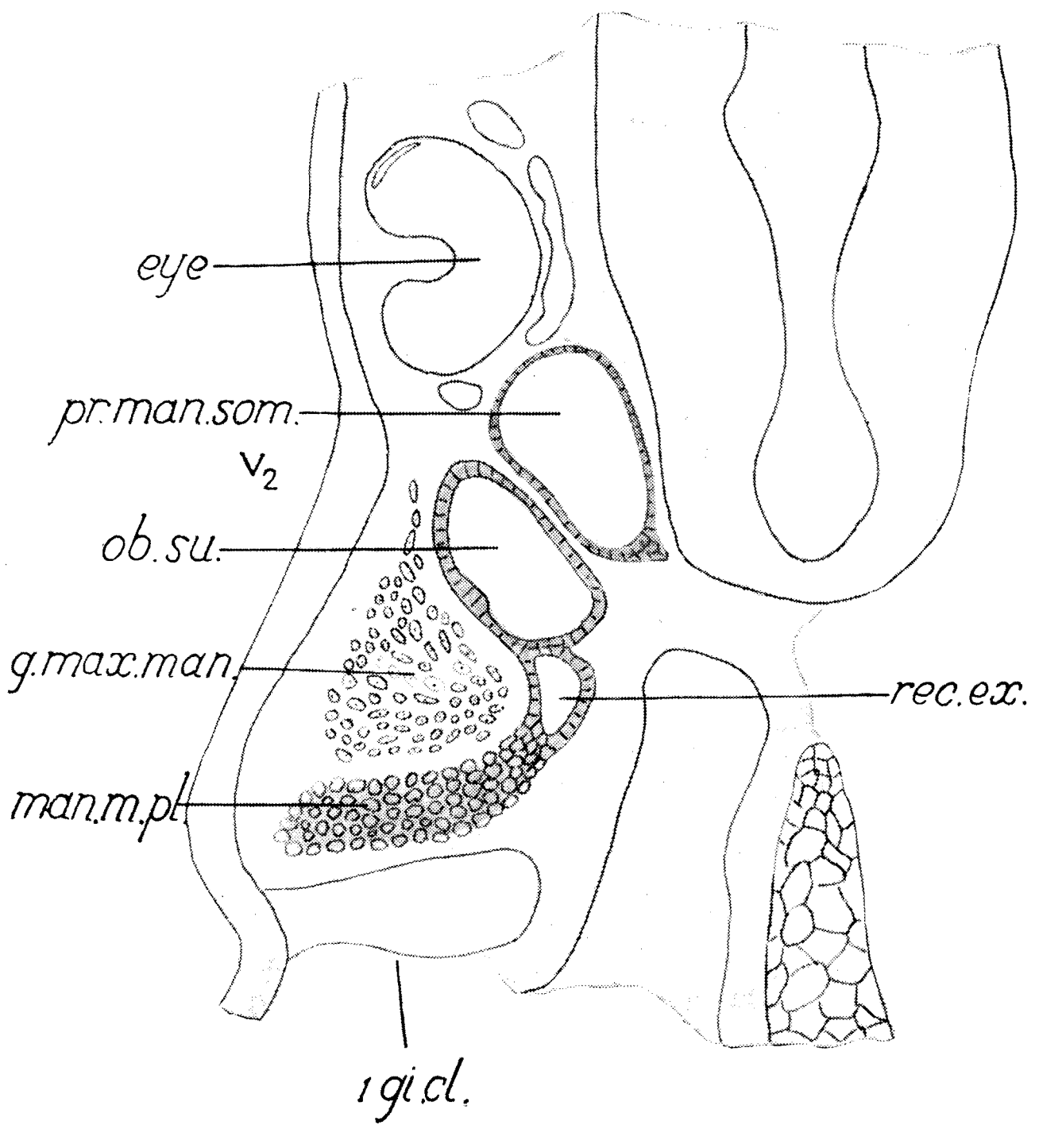

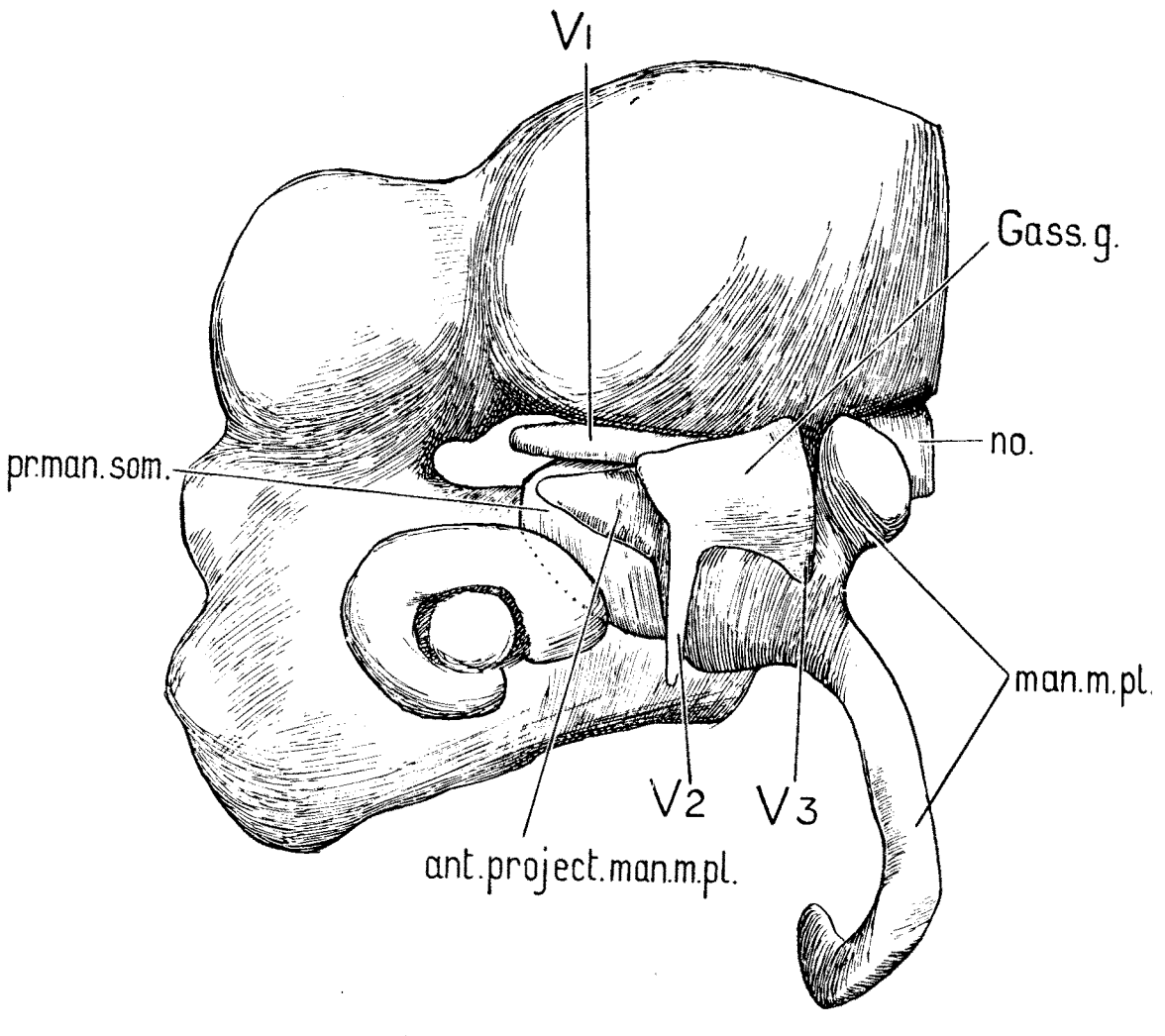

25

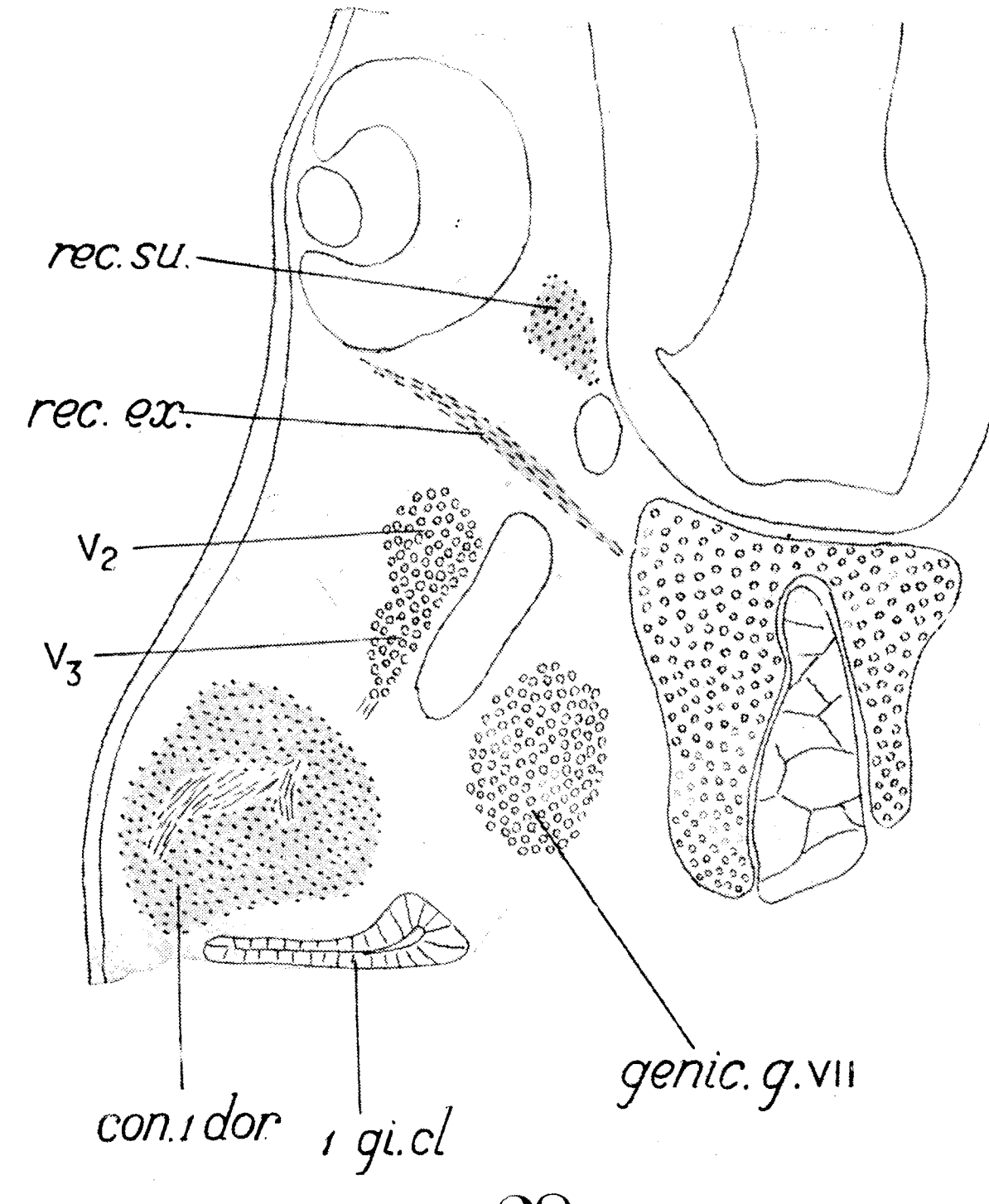

28

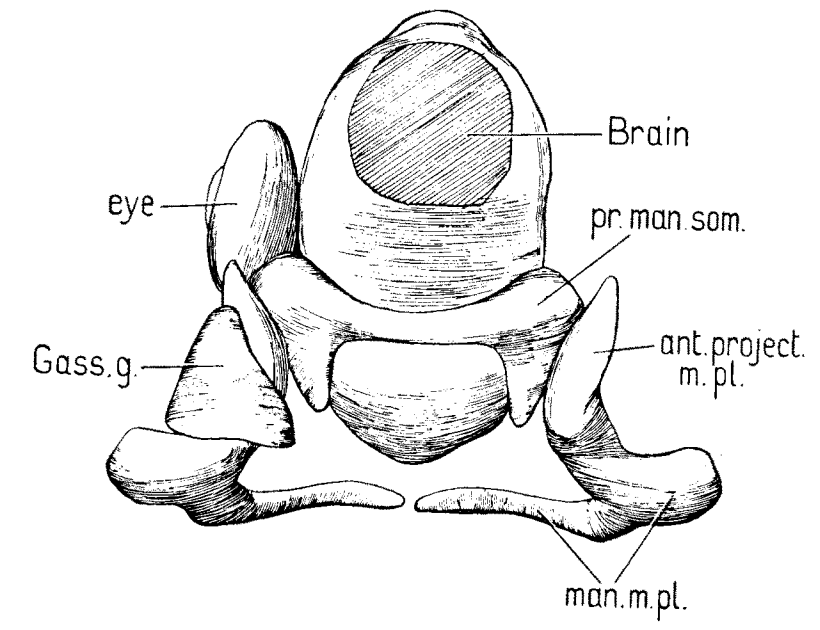

26

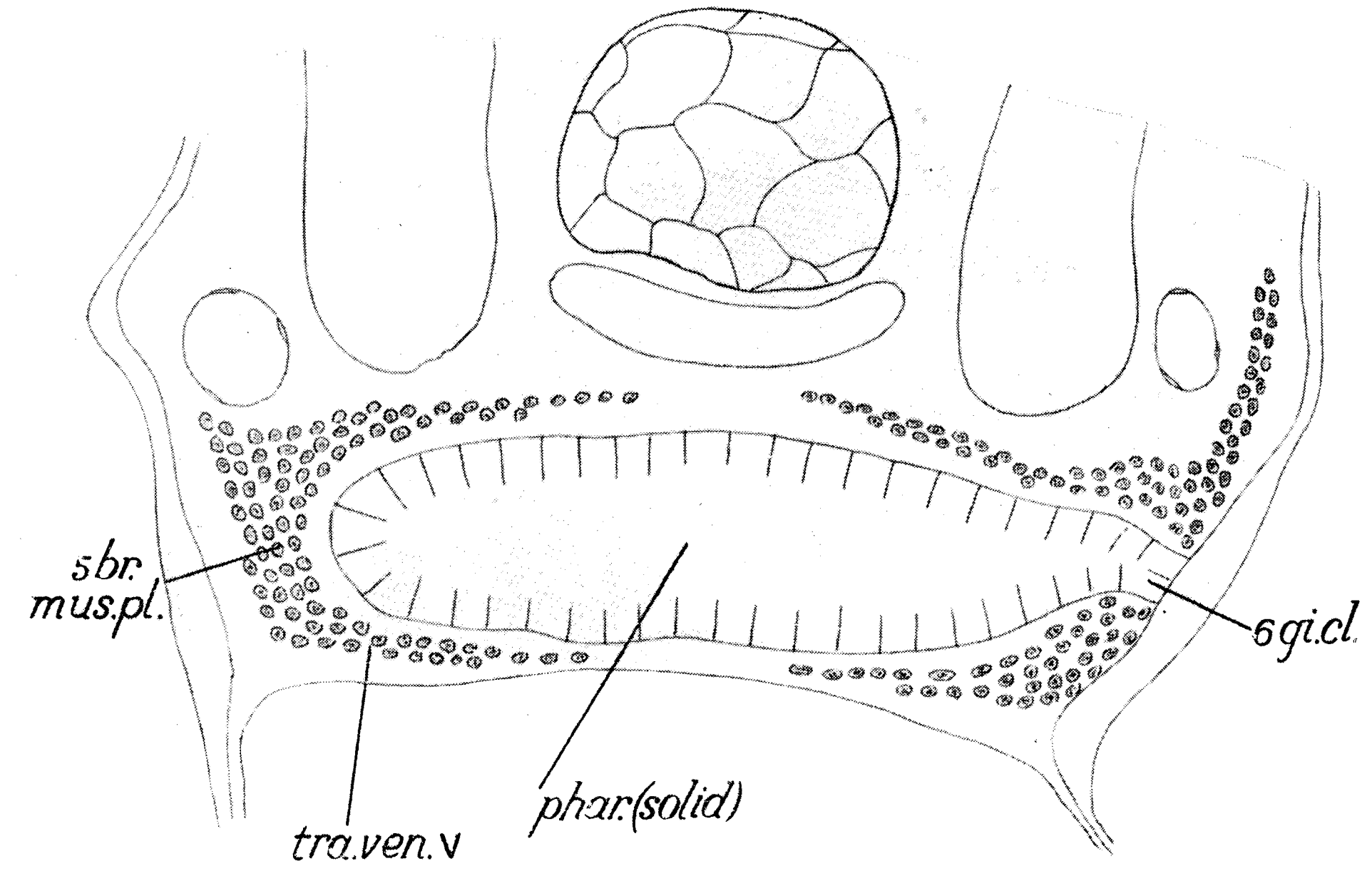

29

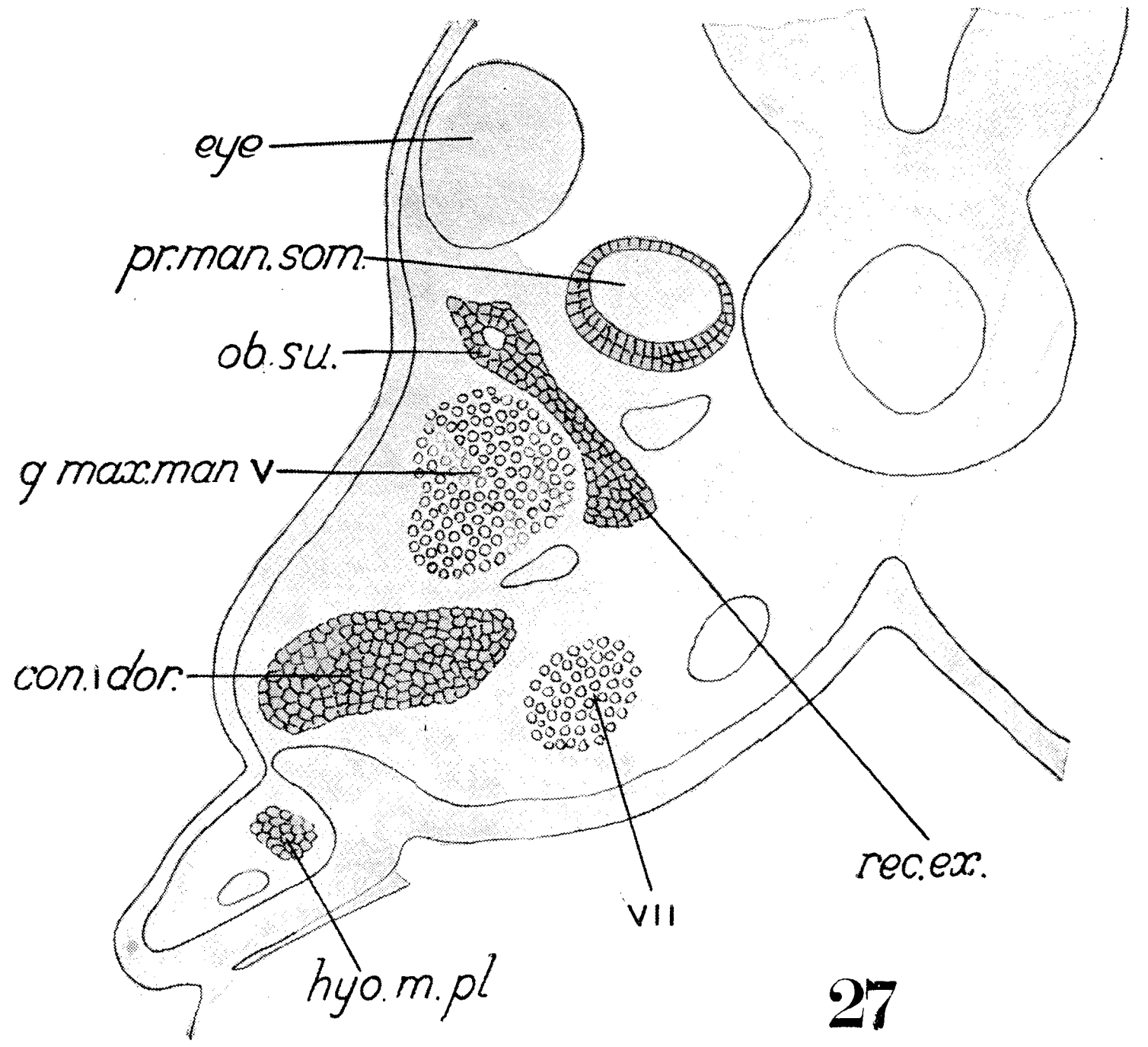

27

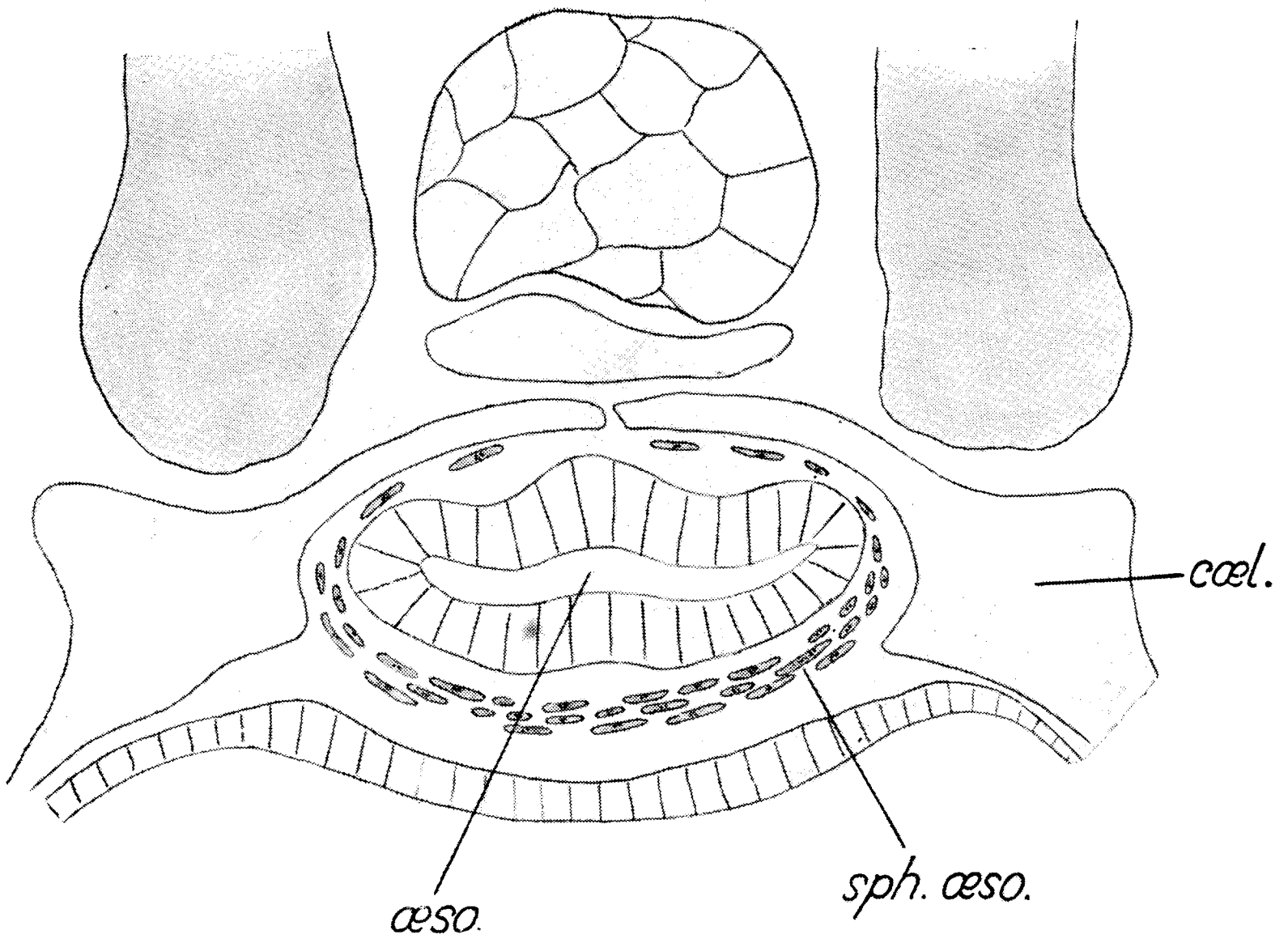

30

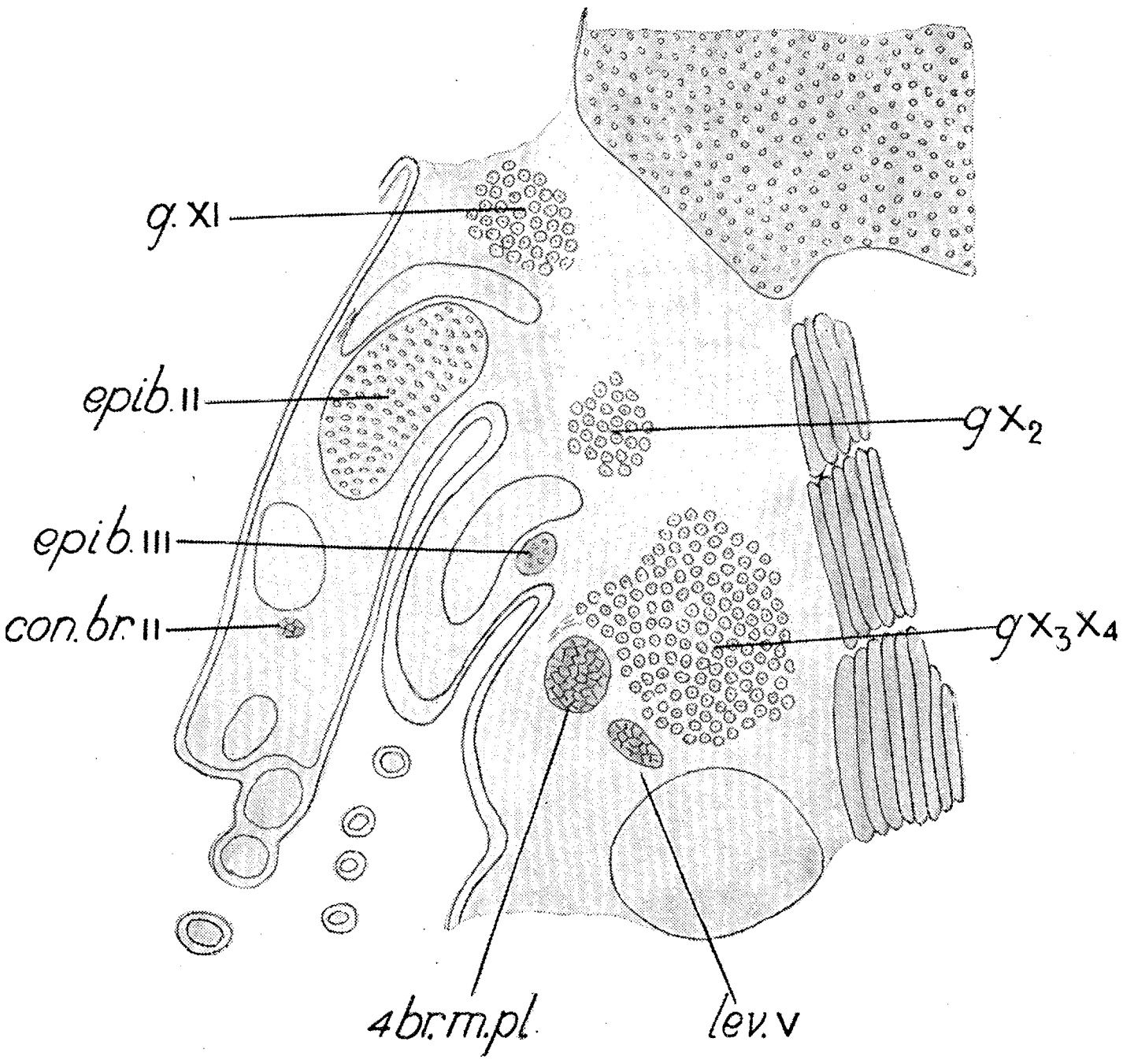

31

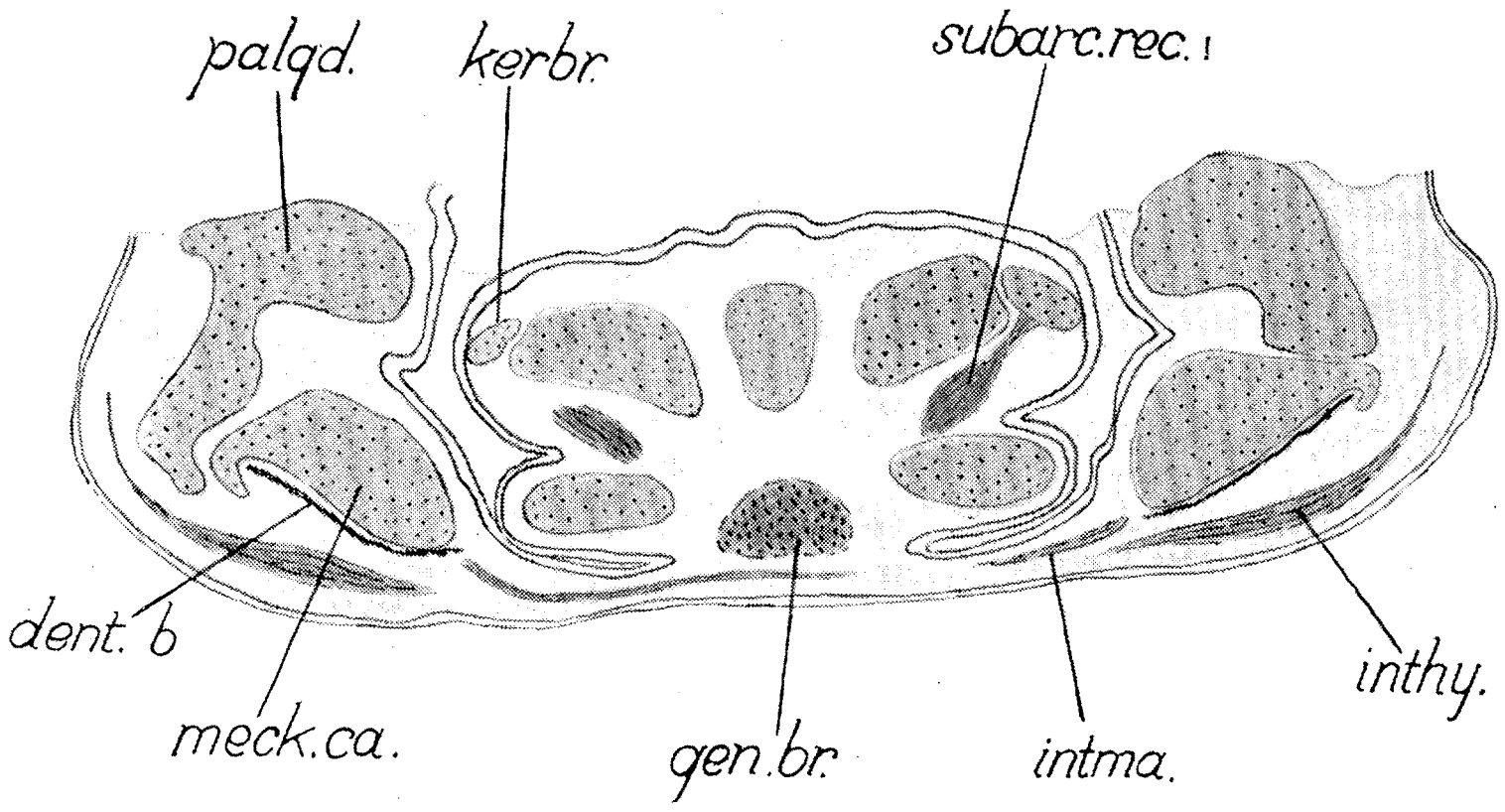

34

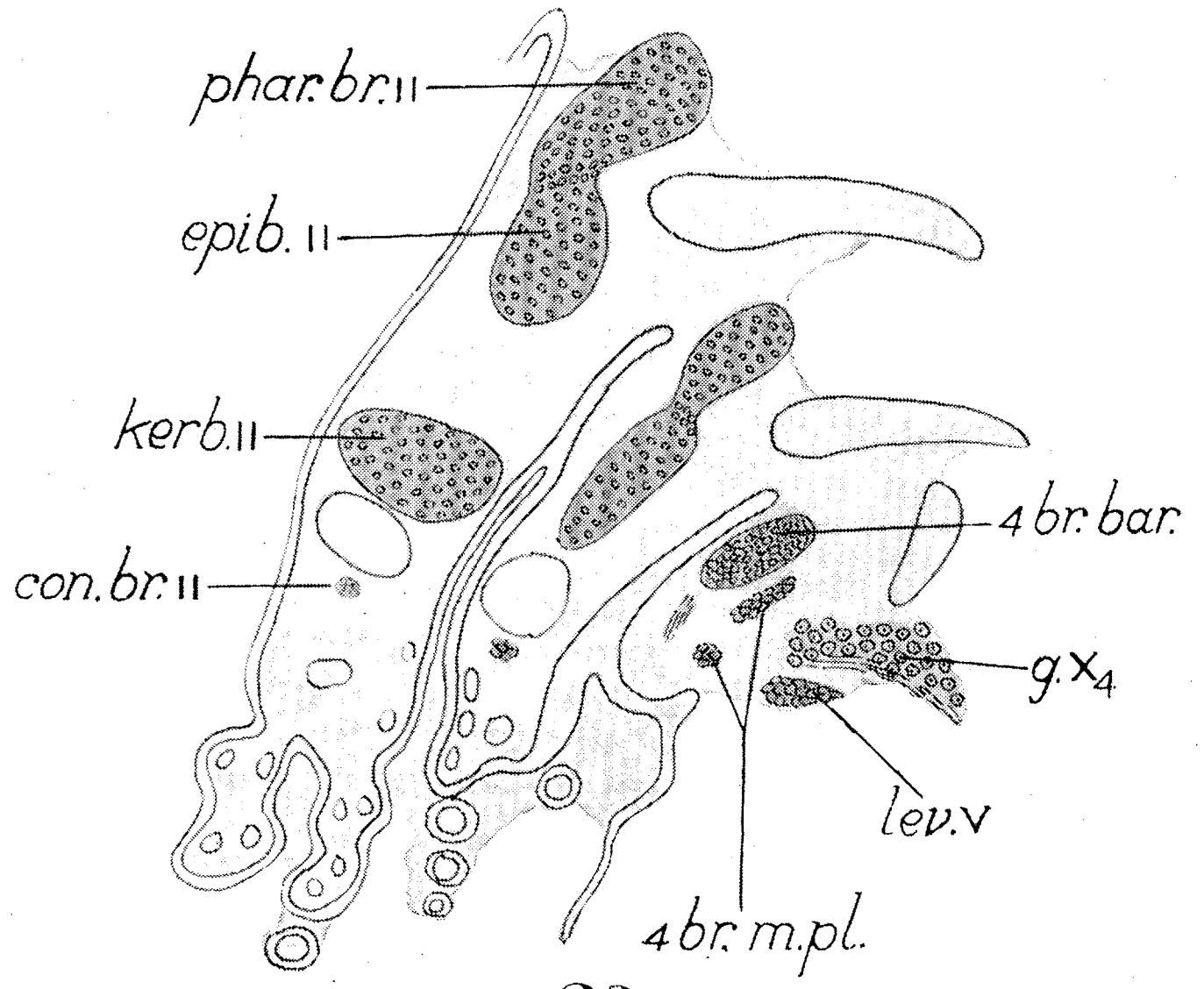

32

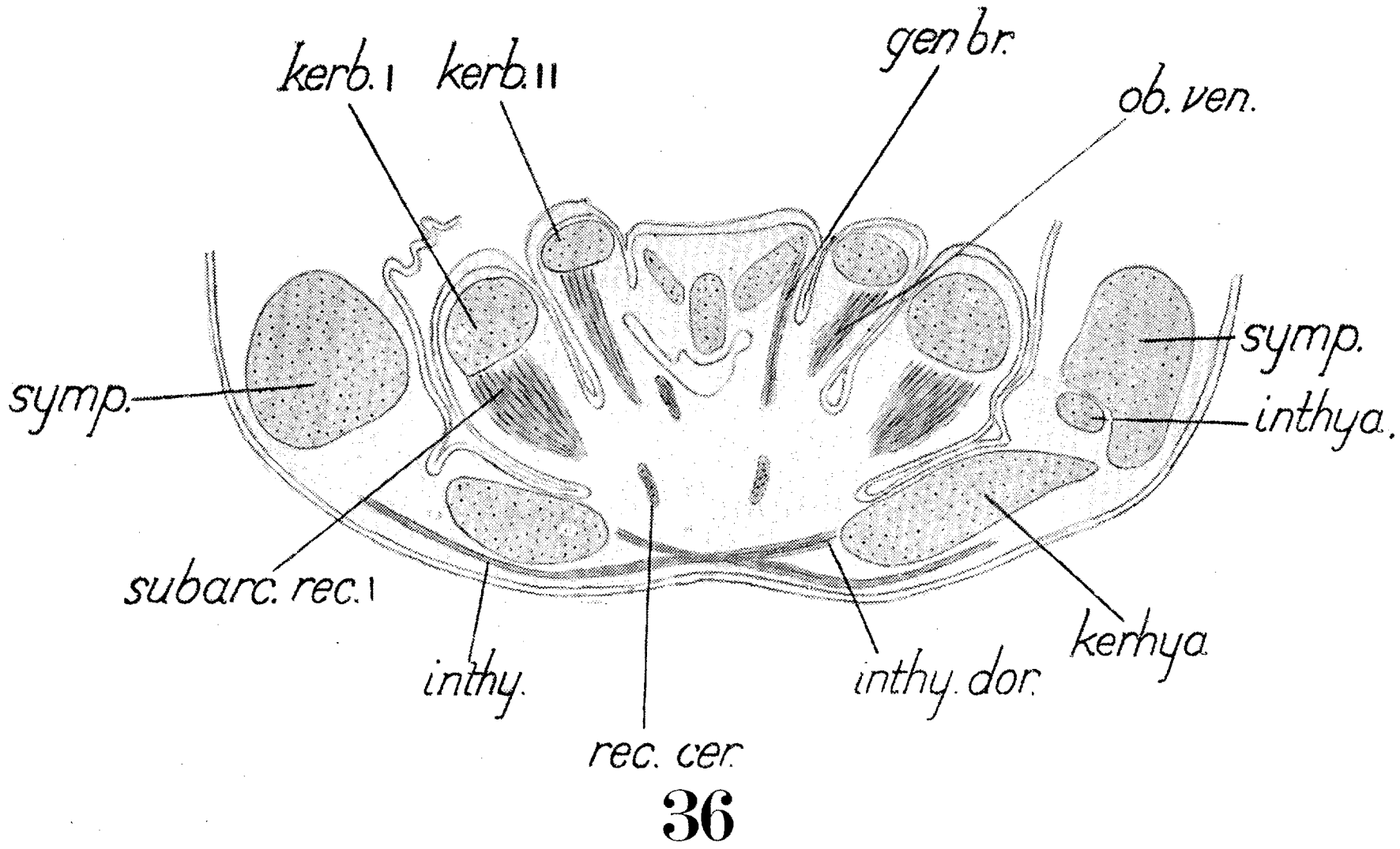

36

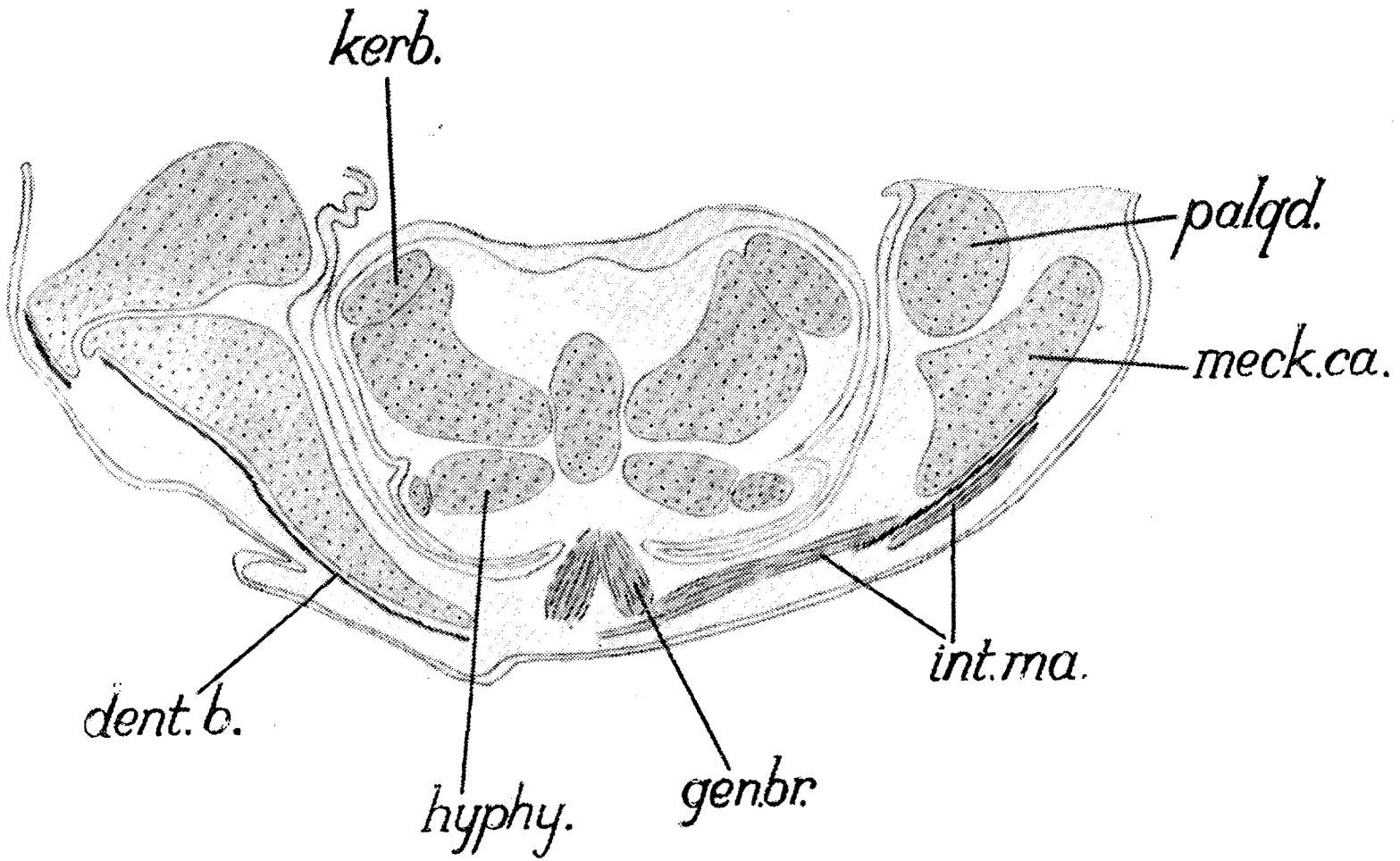

33

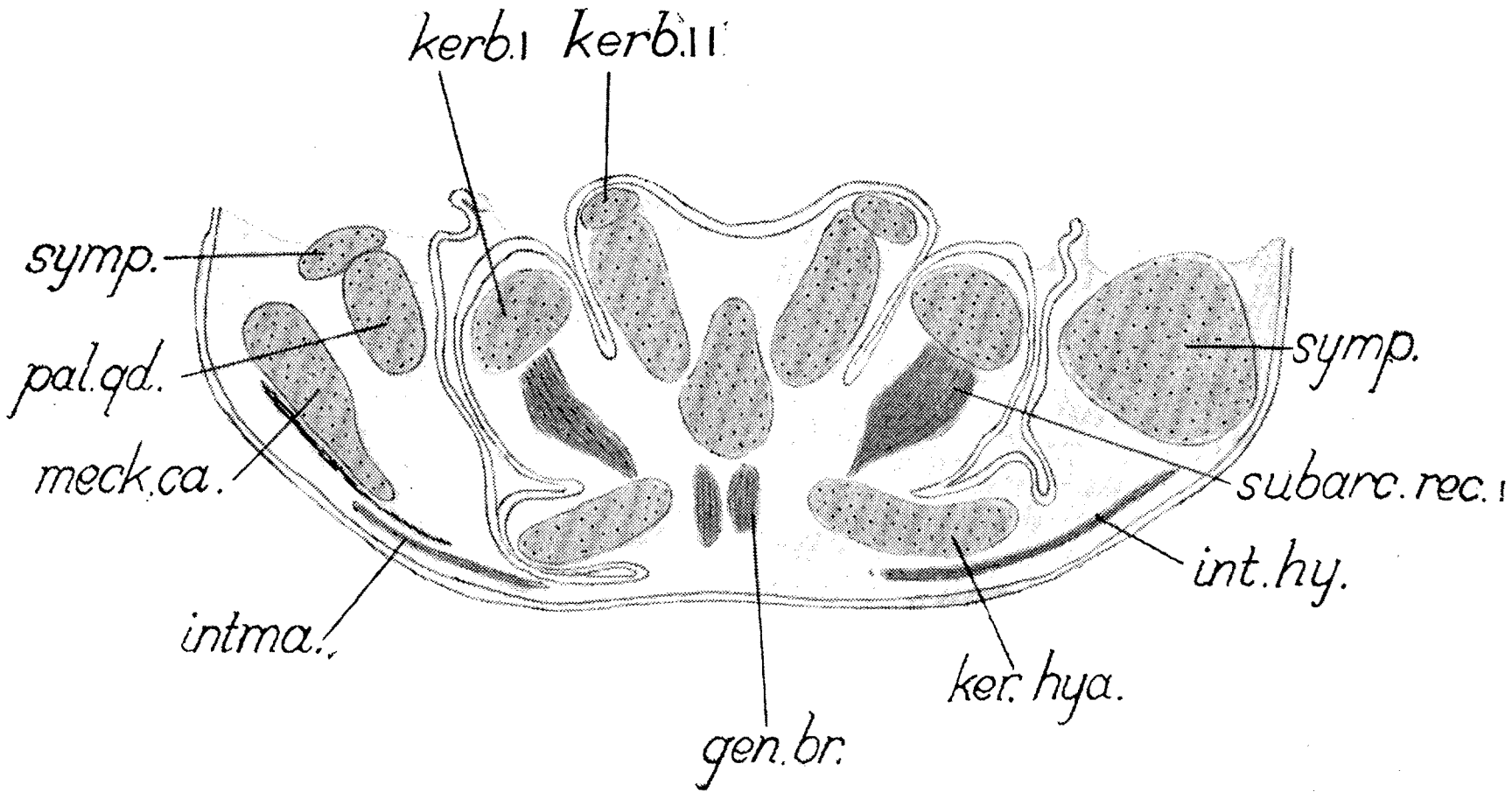

35

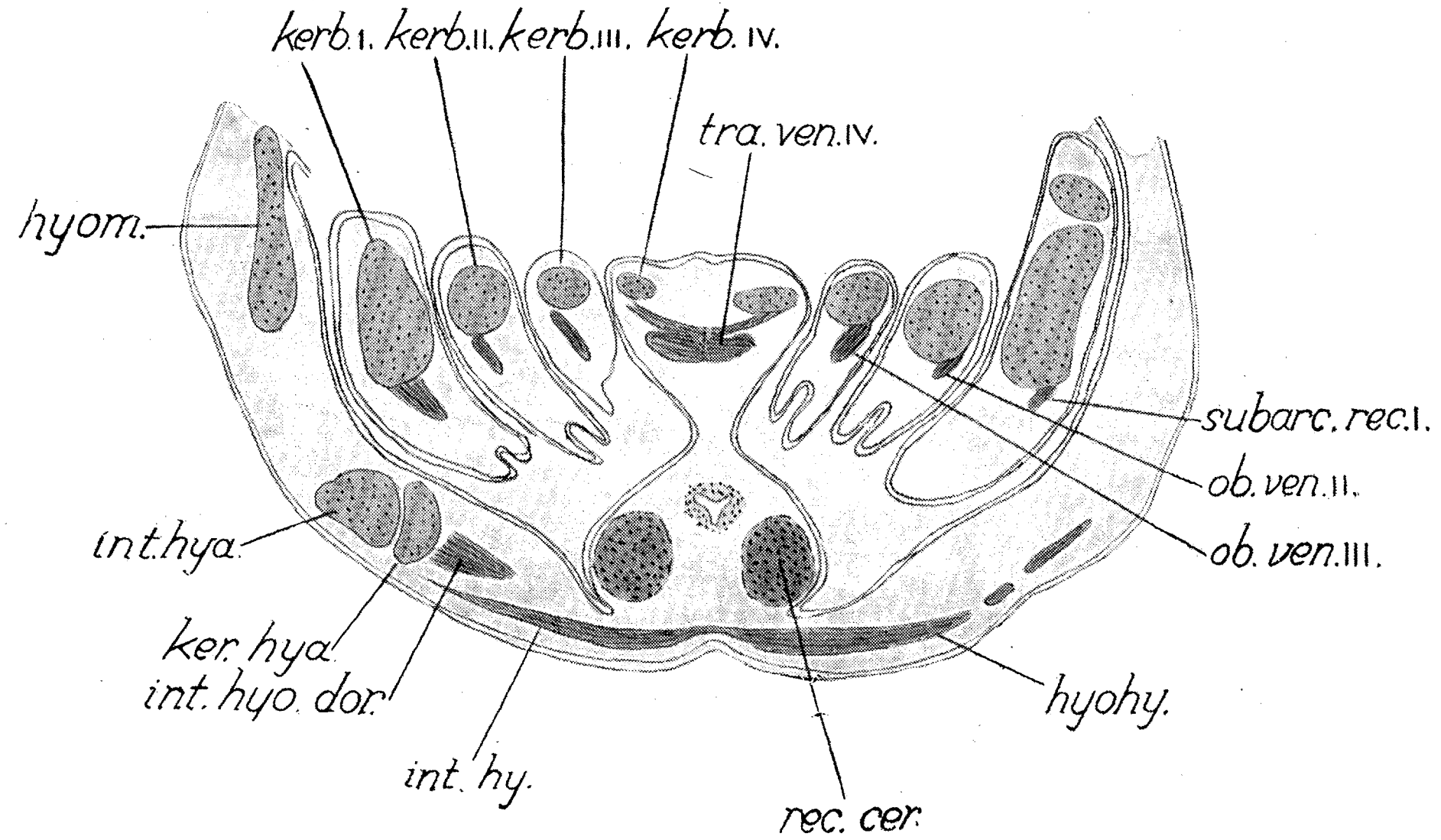
kerb.I.
kerb.II.
kerb.III.
kerb.IV.
tra.ven.IV.
hyom.
subarc.rec.I.
ob.ven.II.
ob.ven.III.
int.hya.
ker.hya.
int.hyo.dor.
hyohy.
int.hy.
rec.cer.

37

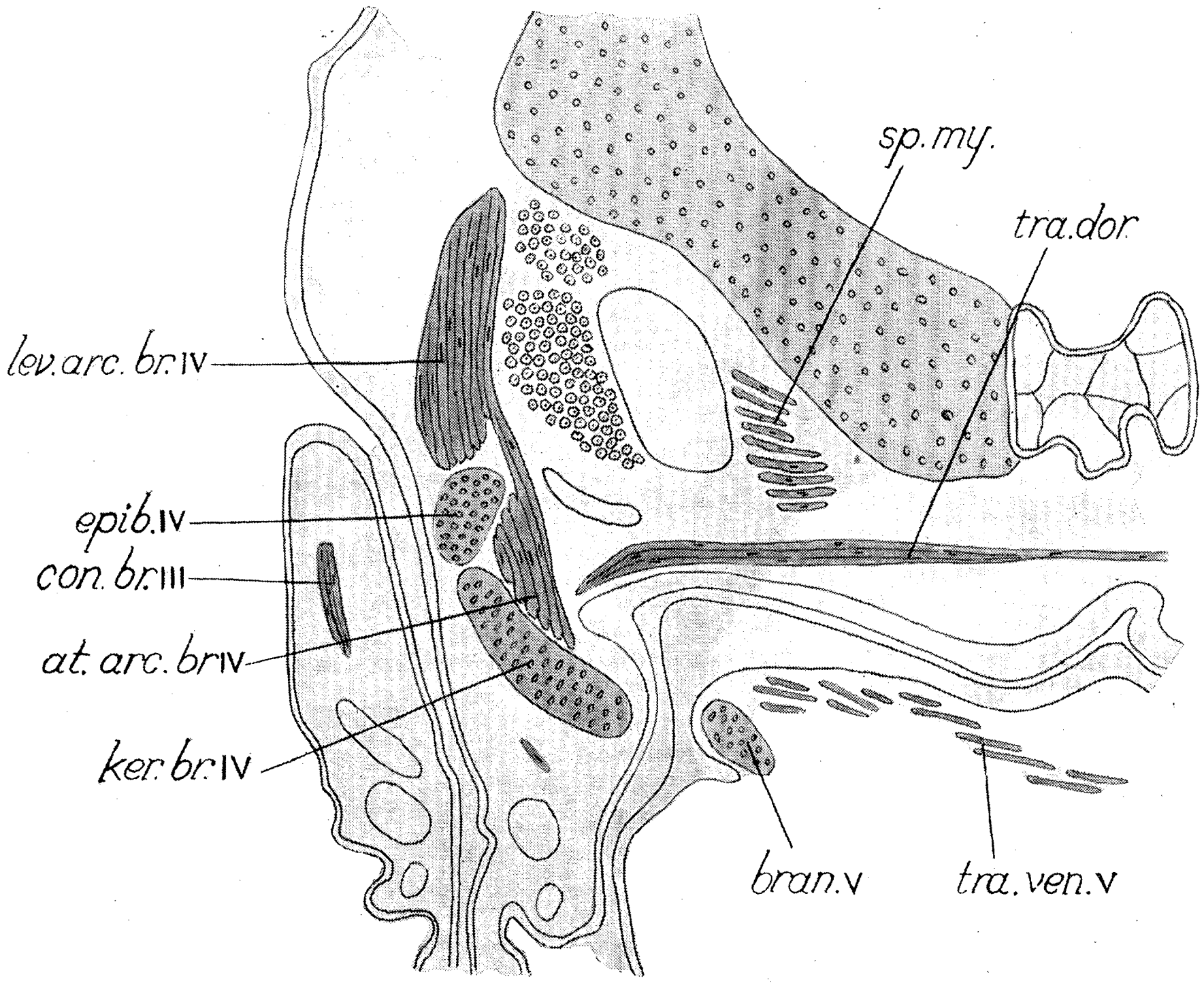
sp.my.
tra.dor.
lev.arc.br.IV
epib.IV
con.br.III
at.arc.br.IV
ker.br.IV
bran.V
tra.ven.V

38

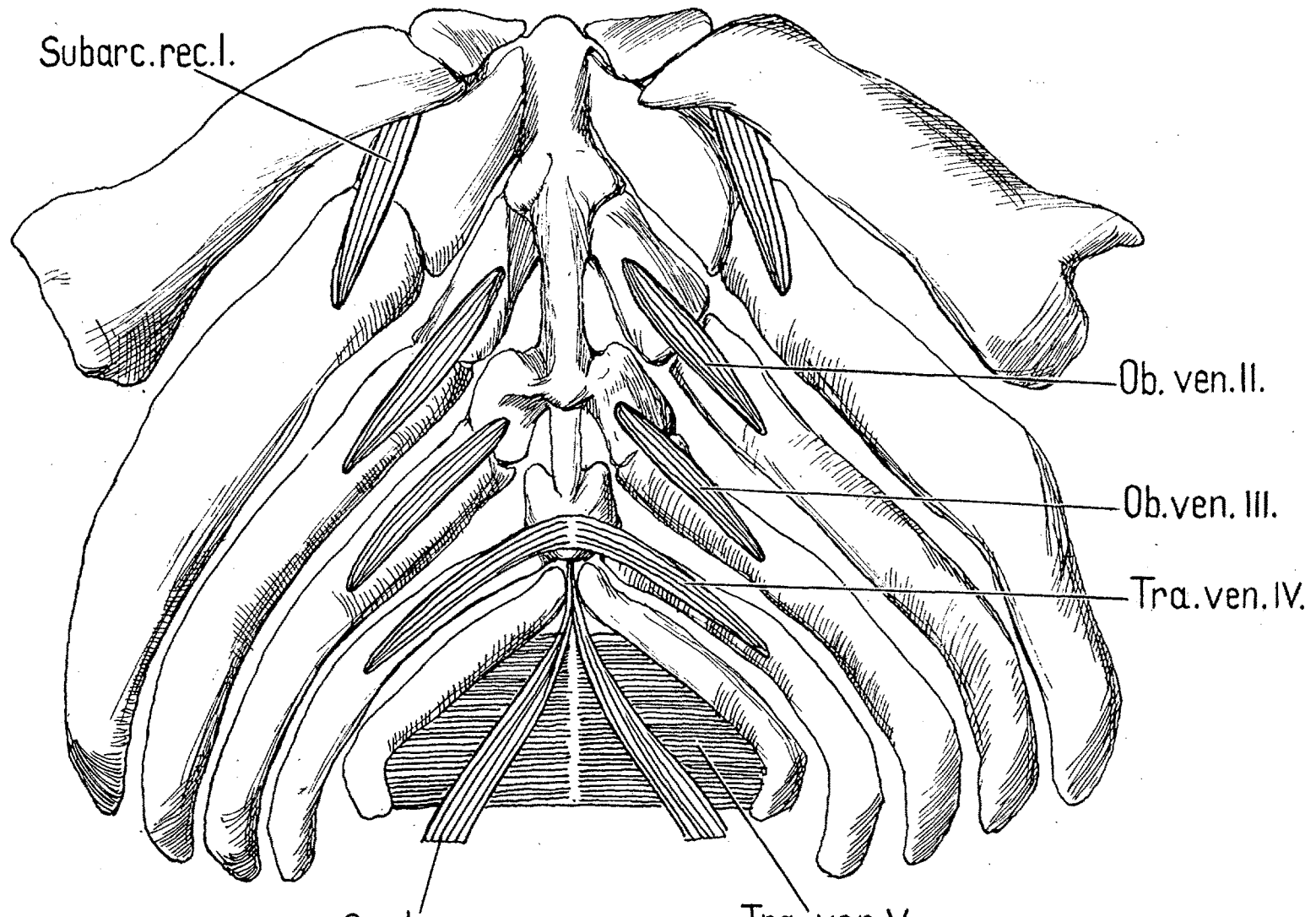
Subarc.rec.I.
Ob.ven.II.
Ob.ven.III.
Tra.ven.IV.
Co.bran.V.
Tra.ven.V.

39

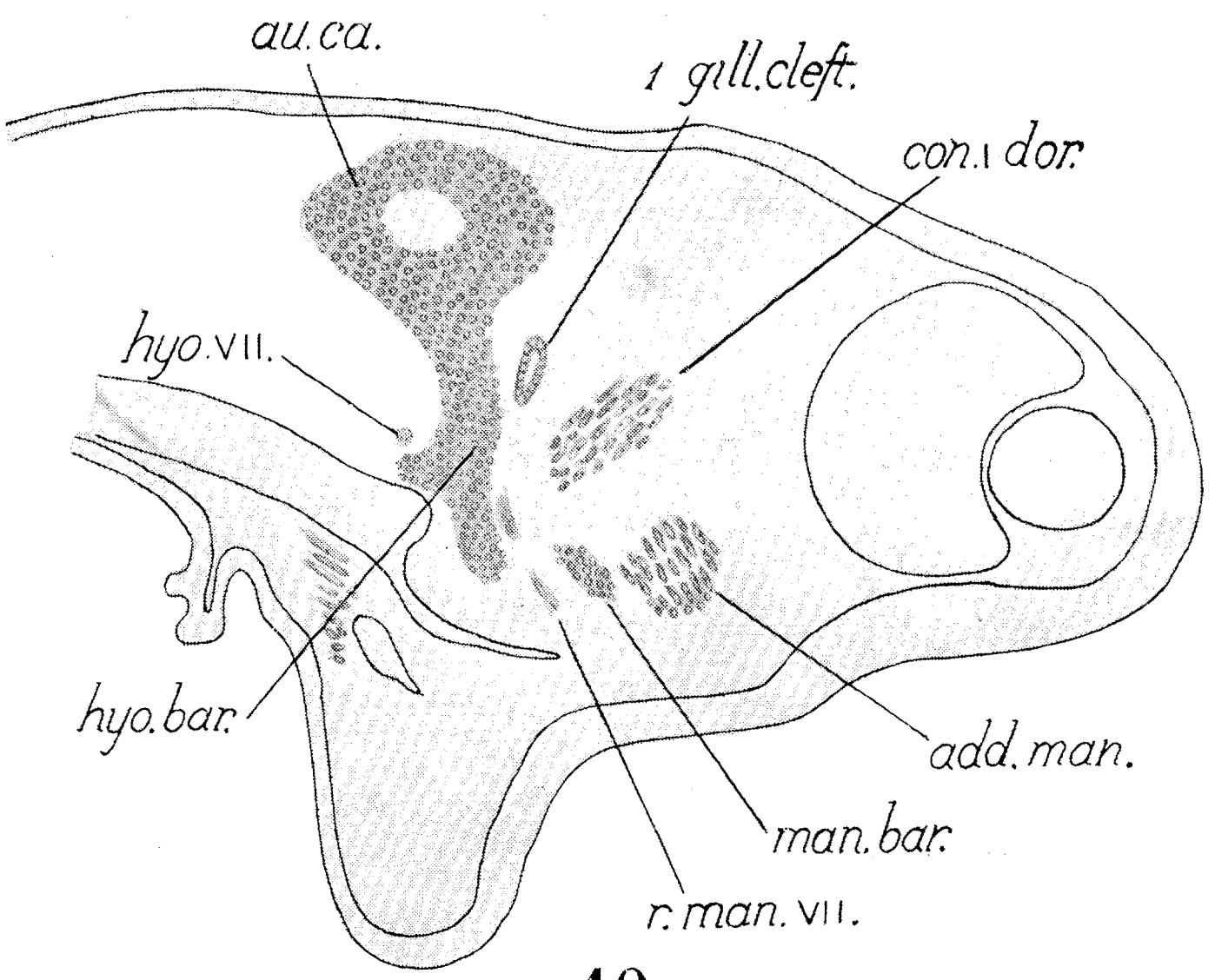

40

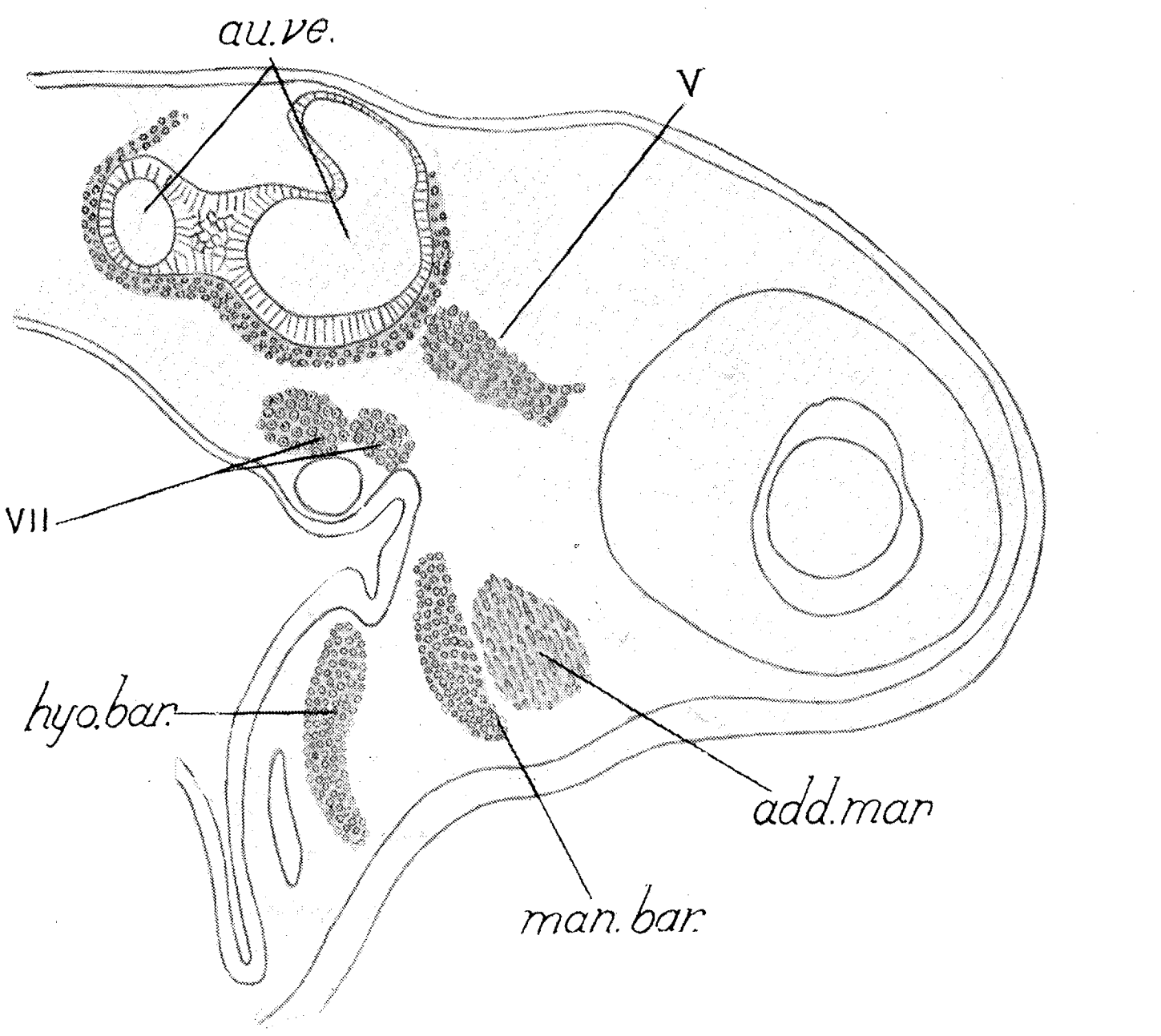

41

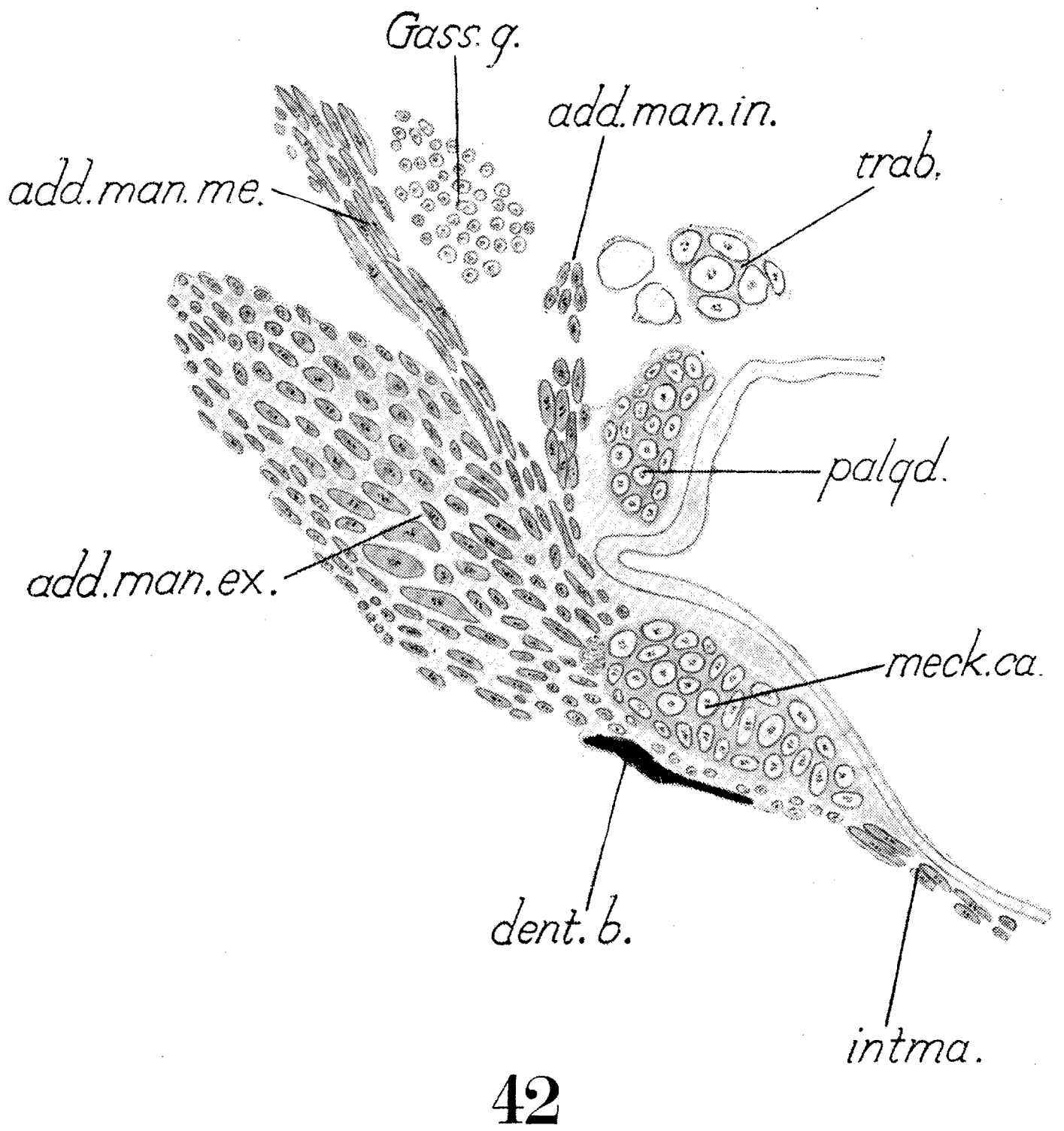

42

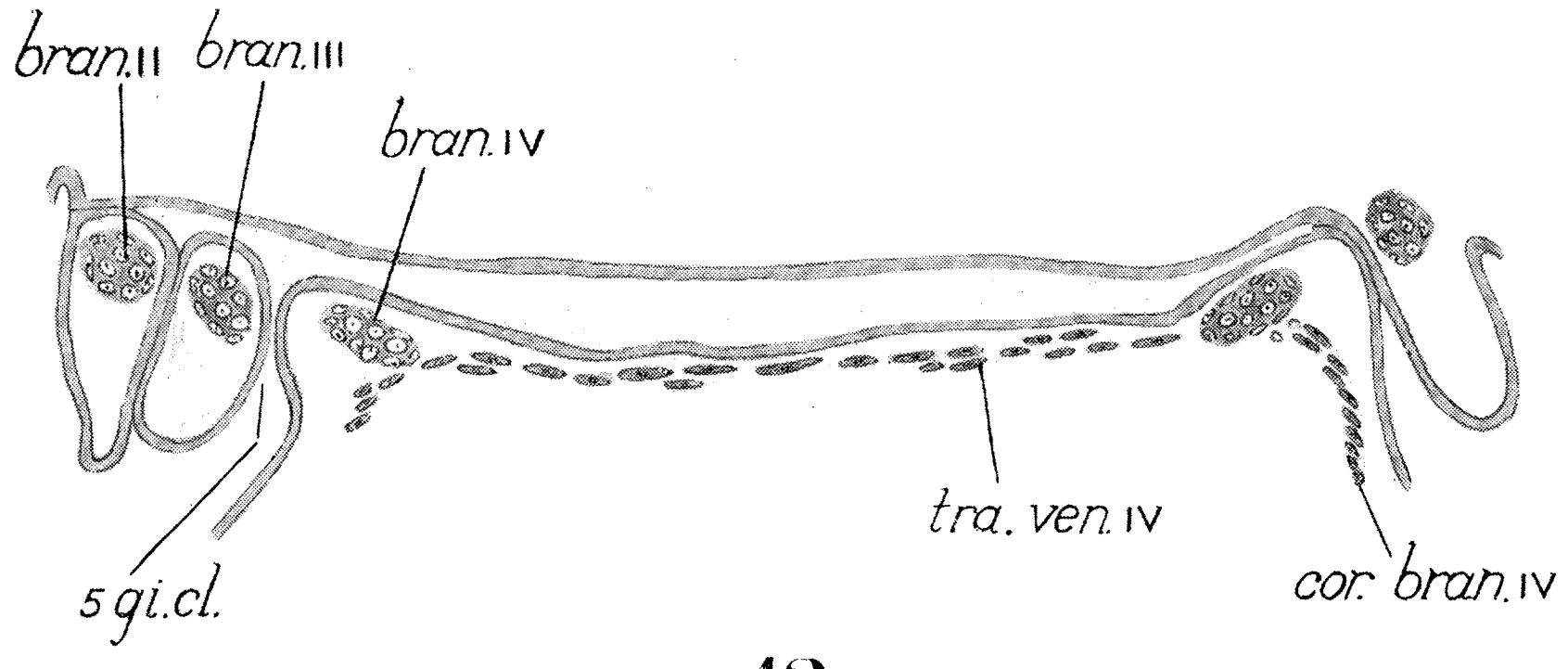

43

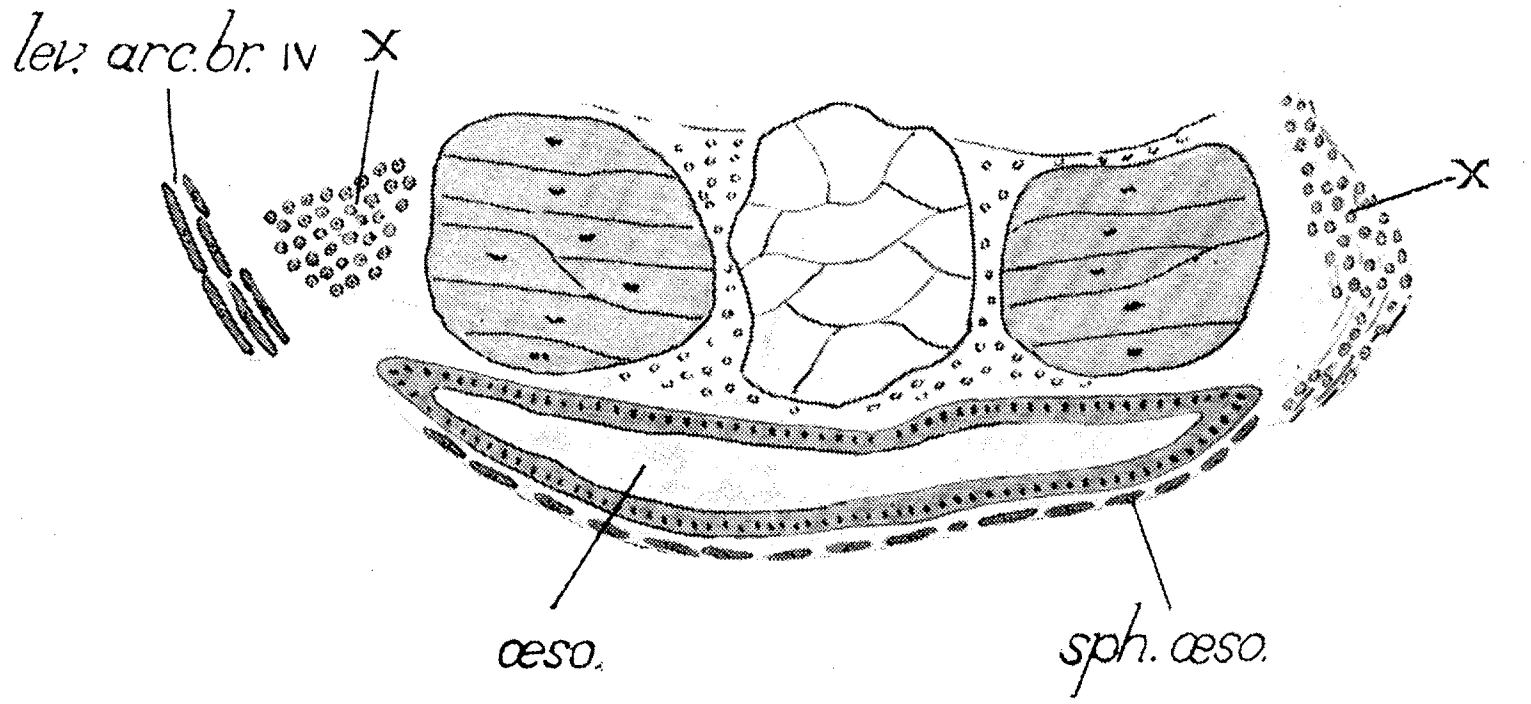

44

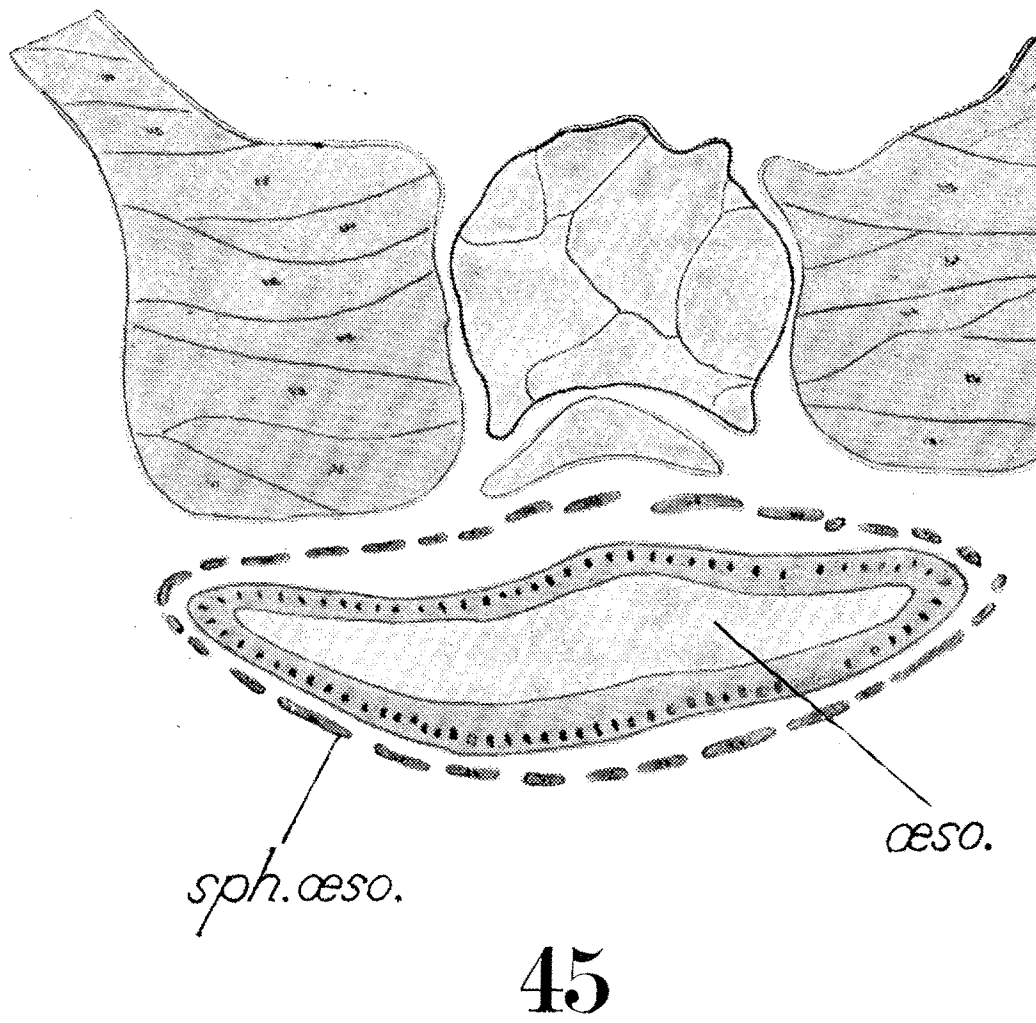

45

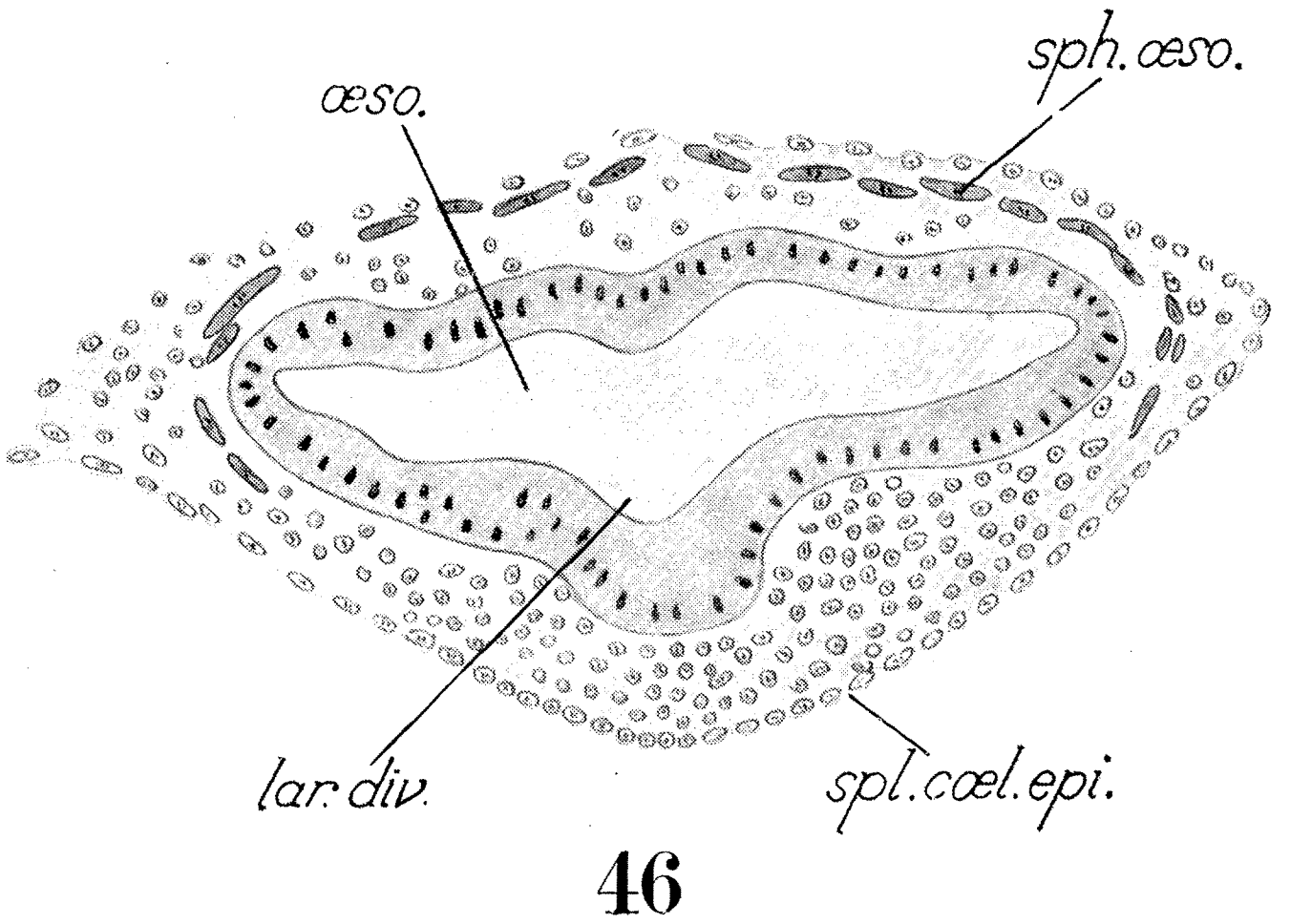

46

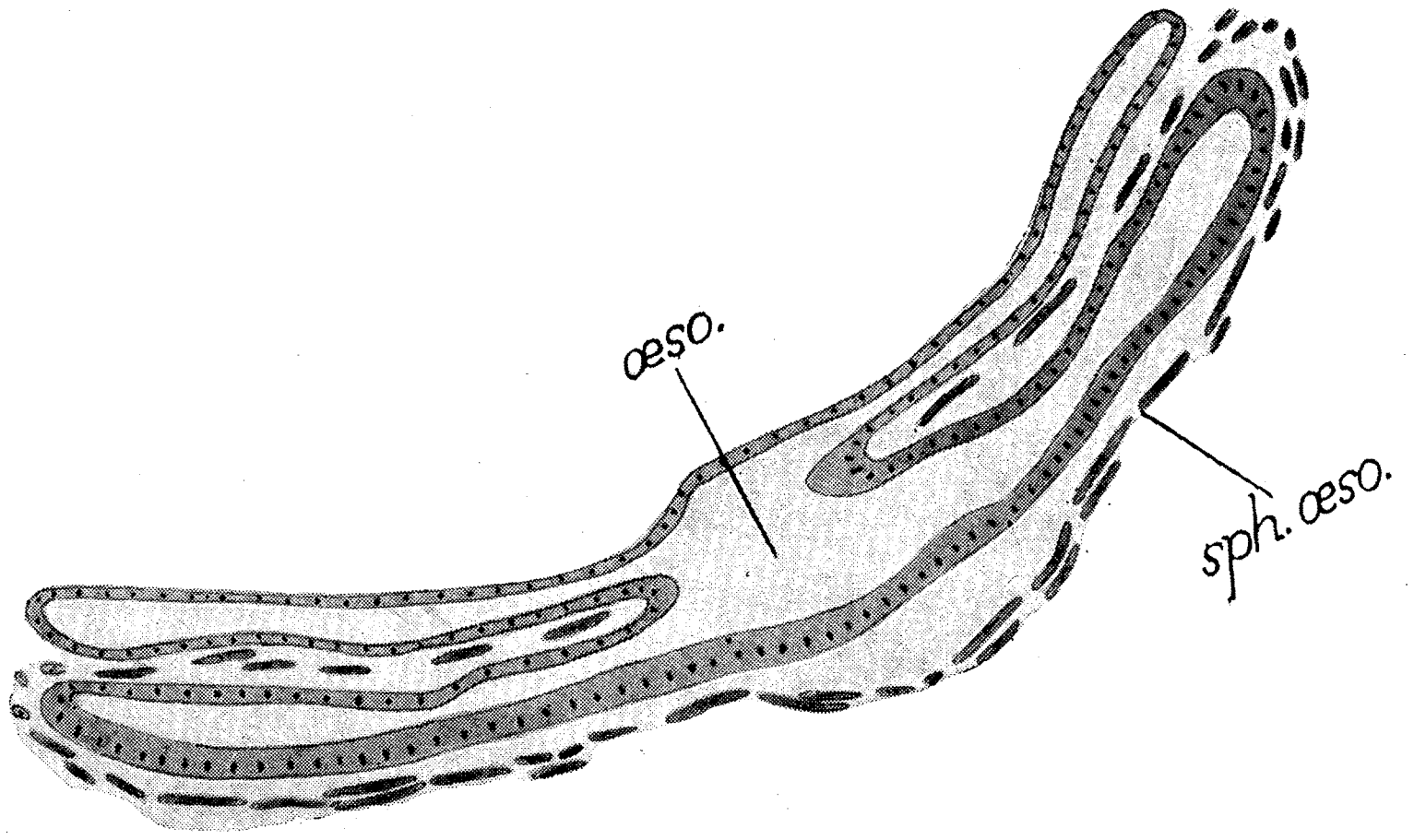

47

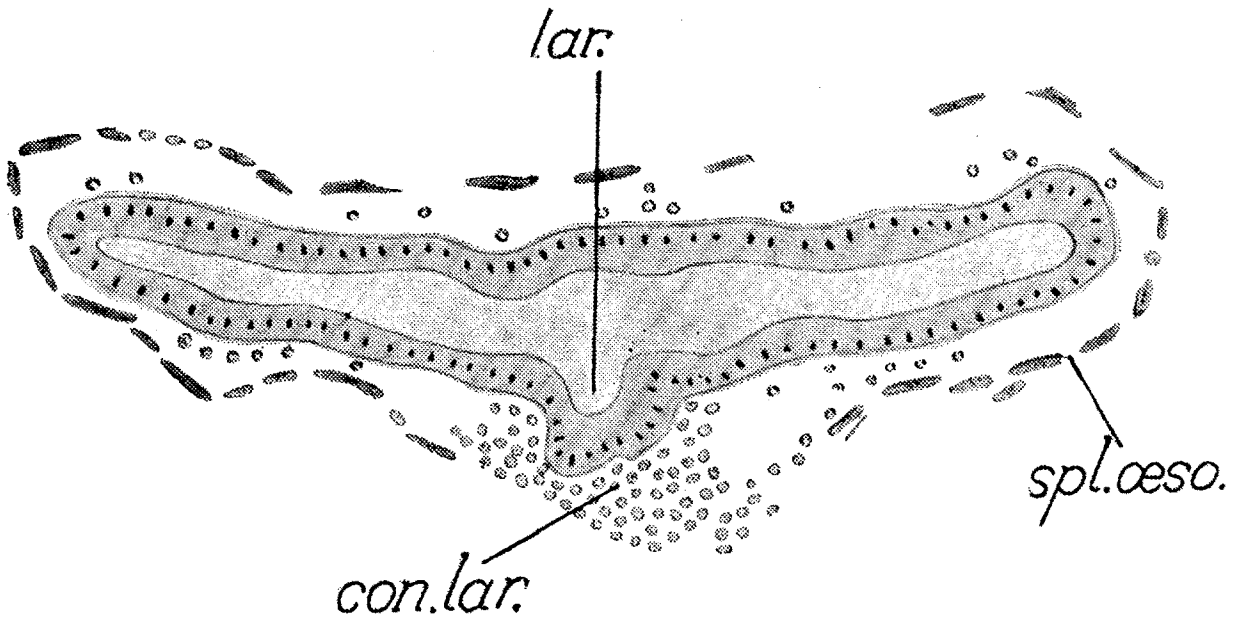

48

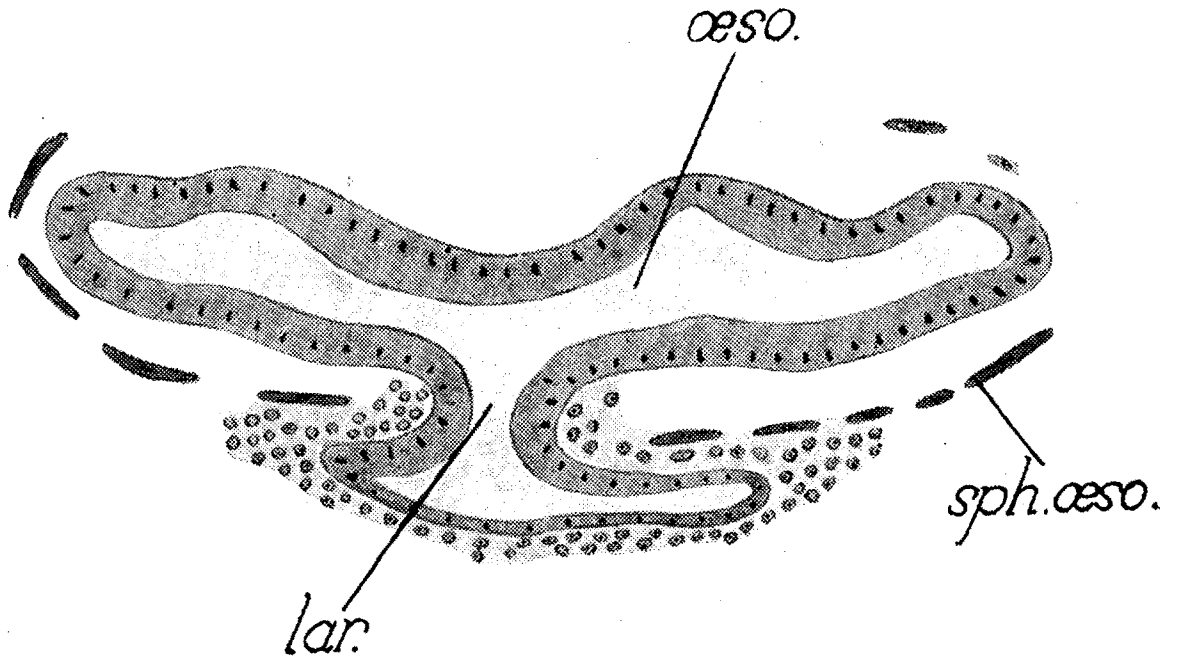

49

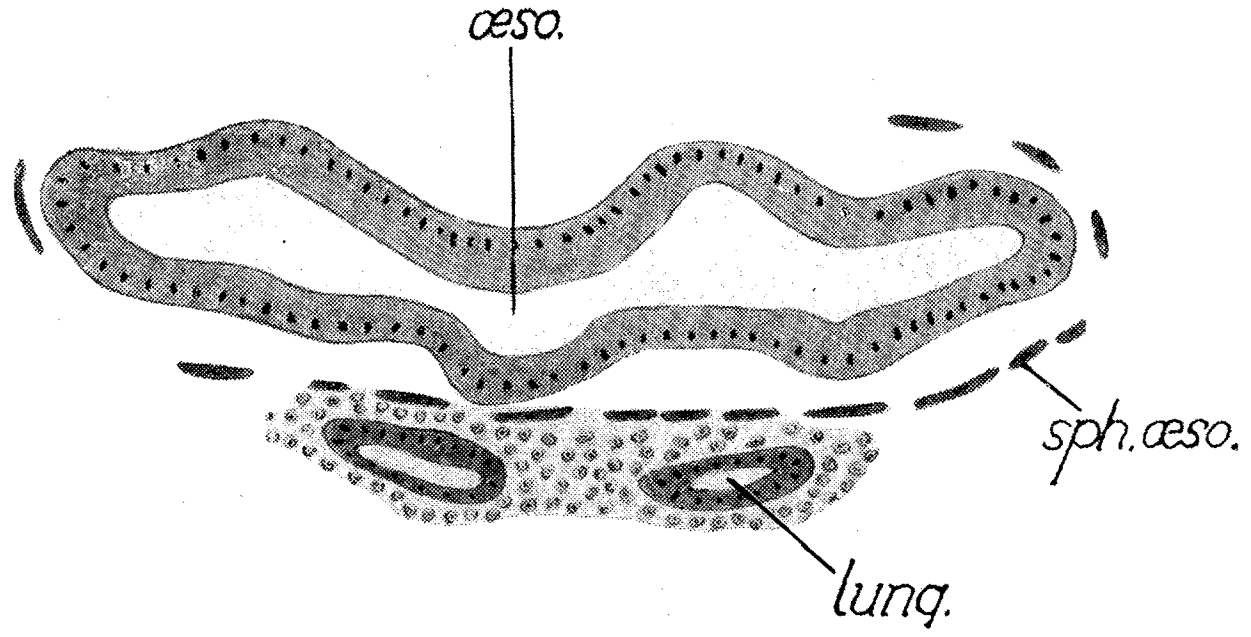

50

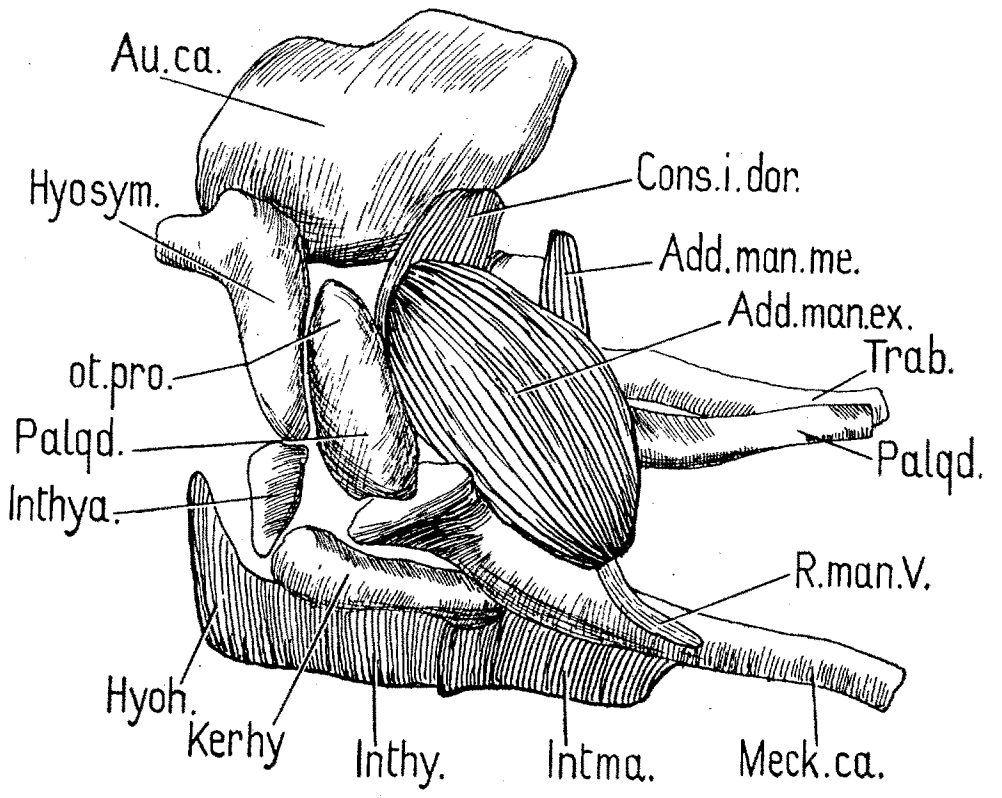

51

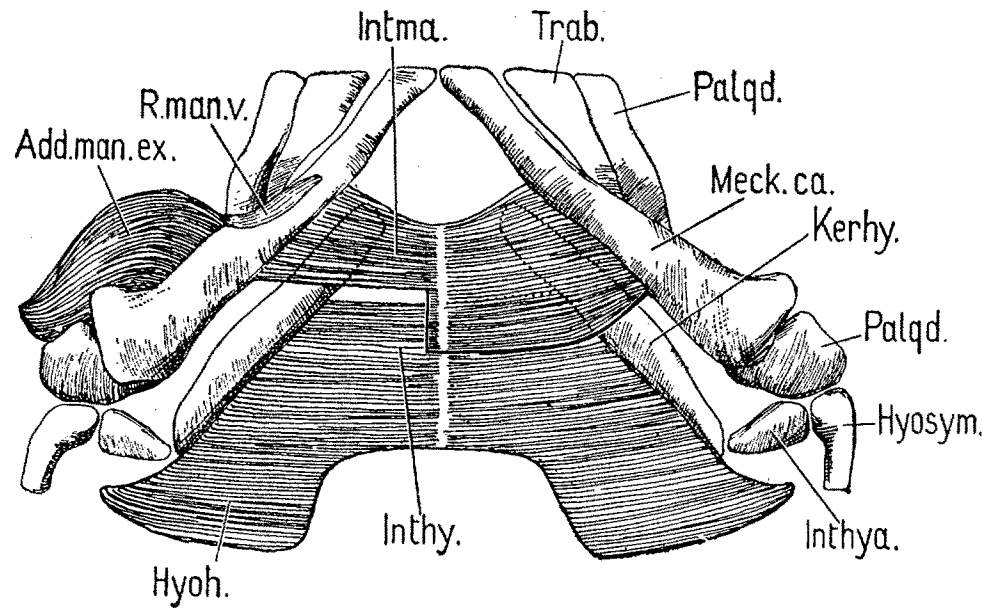

52

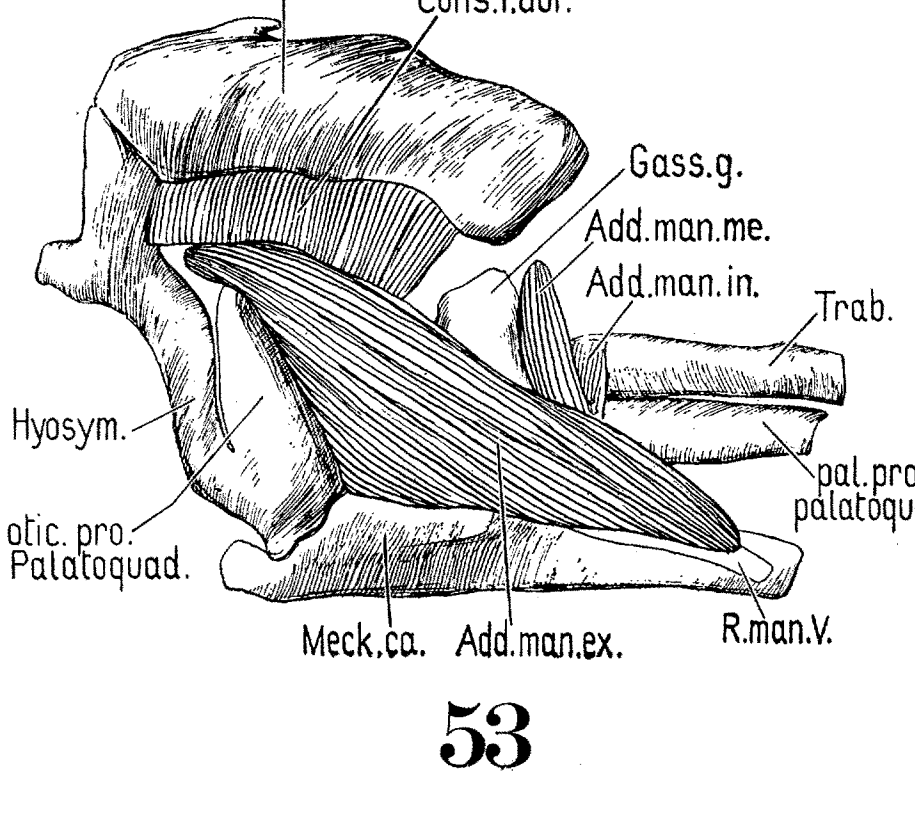

53

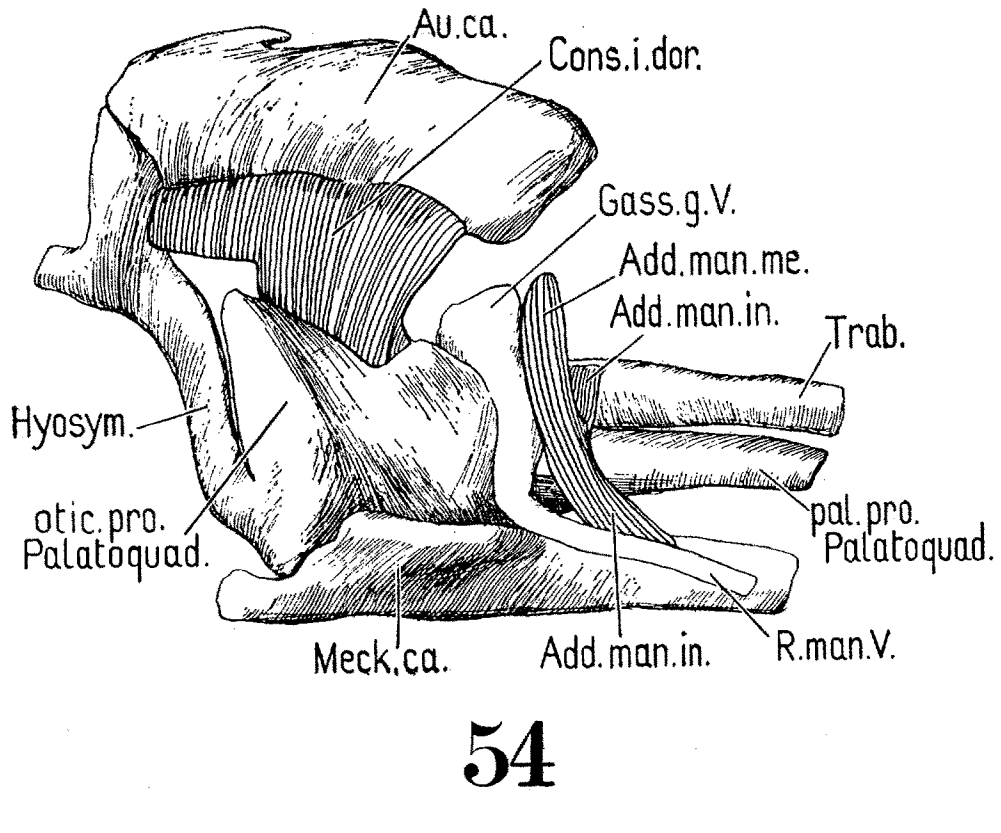

54

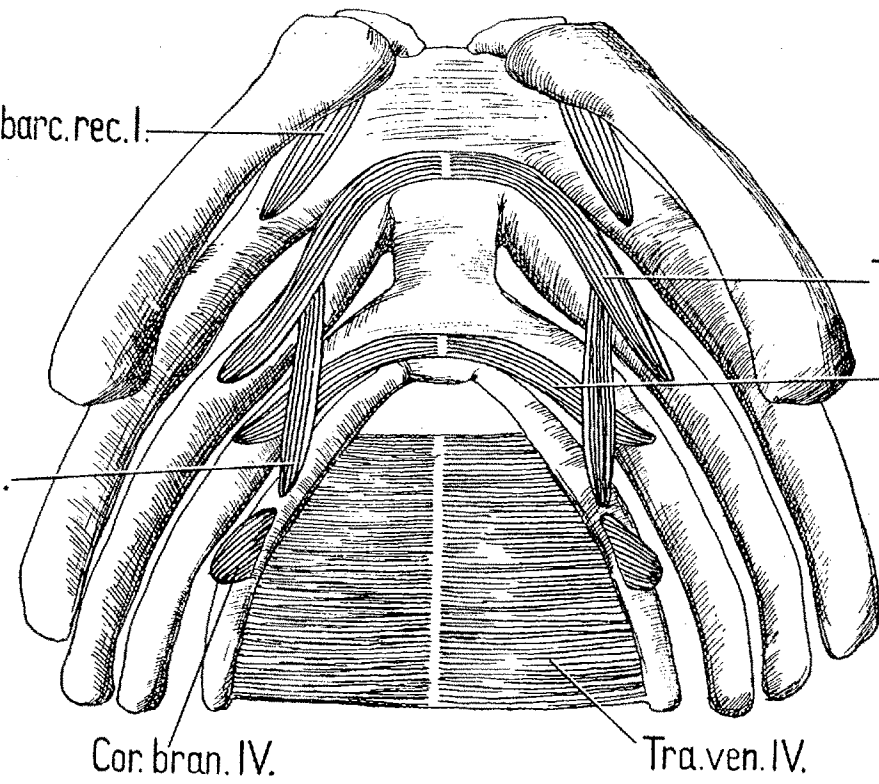

55

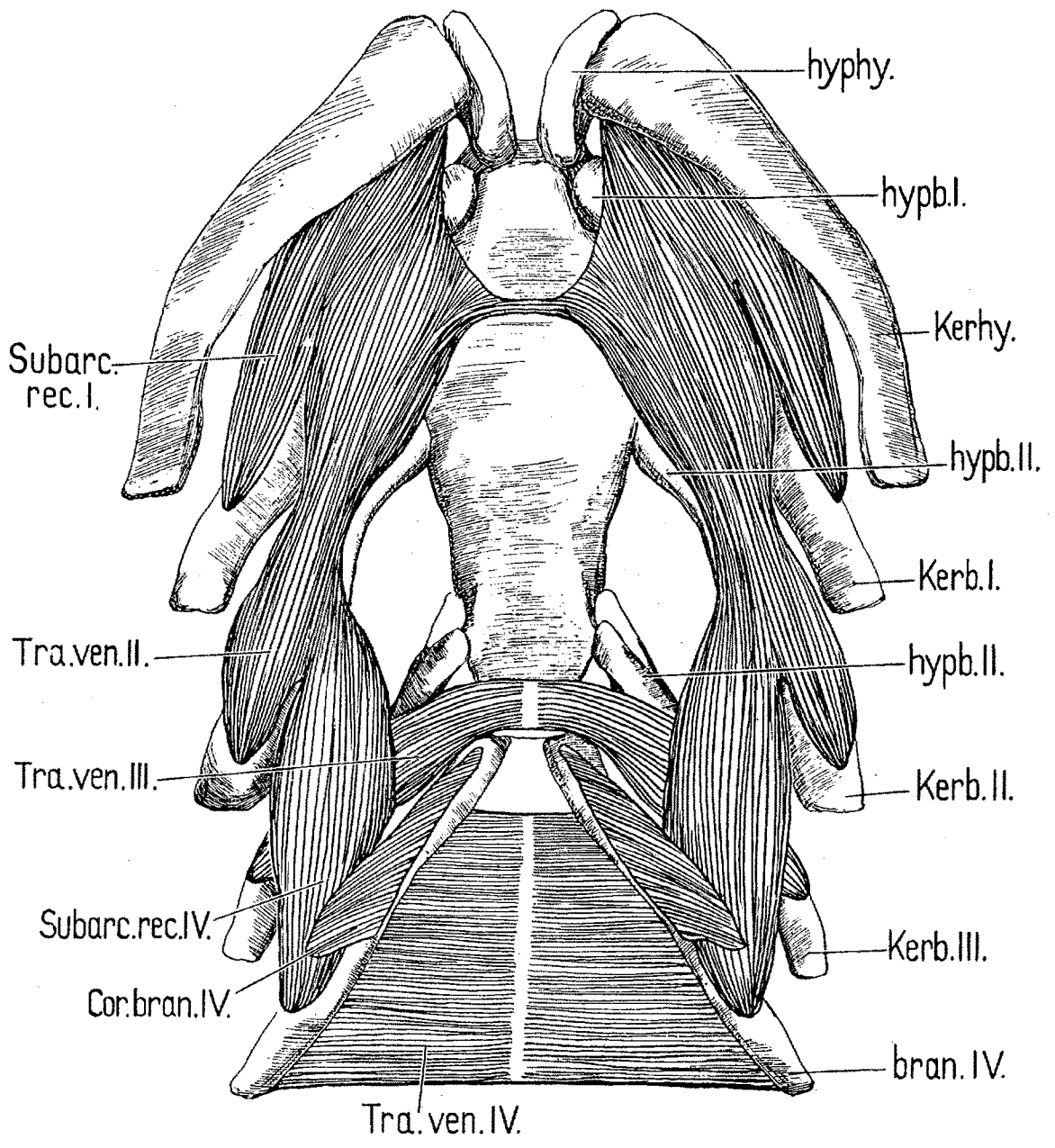

56

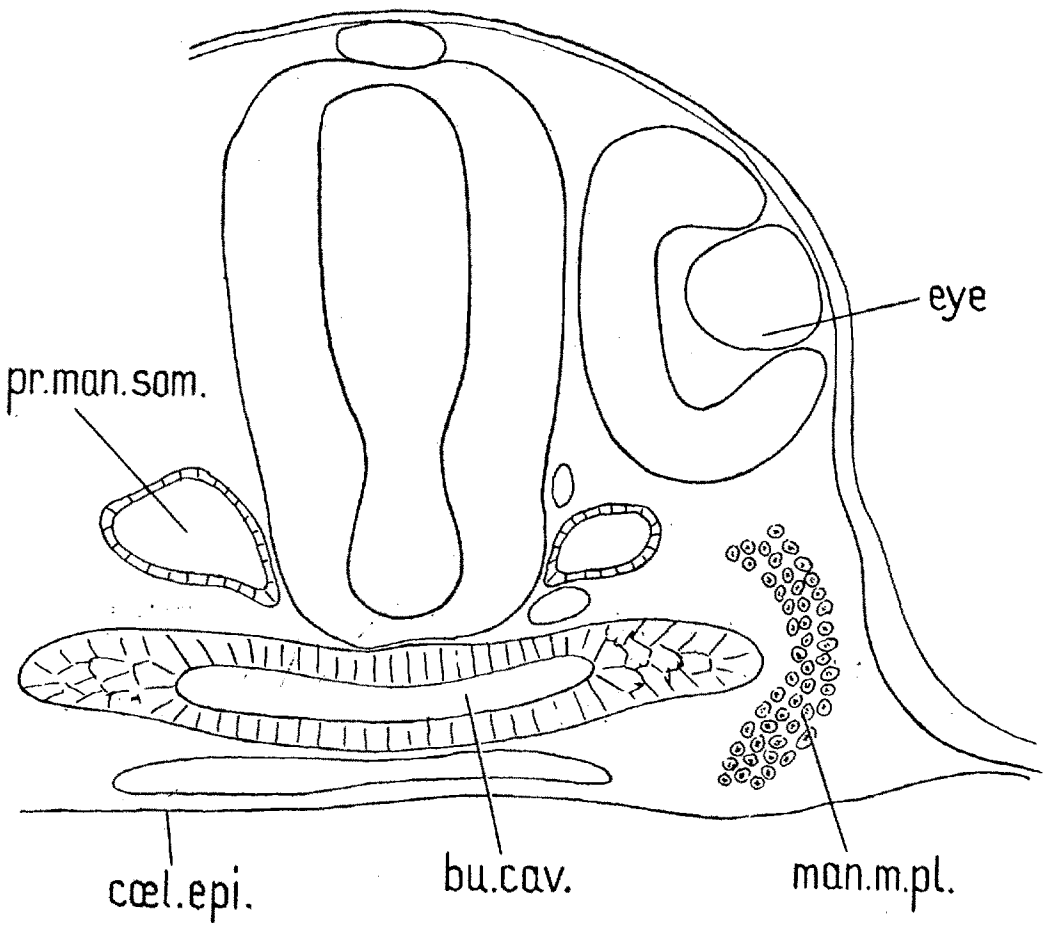

57

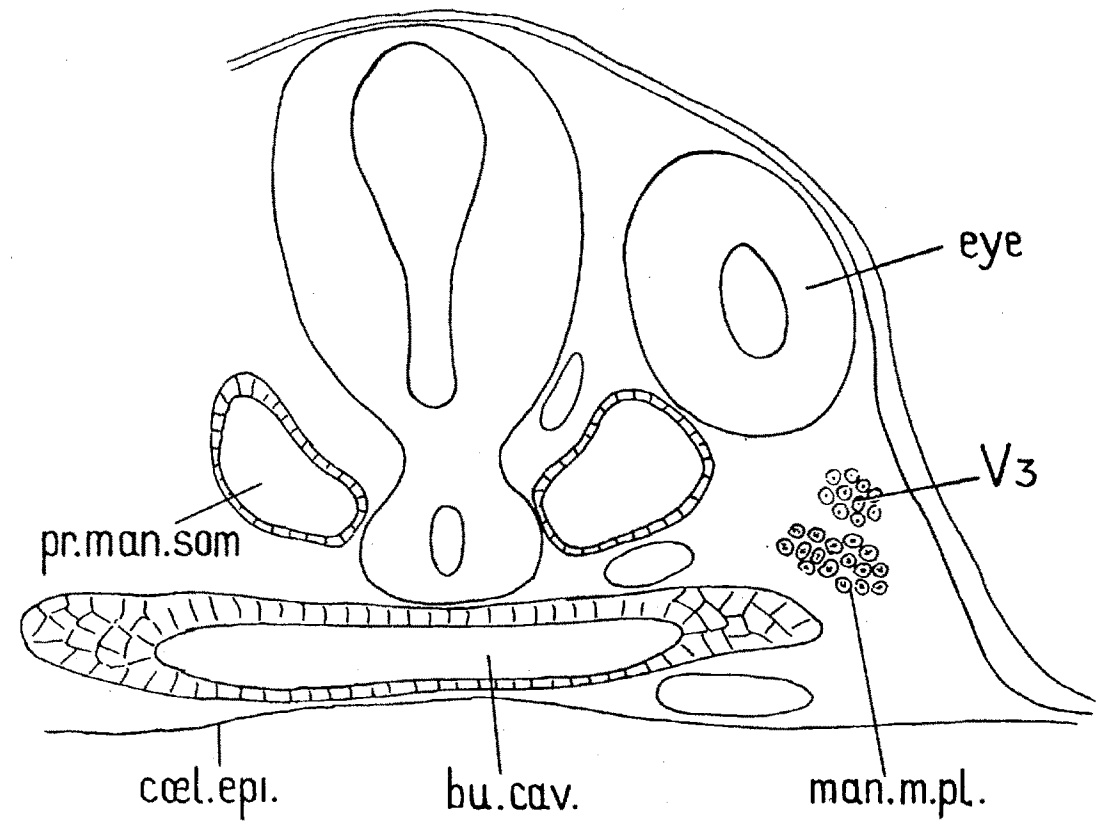

58

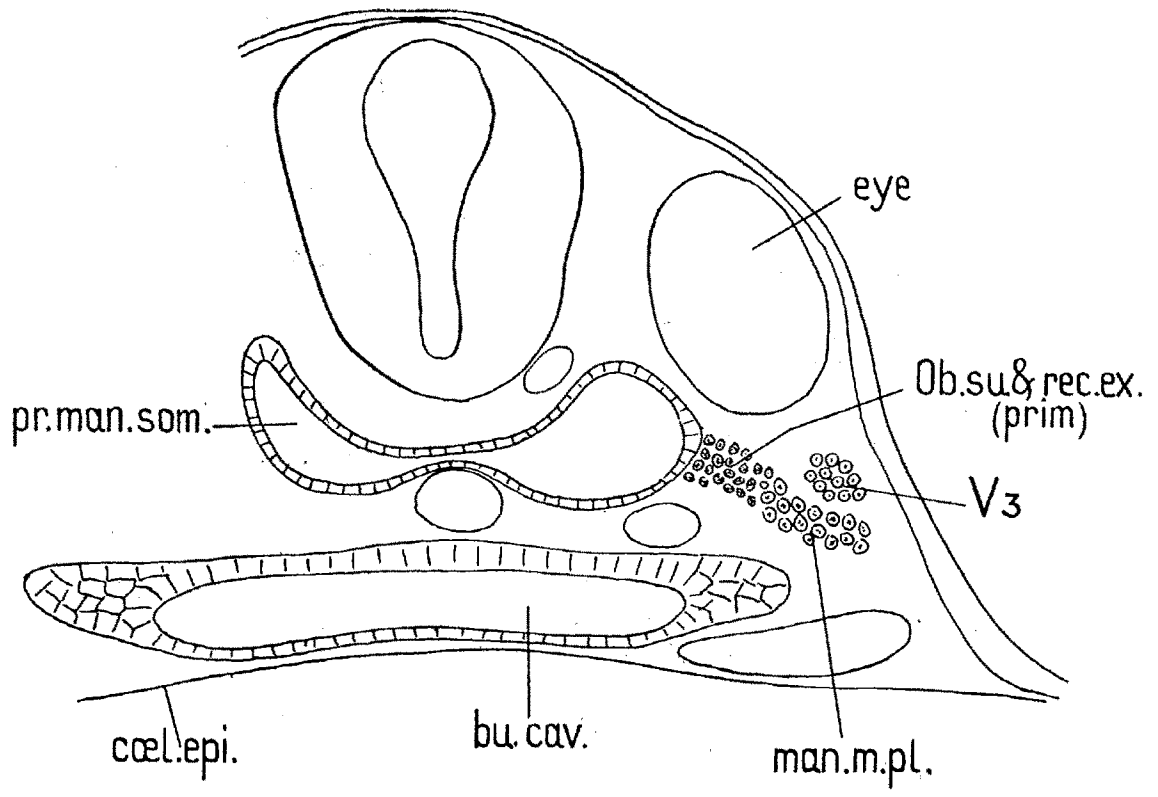

59

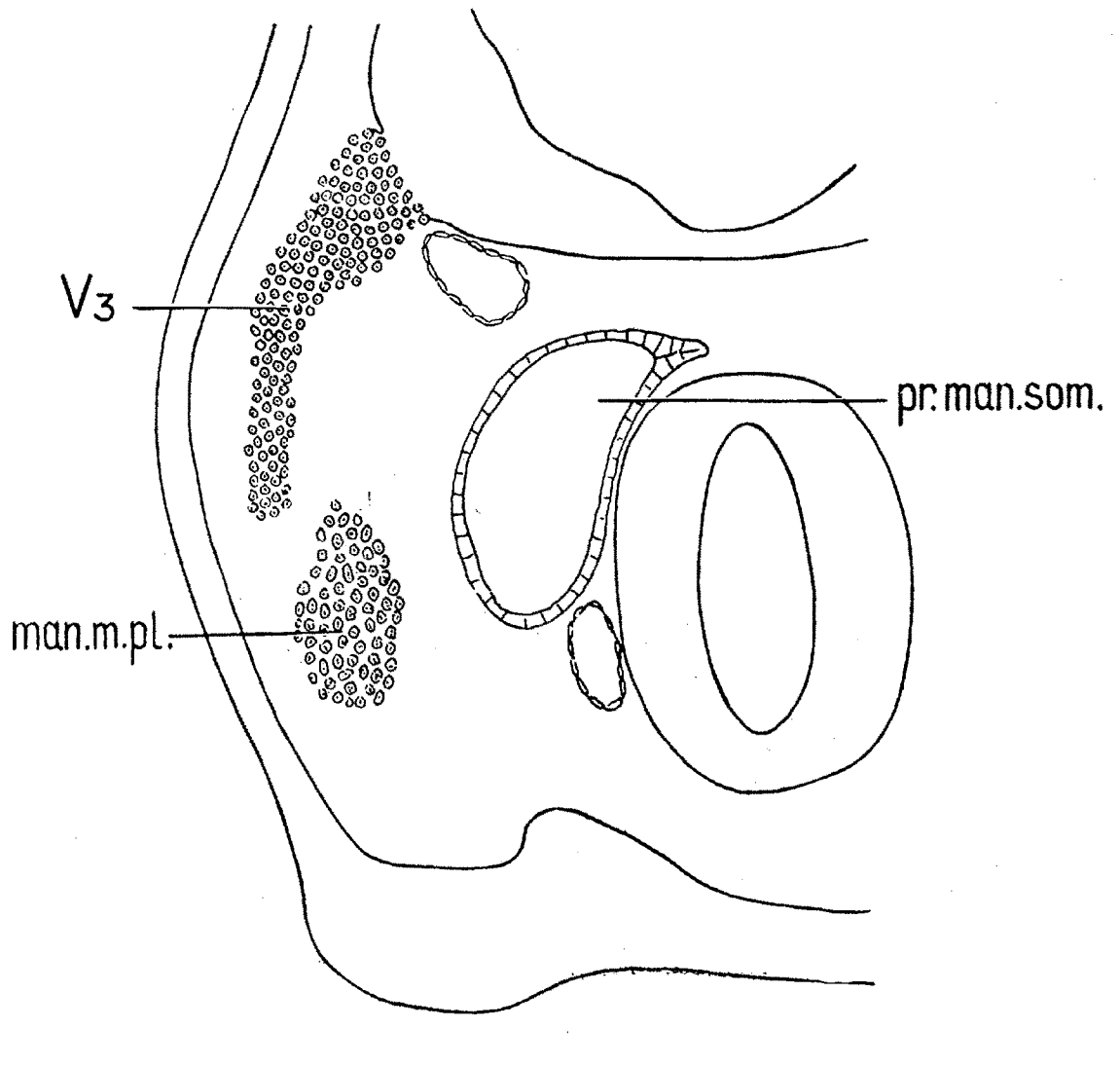

60

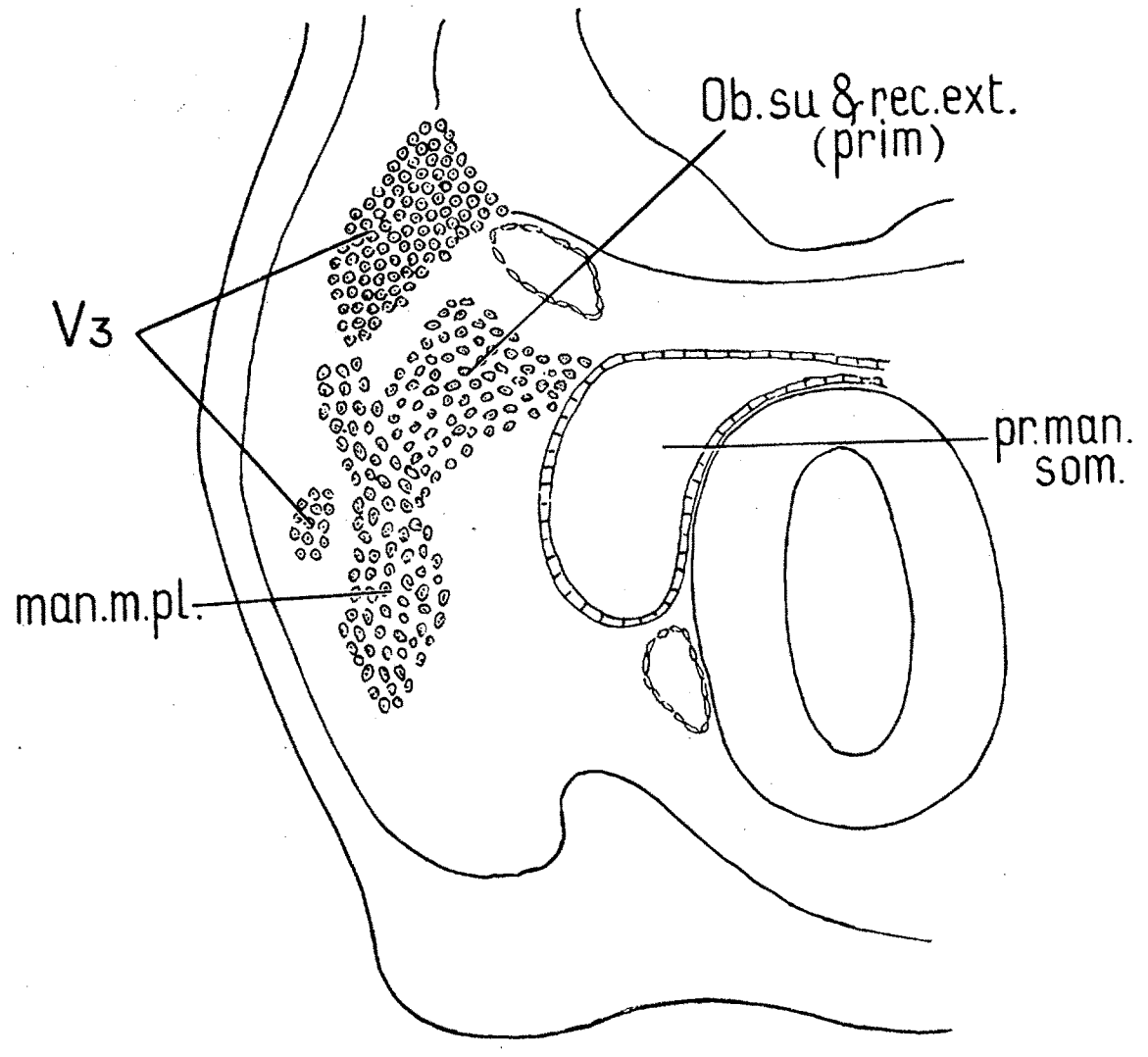

61

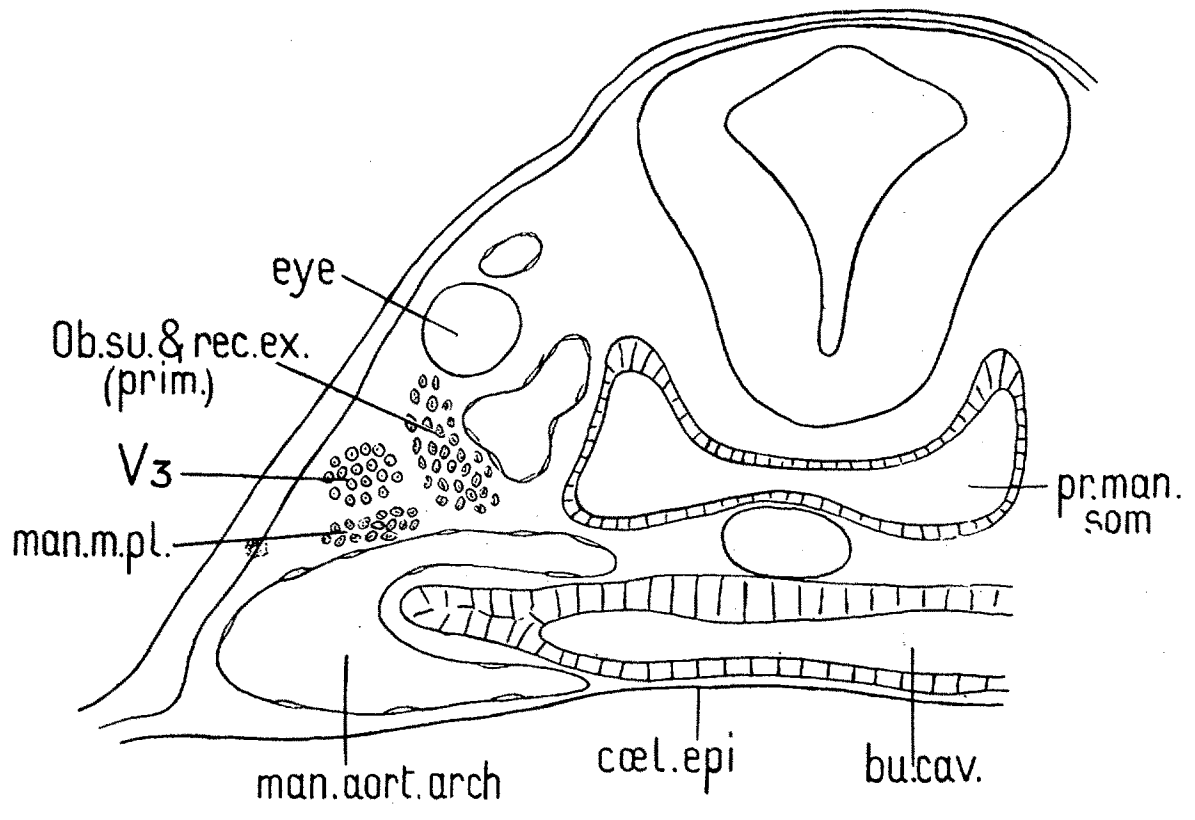

62

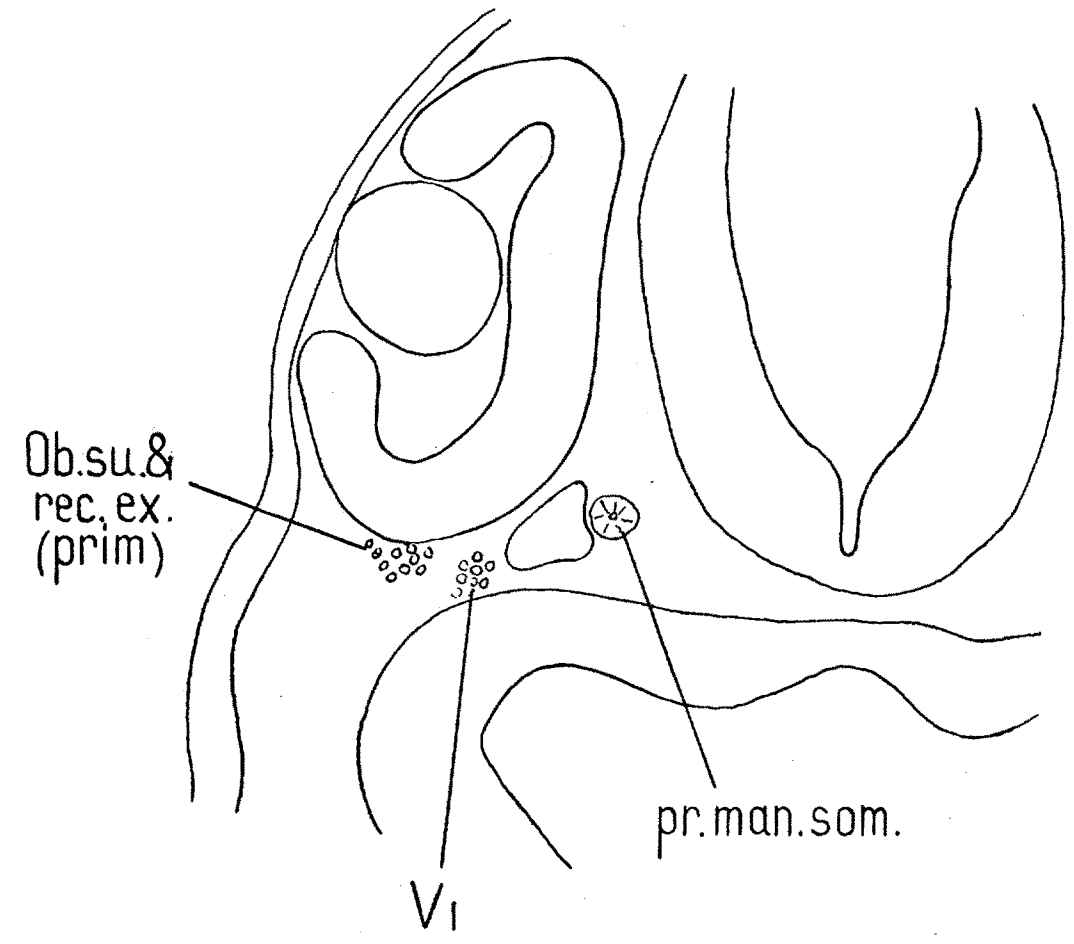

63

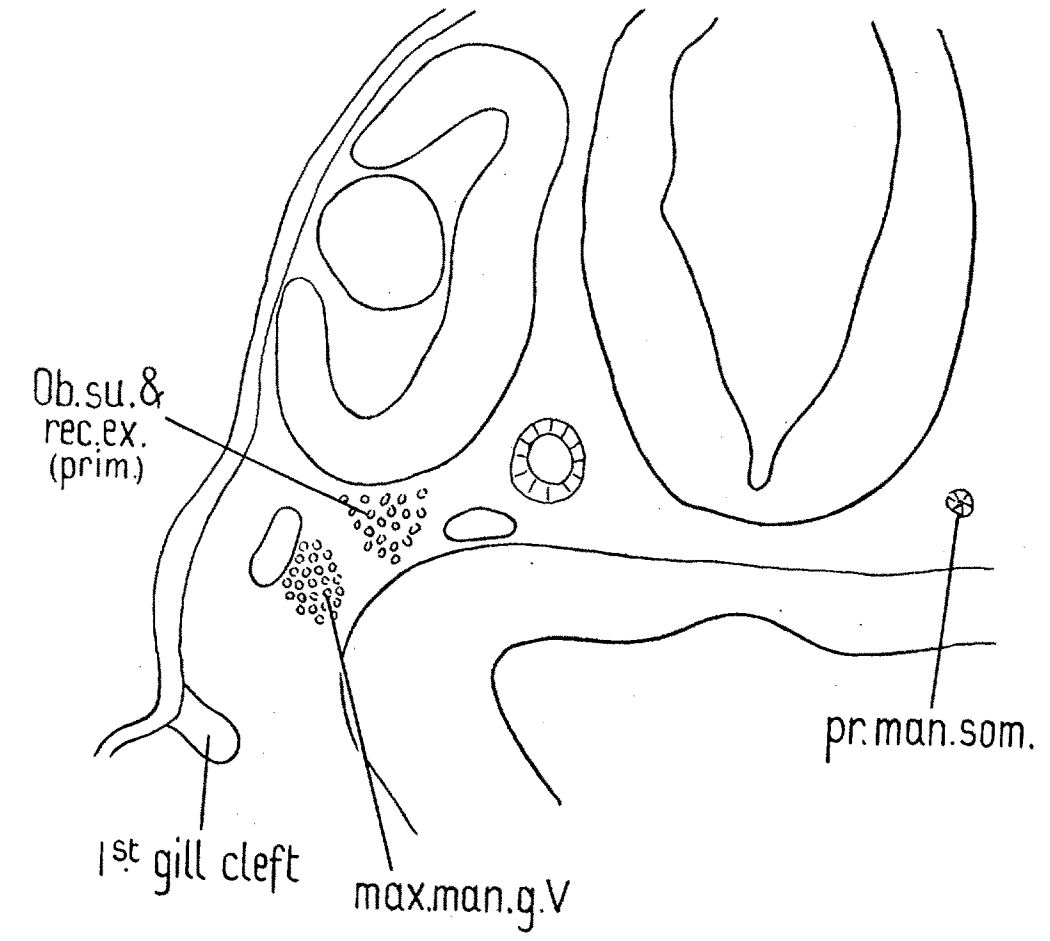

64

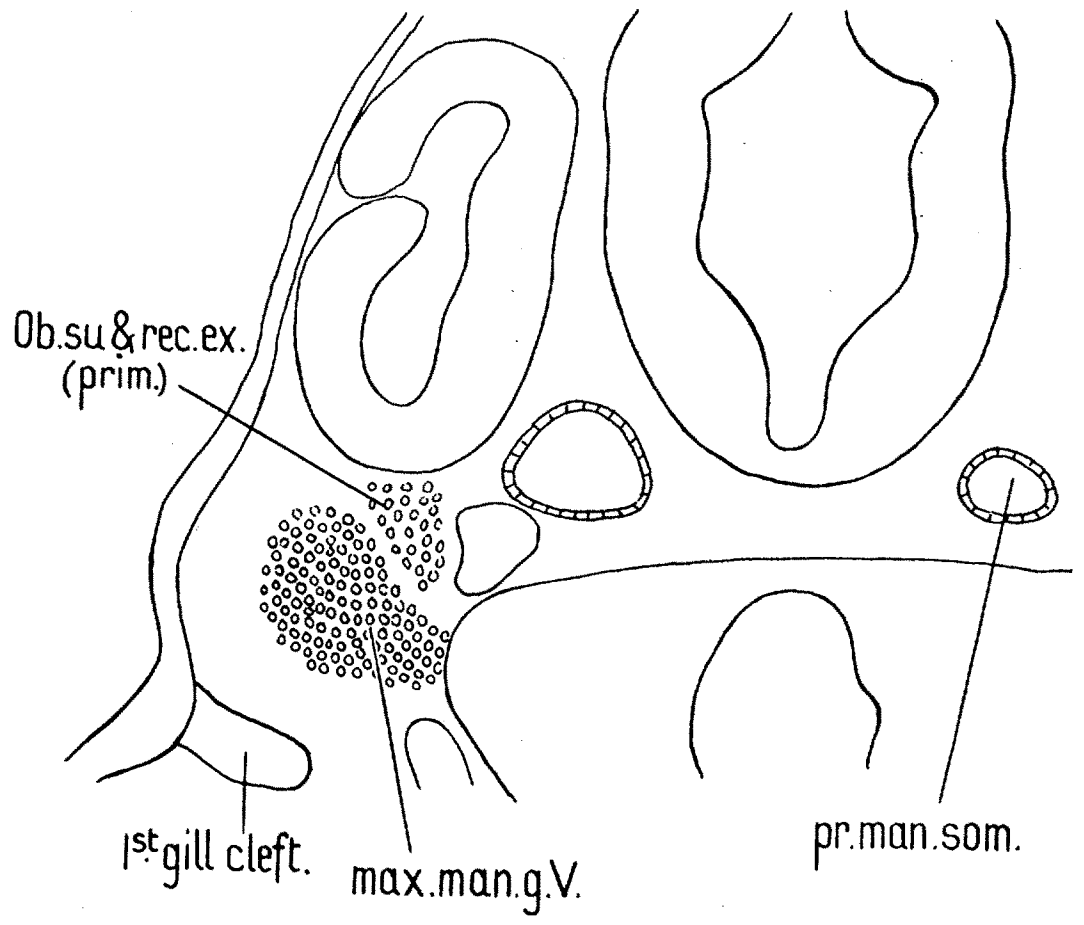

65

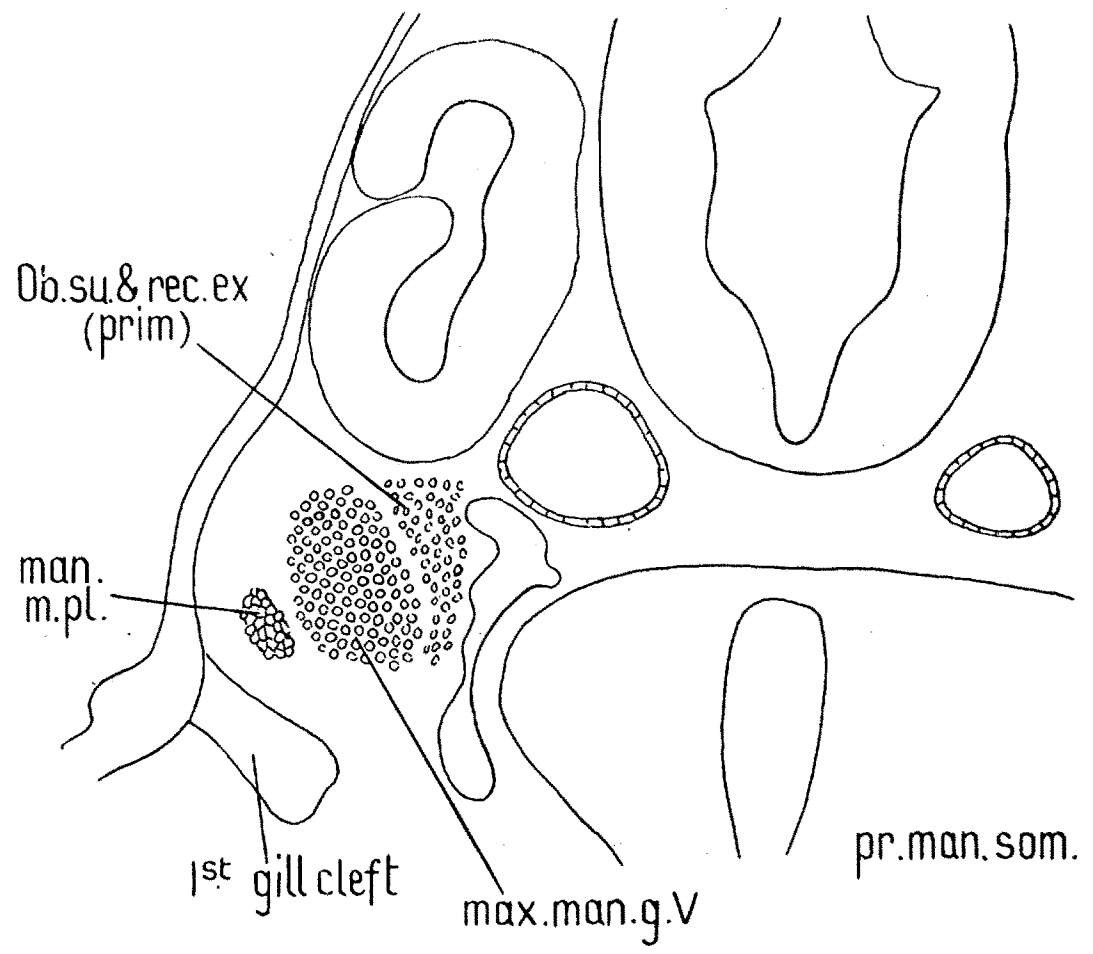

66

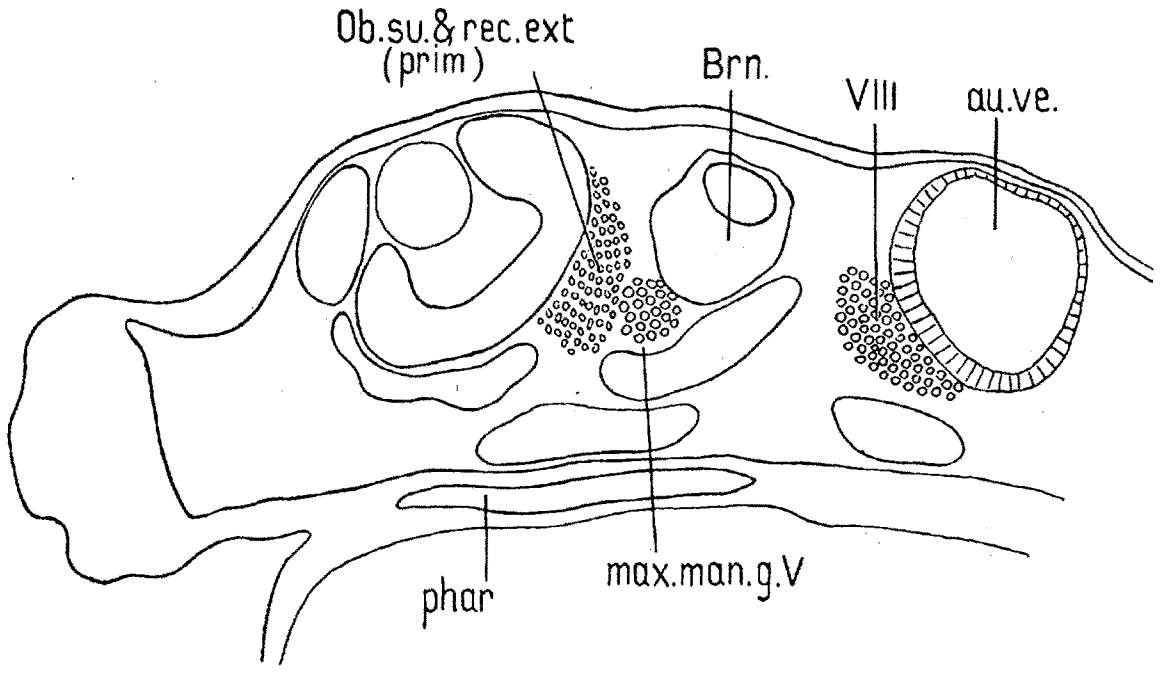

67

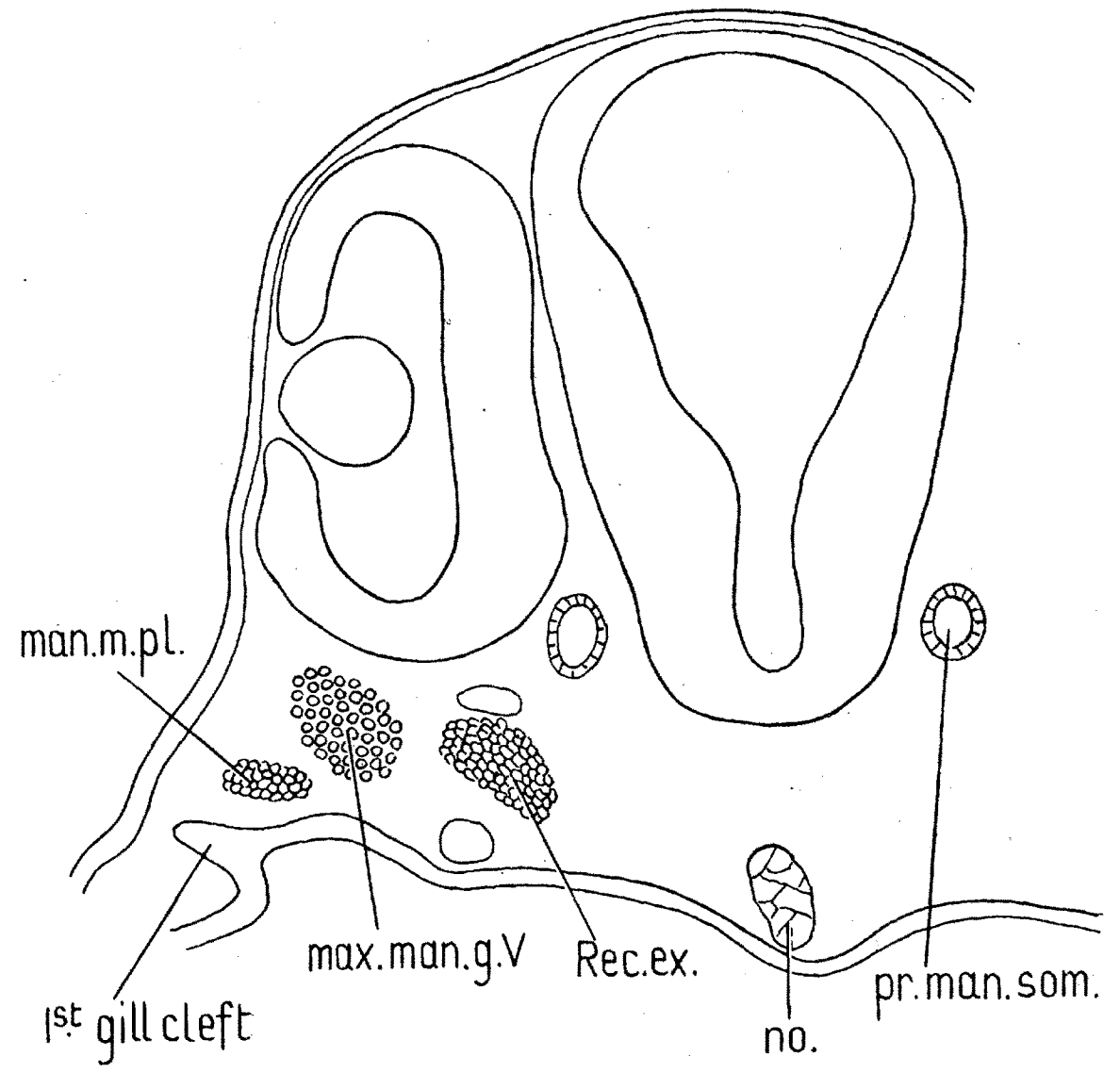

70

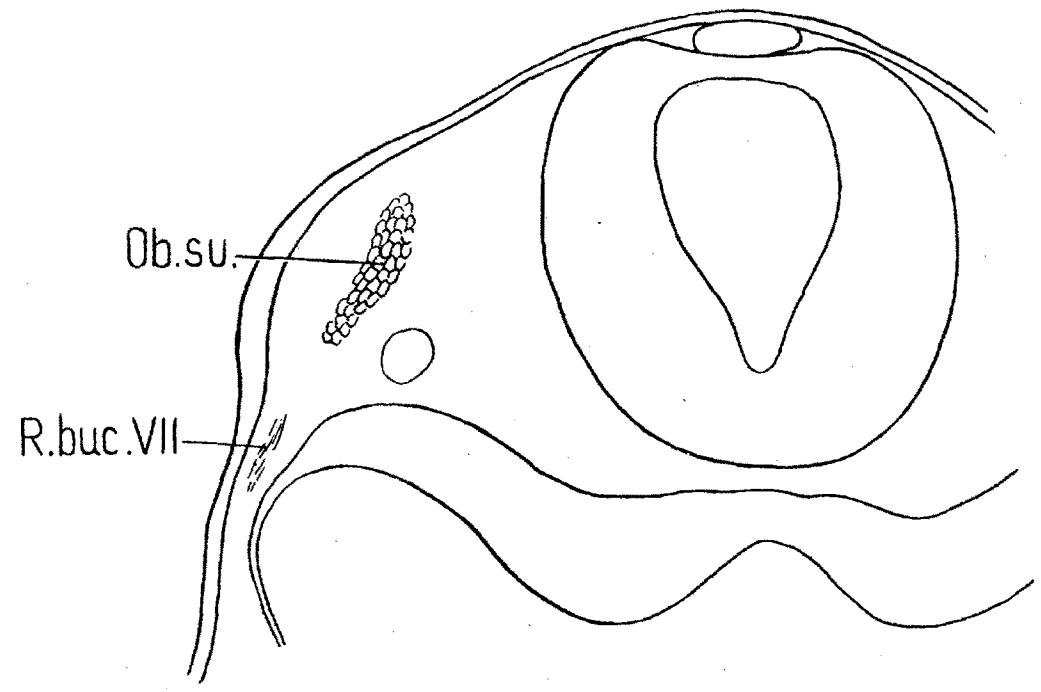

68

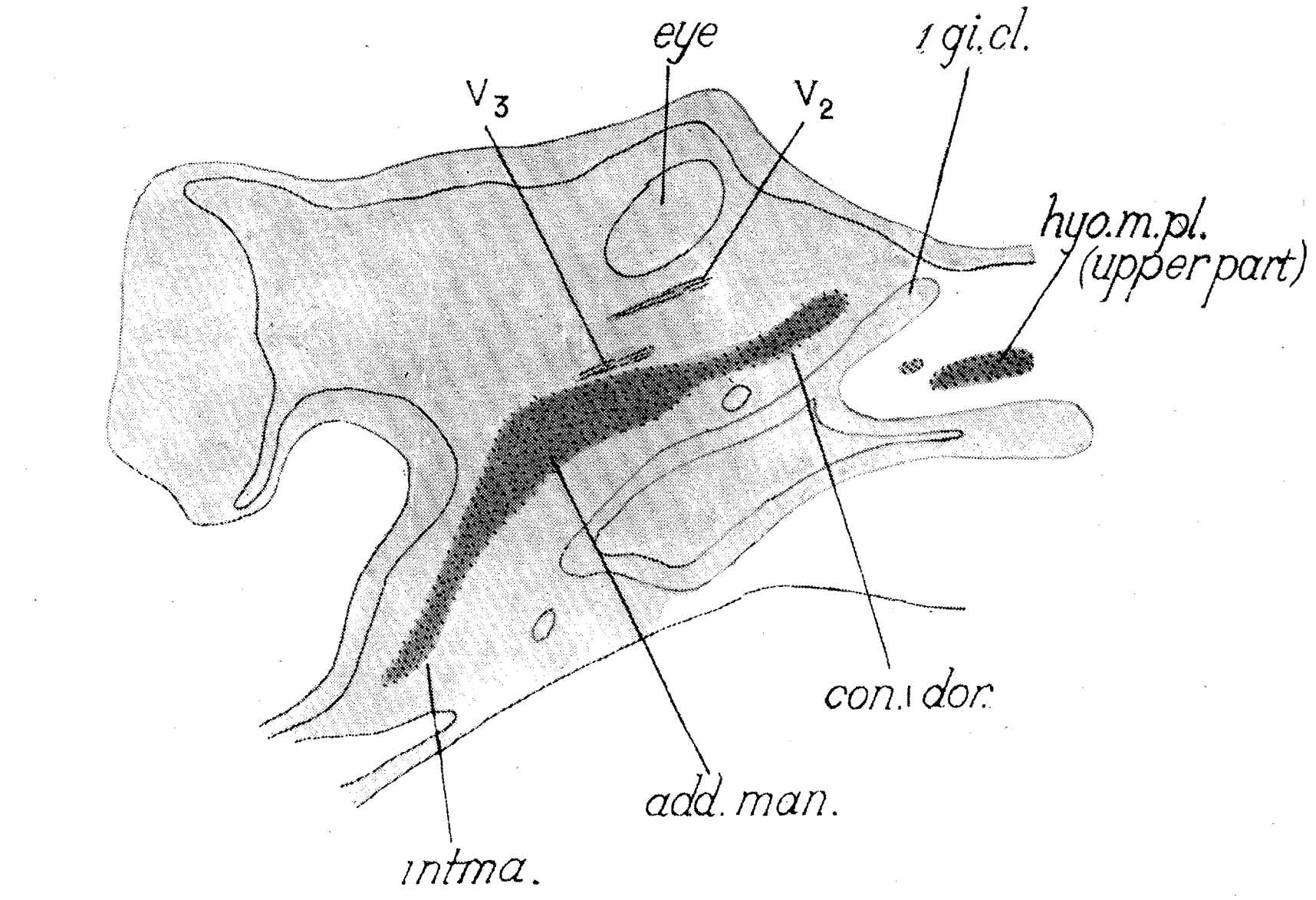

71

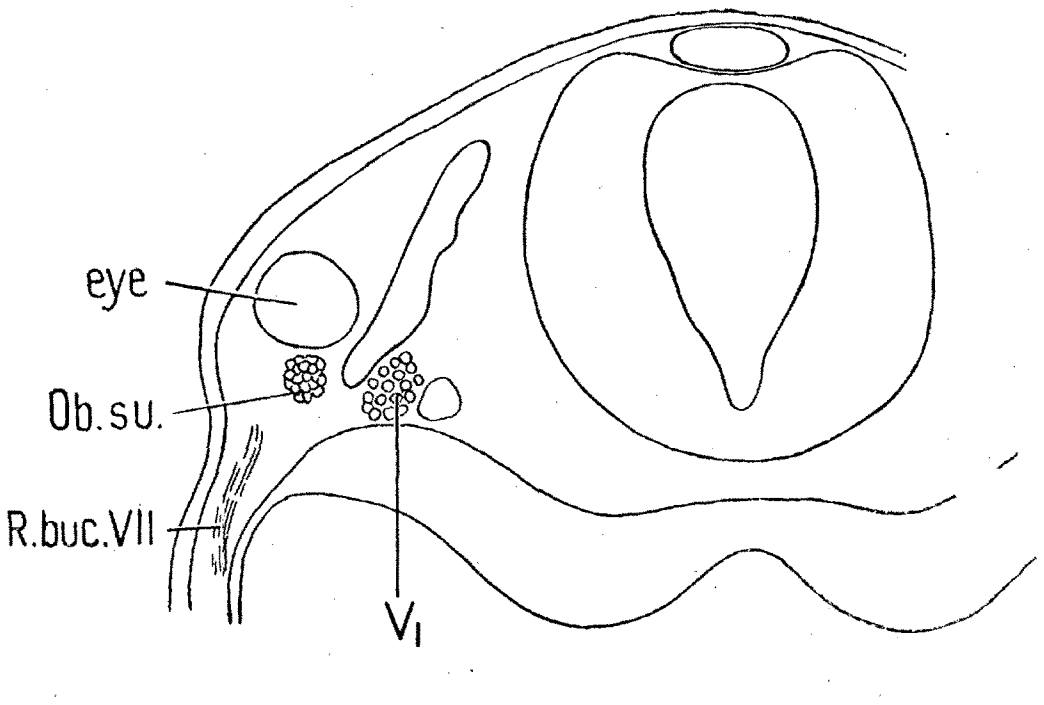

69

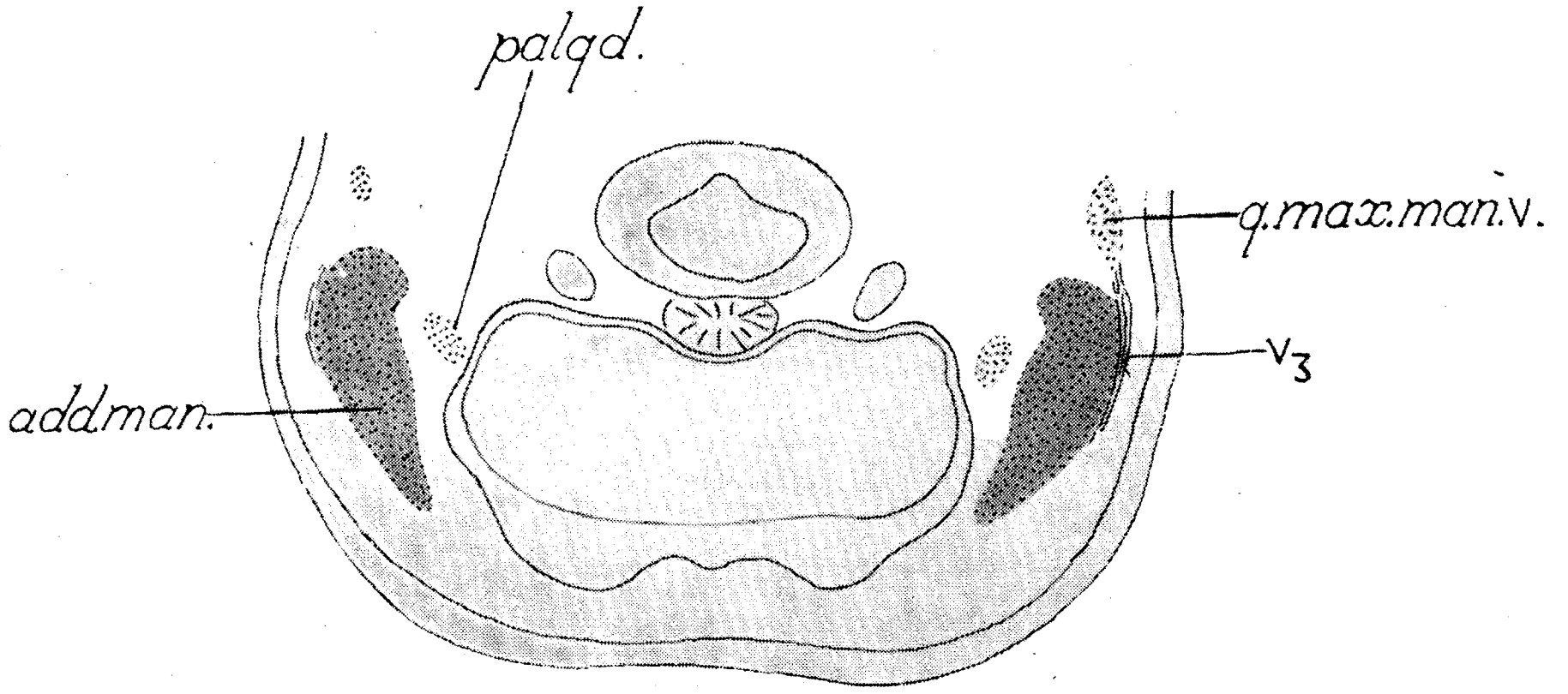

72

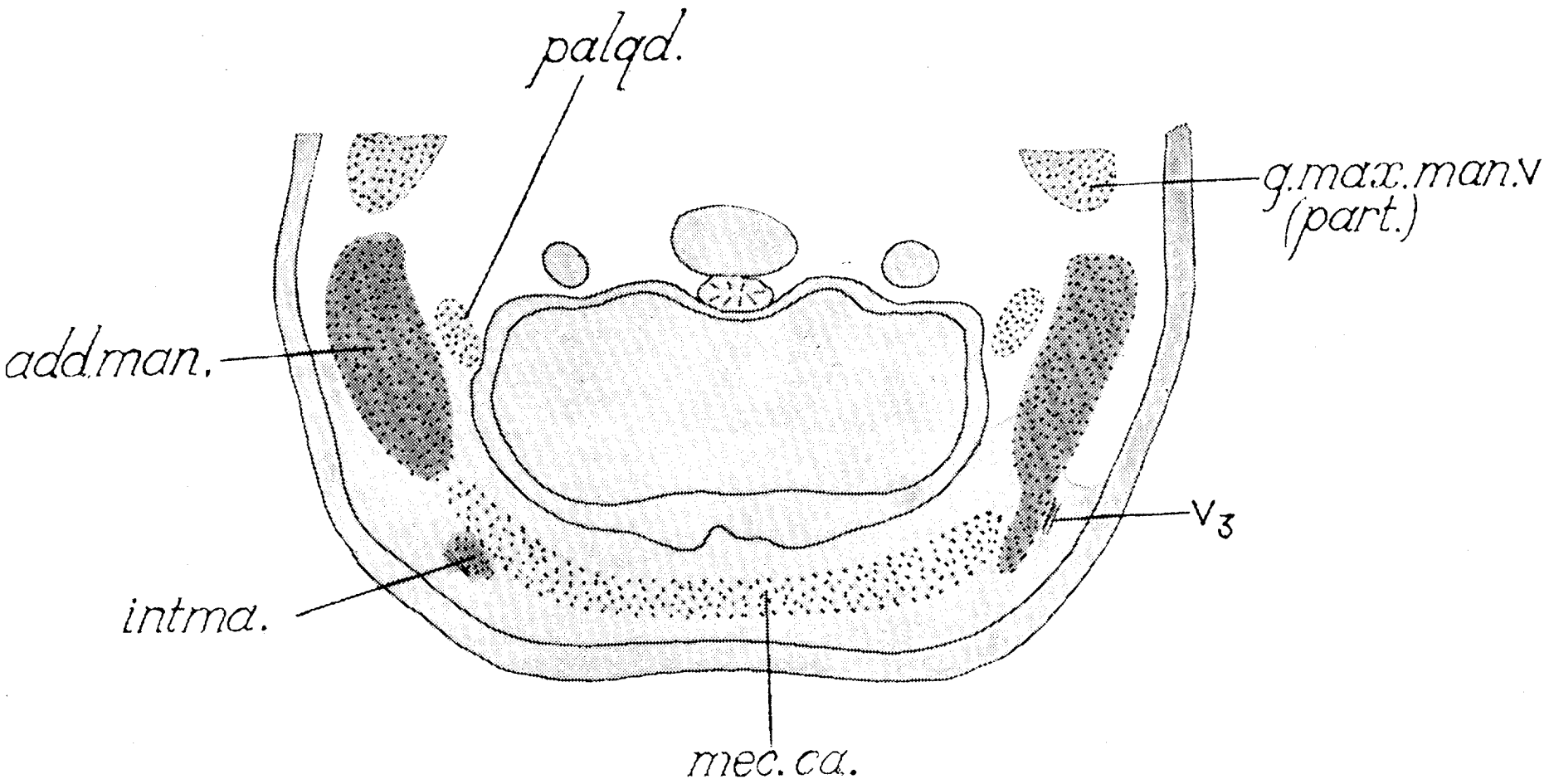

73

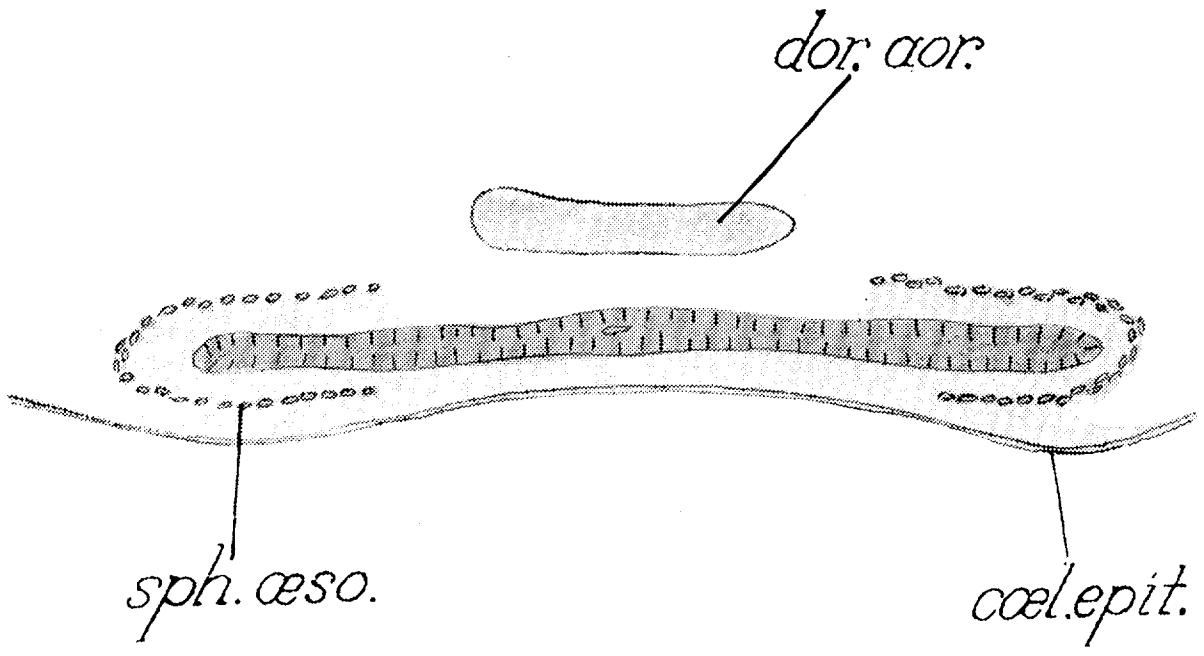

76

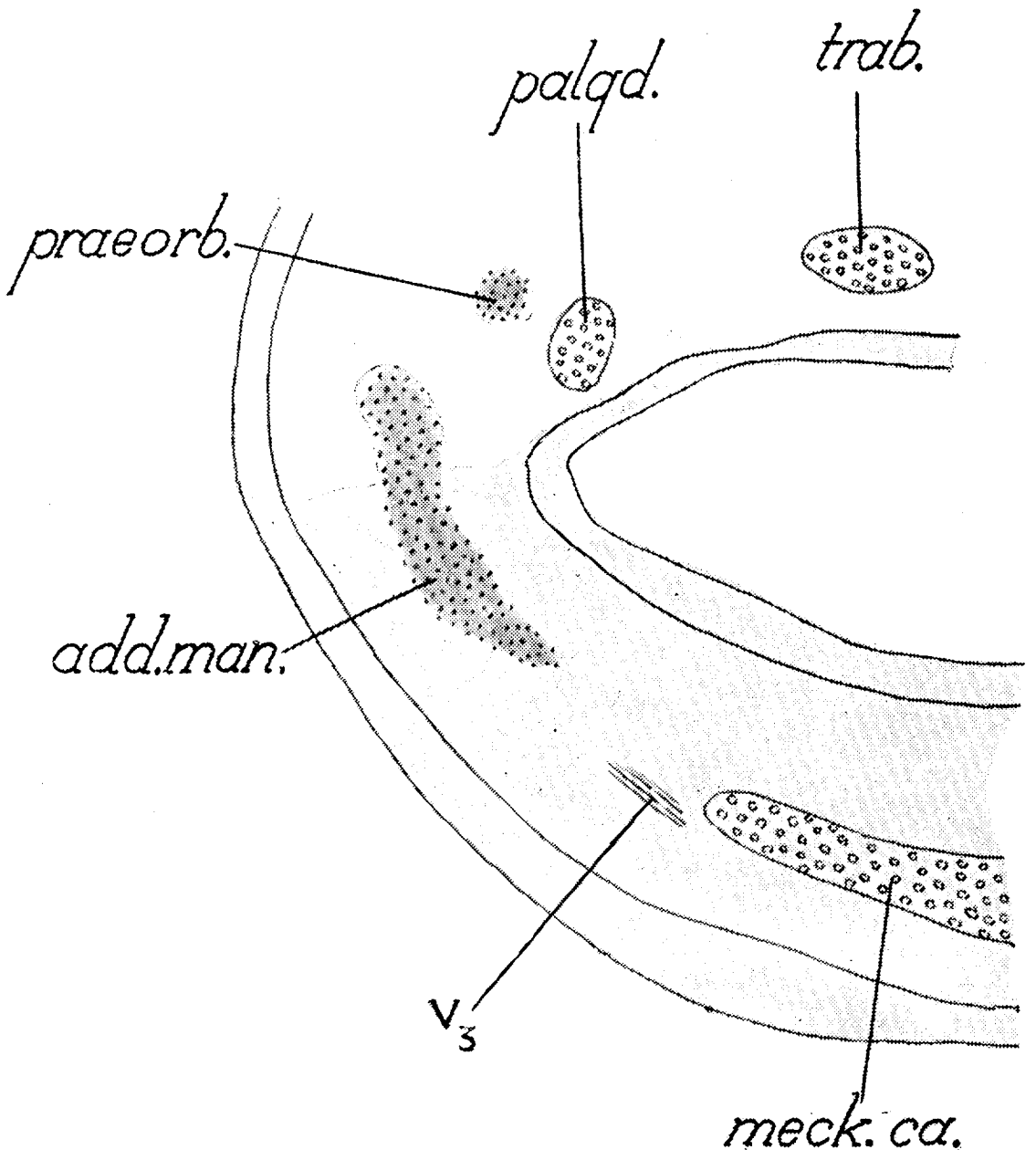

77

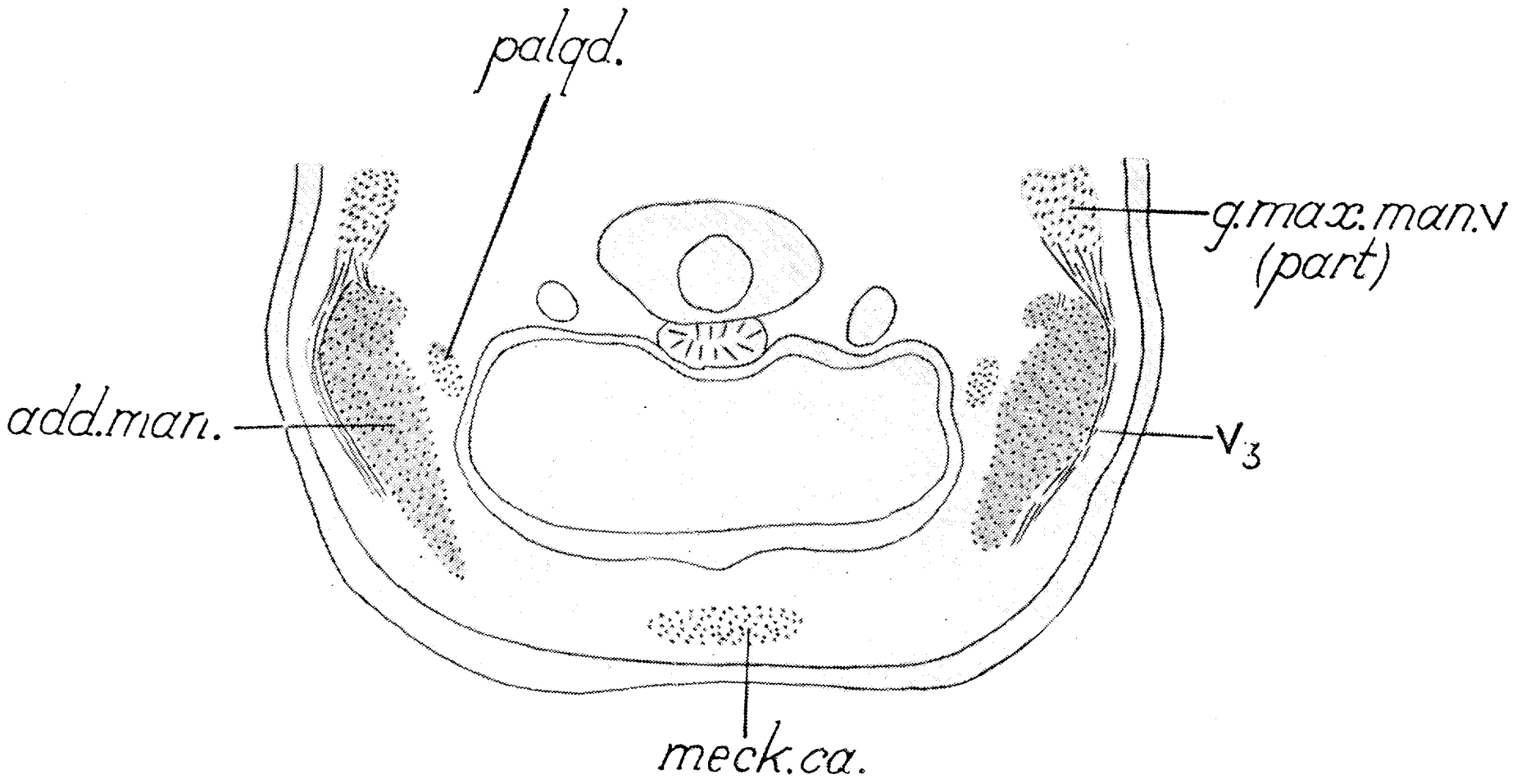

74

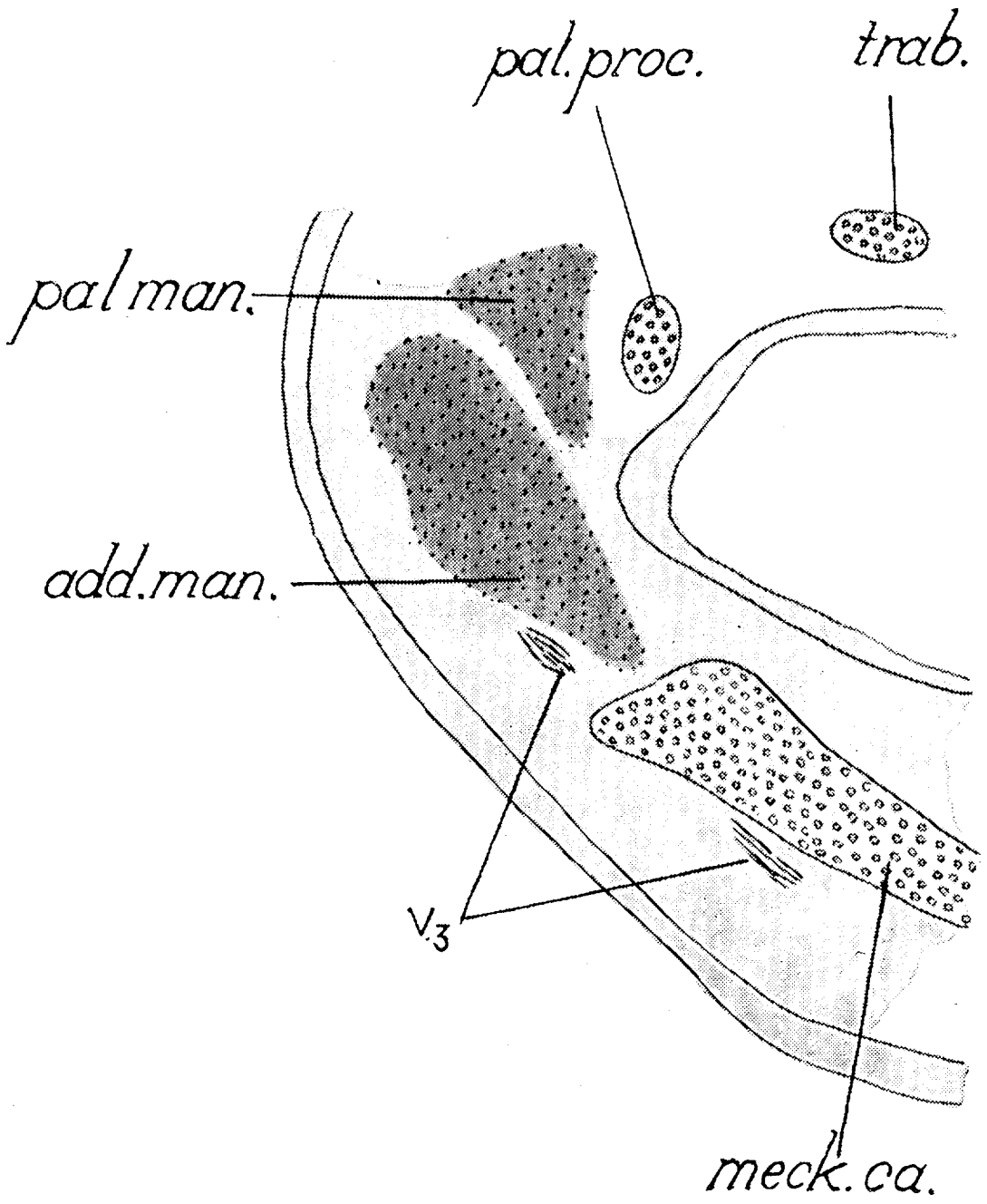

78

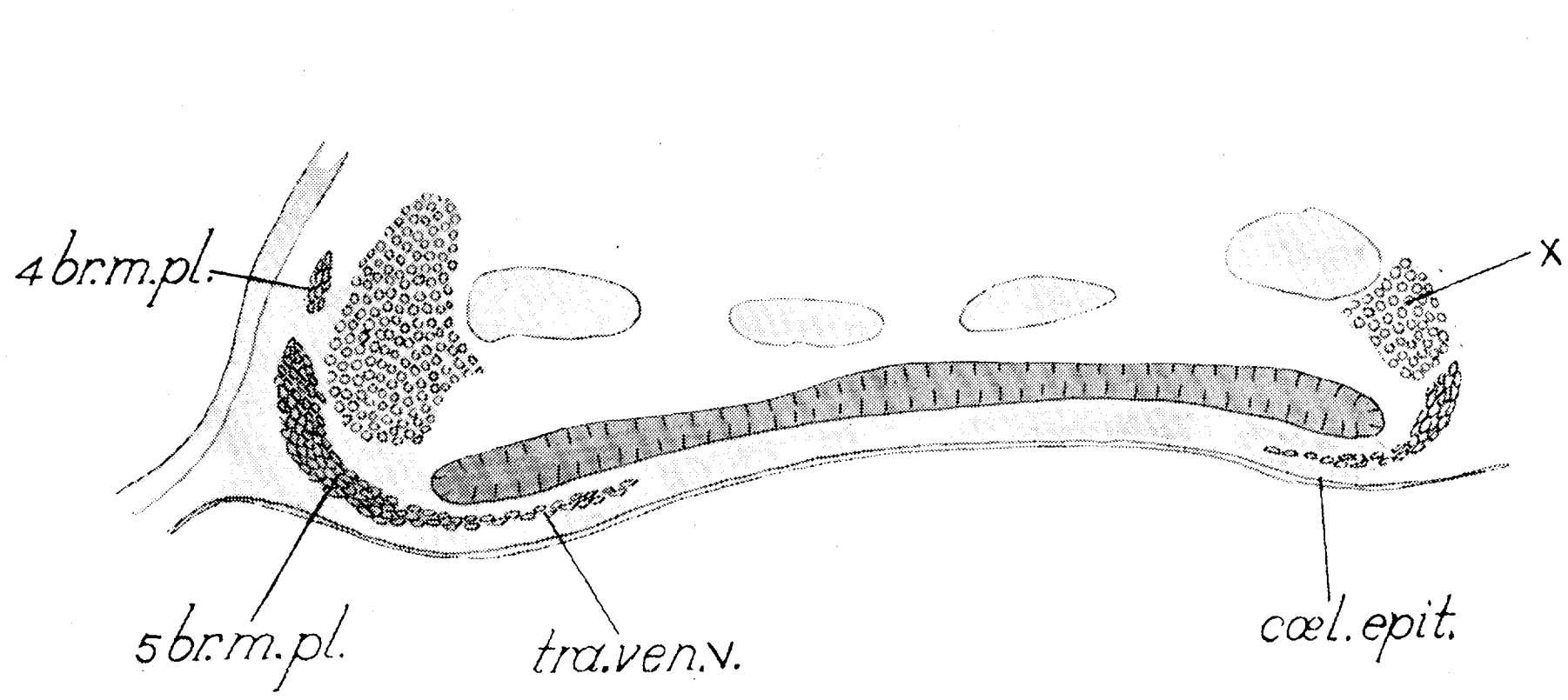

75

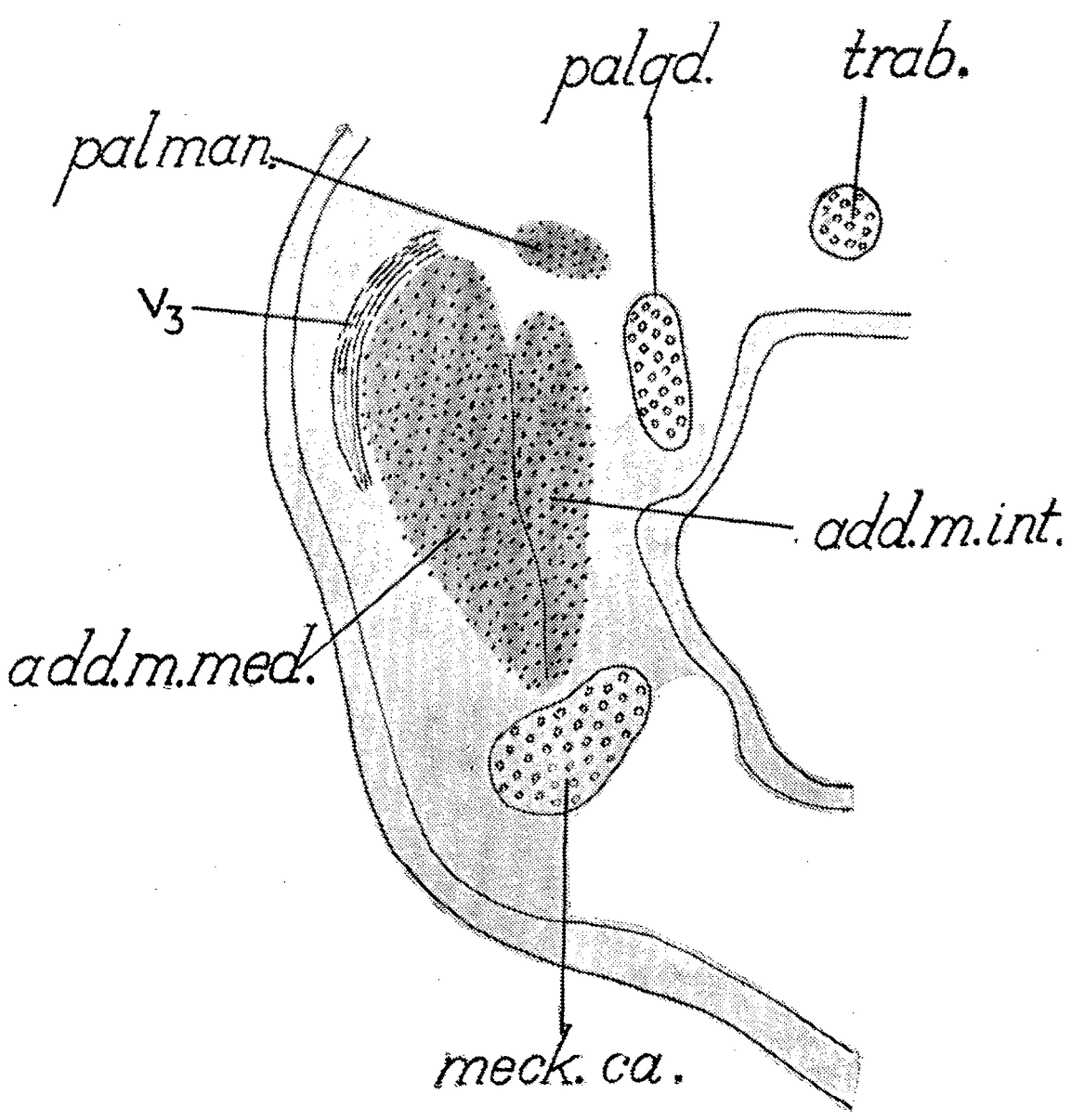
palqd.
trab.
palman.
V3
add.m.int.
add.m.med.
meck.ca.

79

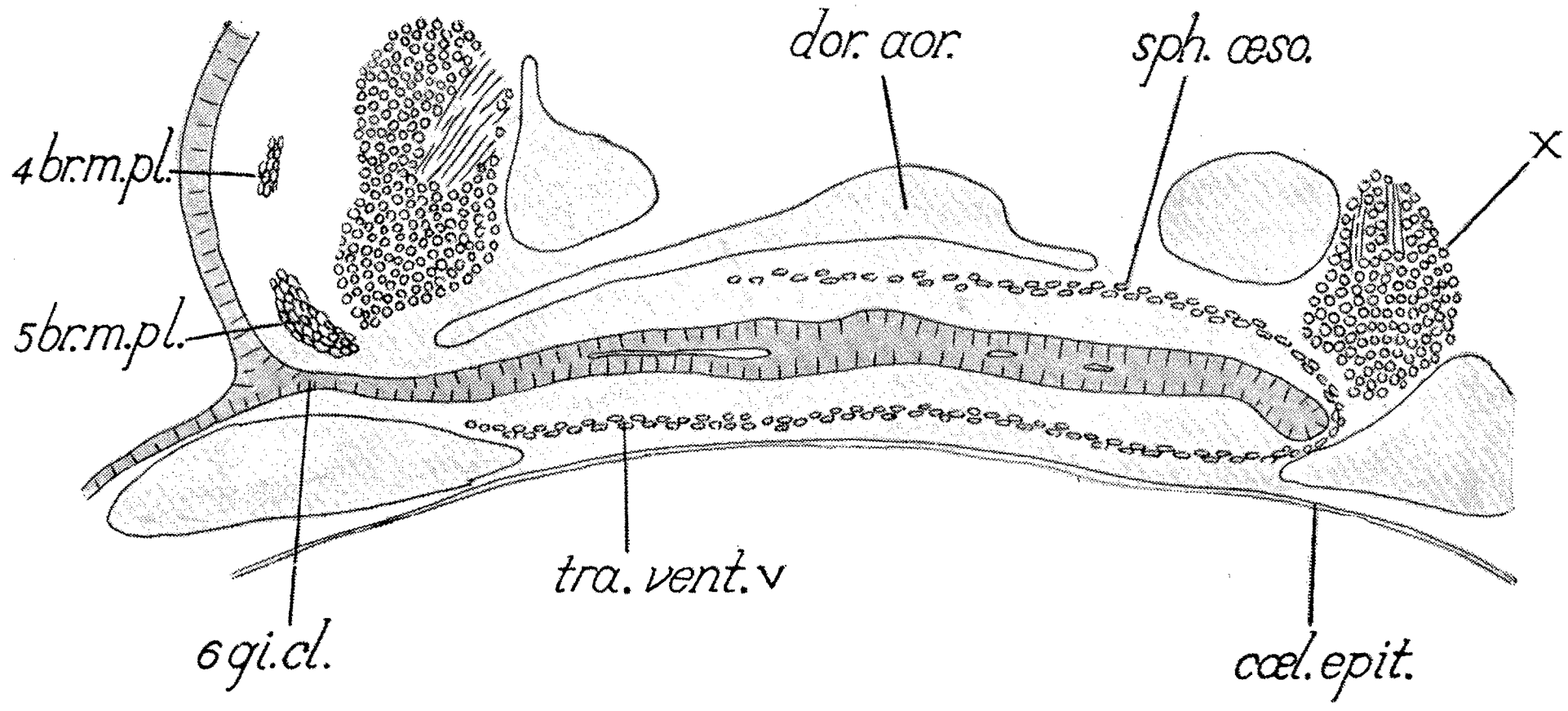
dor. aor.
sph. œso.
X
4br.m.pl.
5br.m.pl.
tra. vent.v
6gi.cl.
cœl. epit.

80

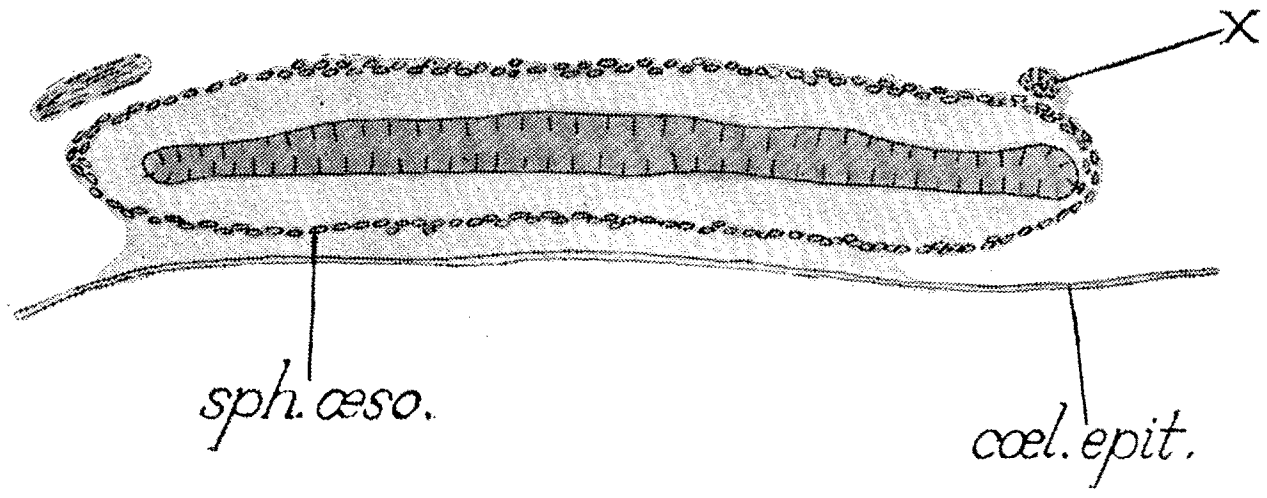
X
sph. œso.
cœl. epit.

81

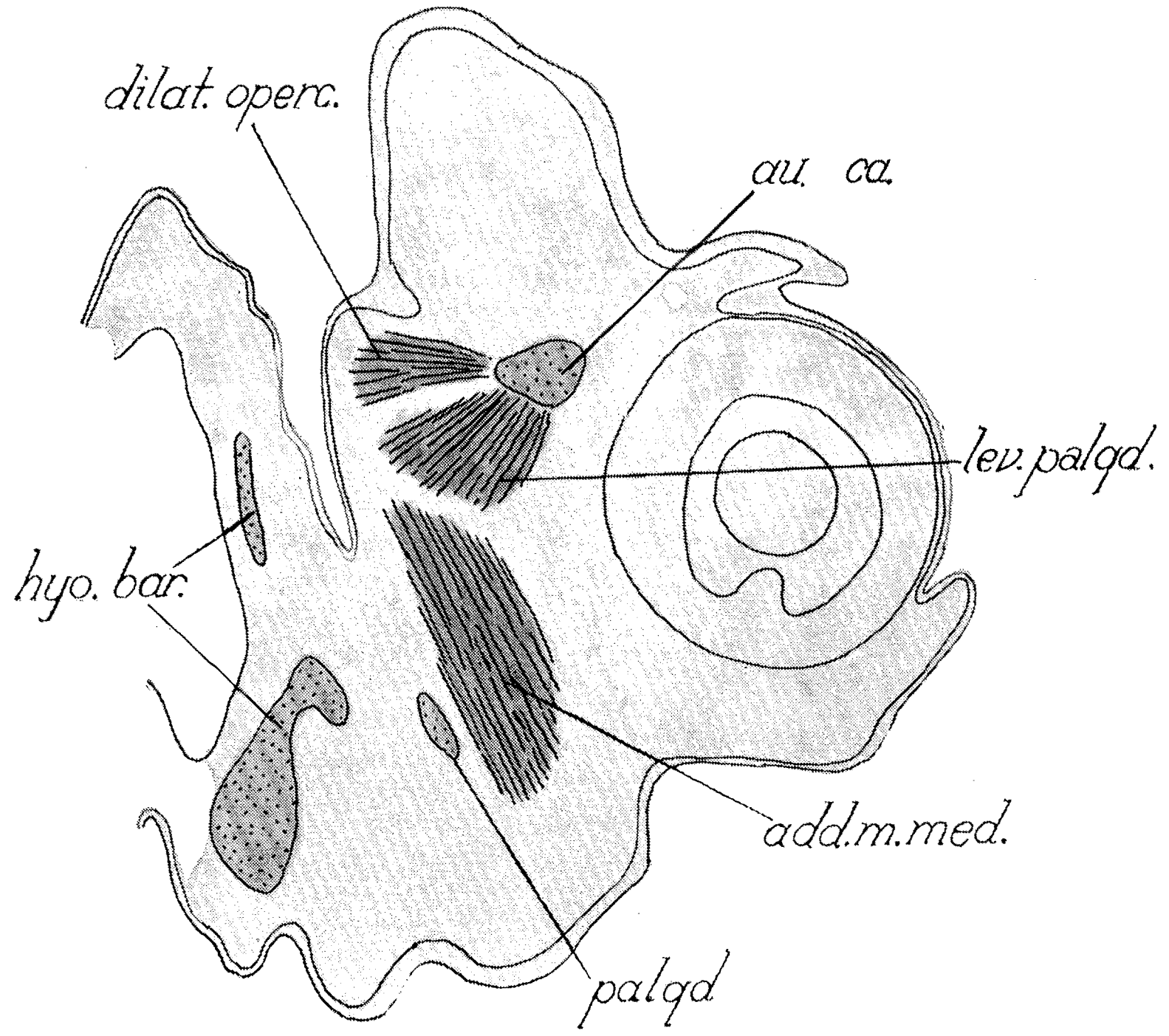
dilat. operc.
au. ca.
lev. palqd.
hyo. bar.
add.m.med.
palqd

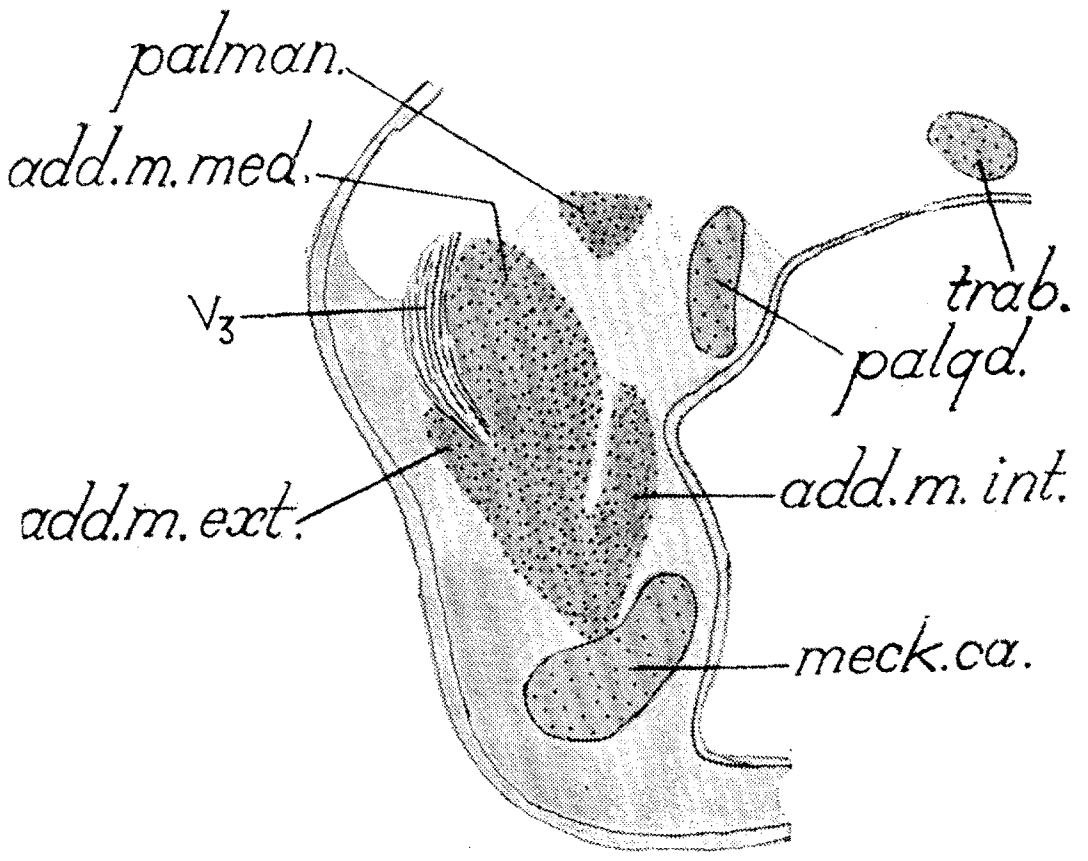
palman.
add.m.med.
trab.
V3
palqd.
add.m.ext.
add.m.int.
meck.ca.

82

83

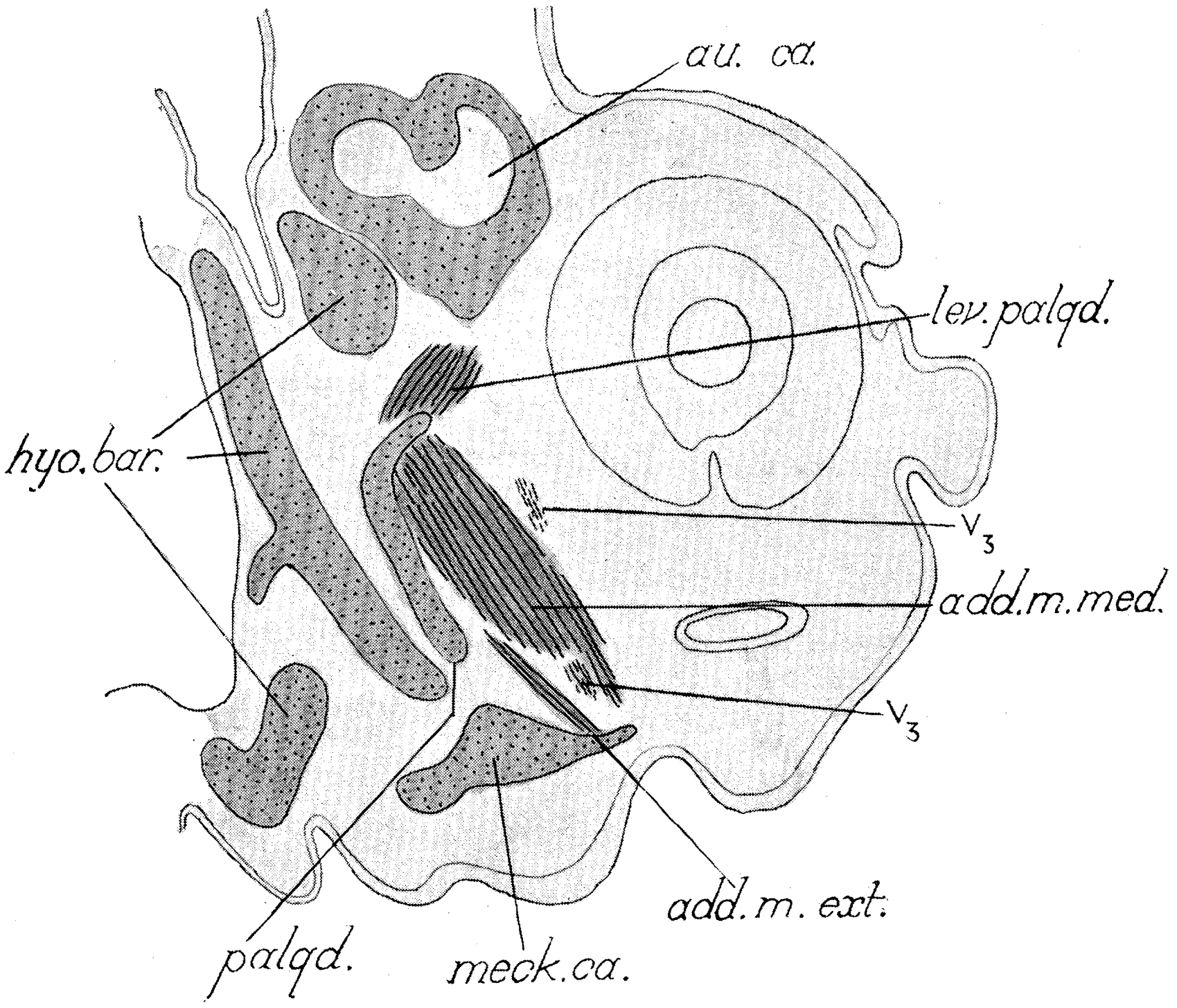

84

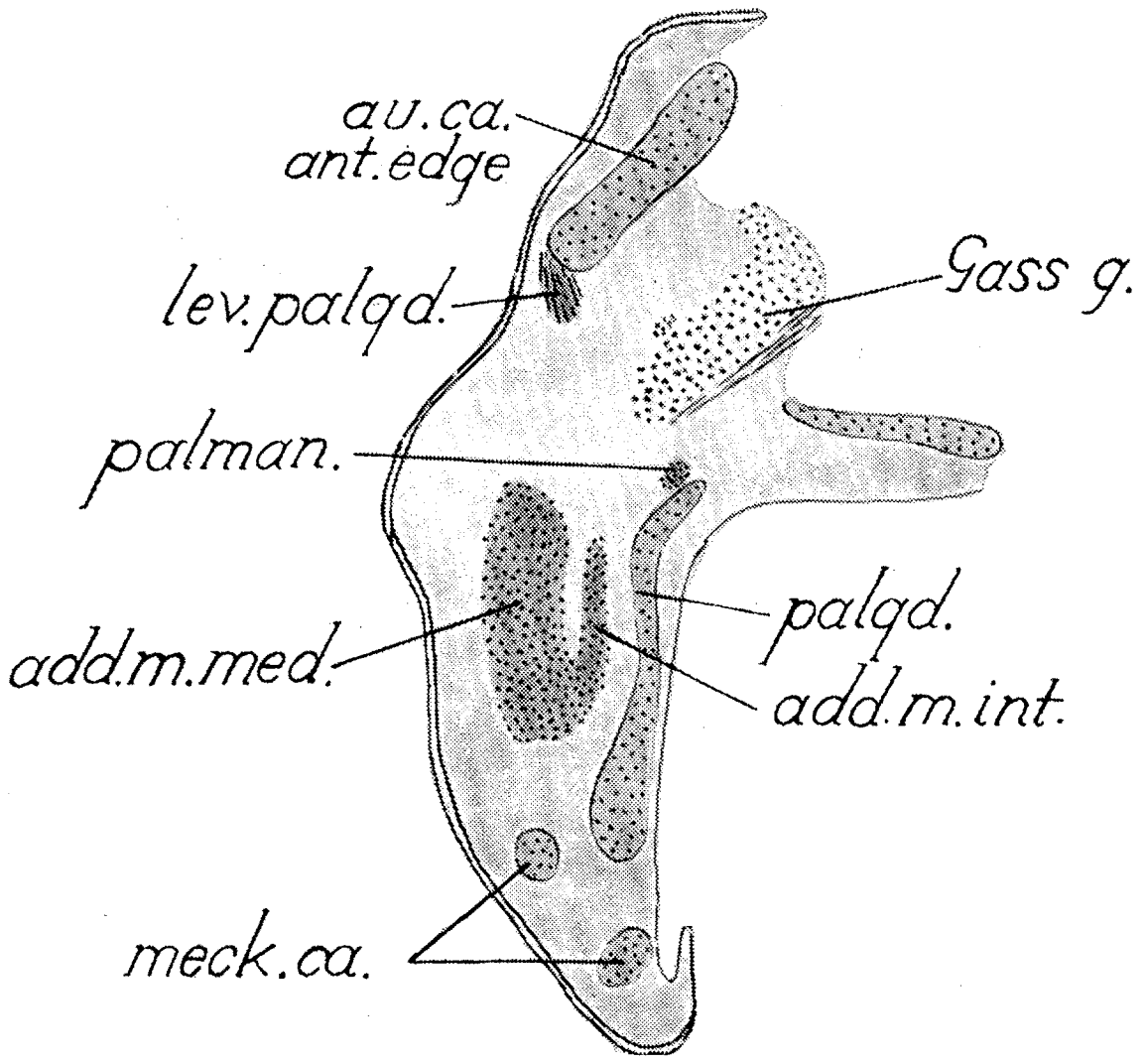

85

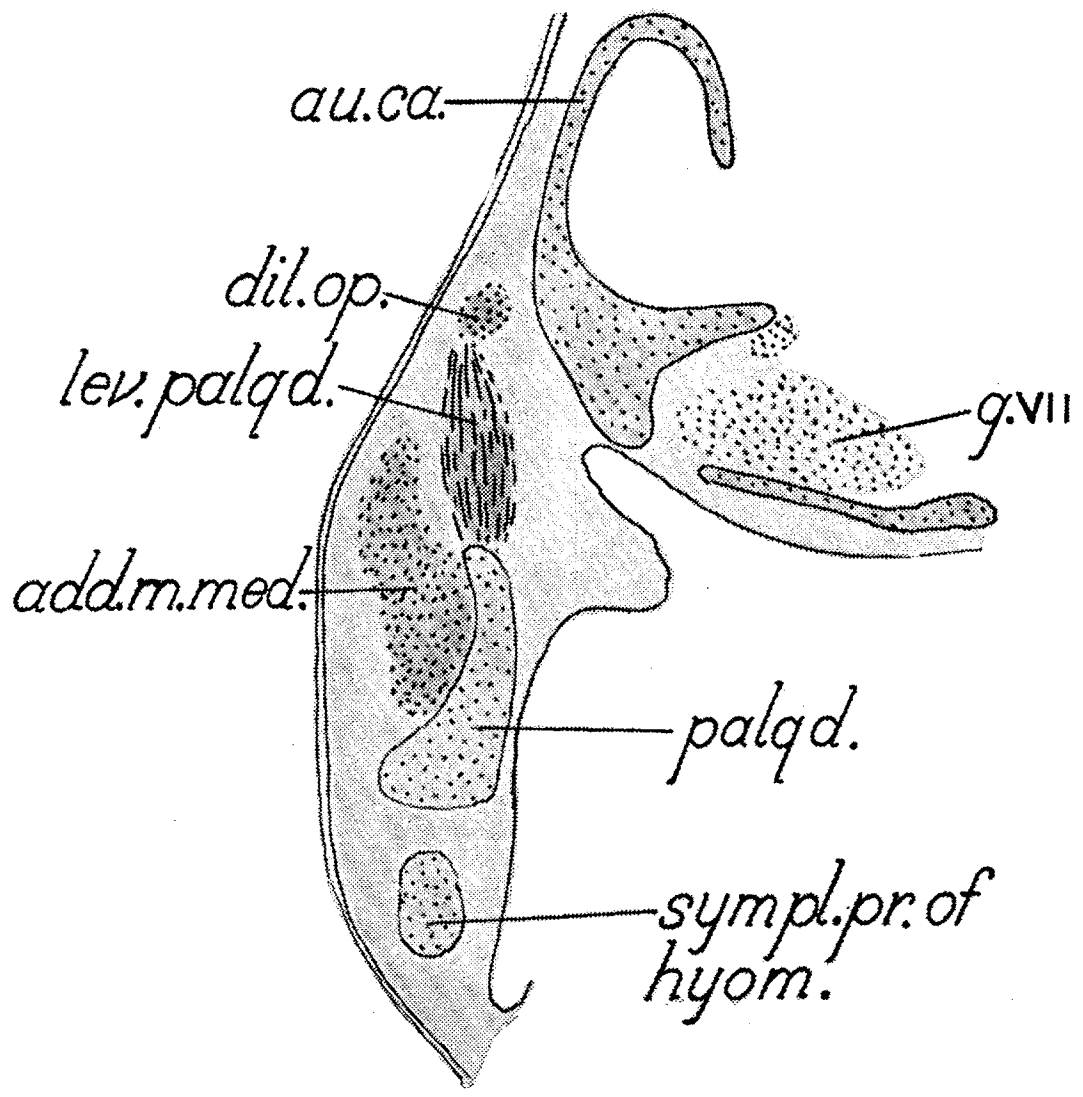

86

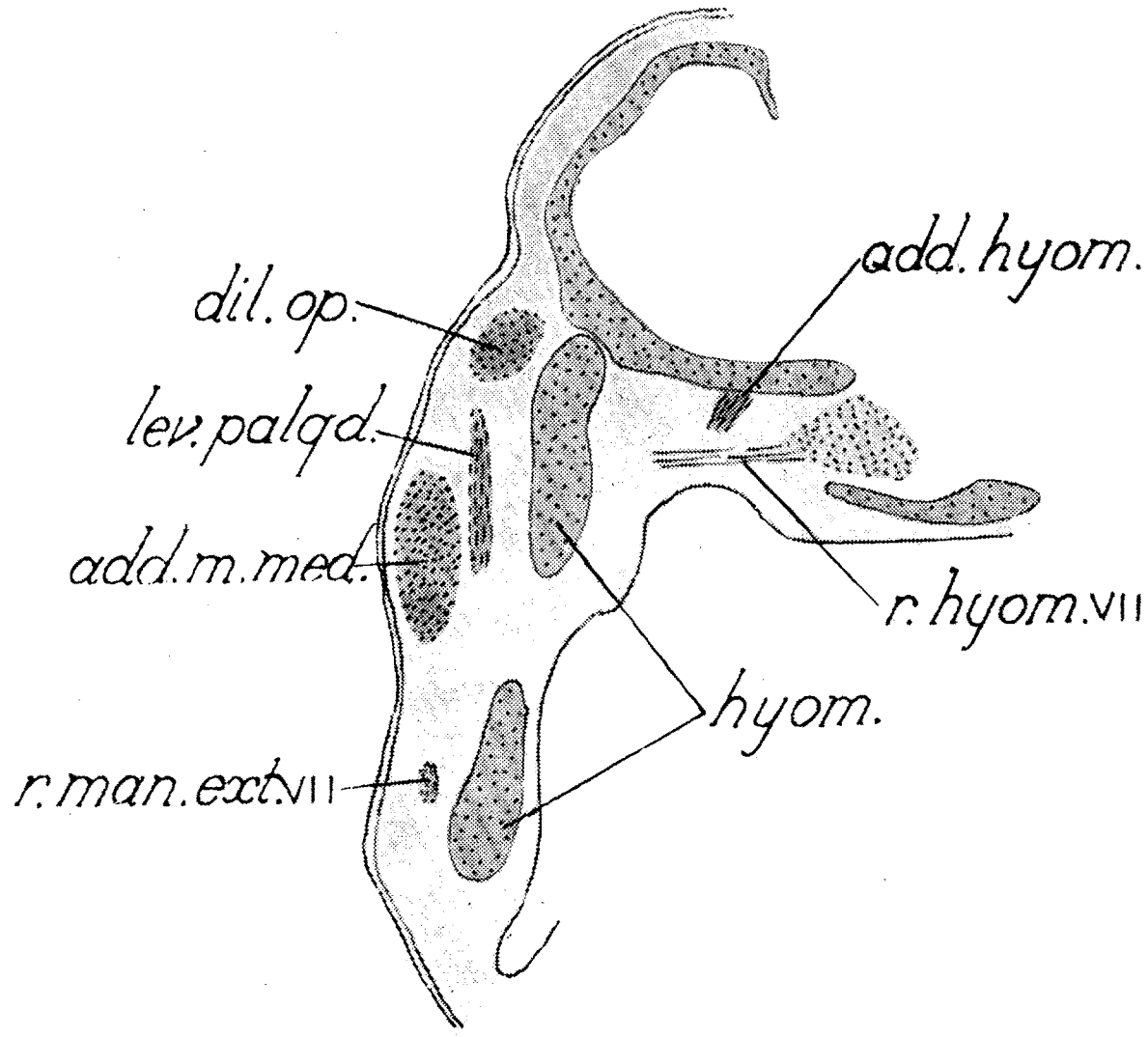

87

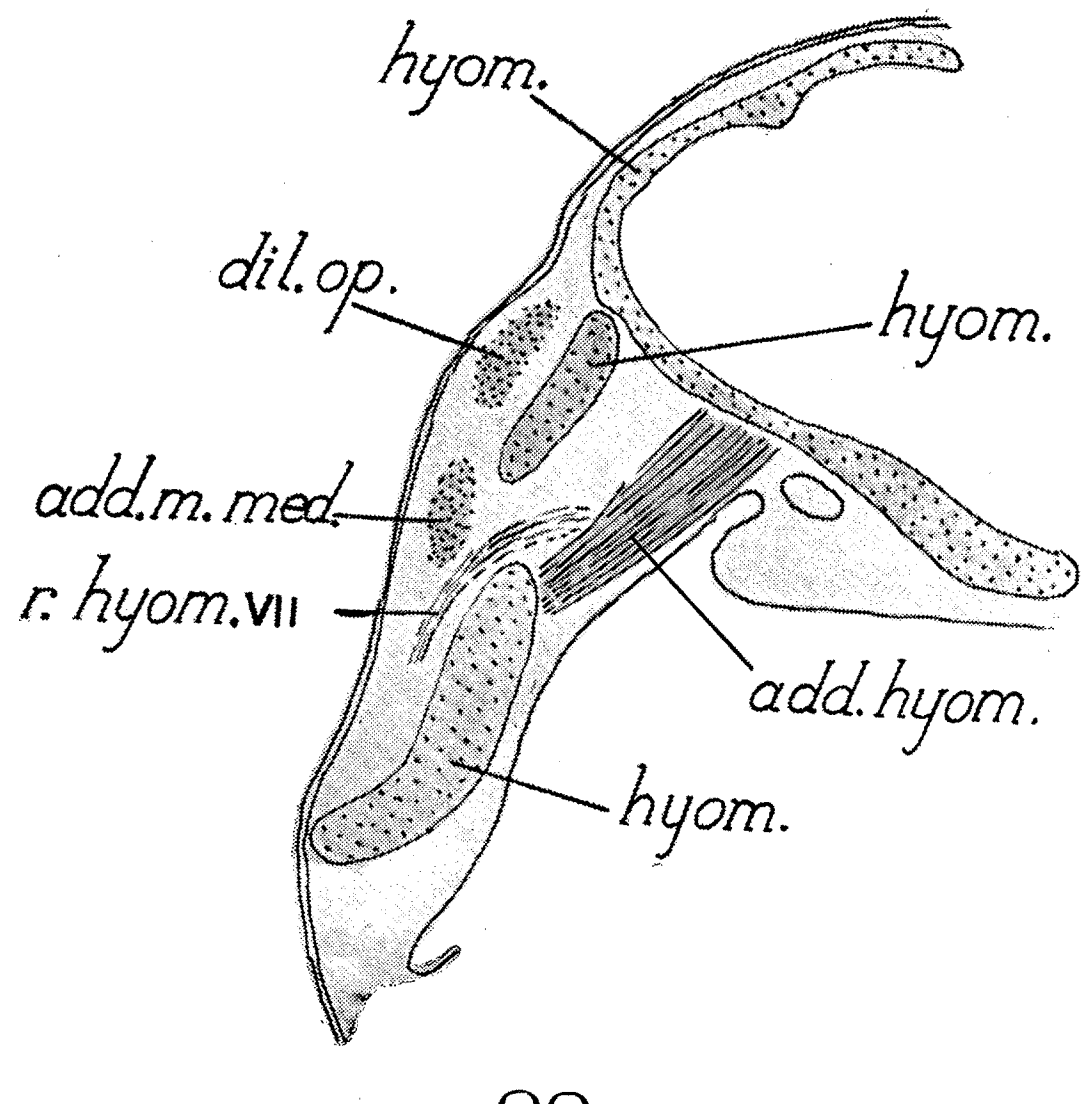

88

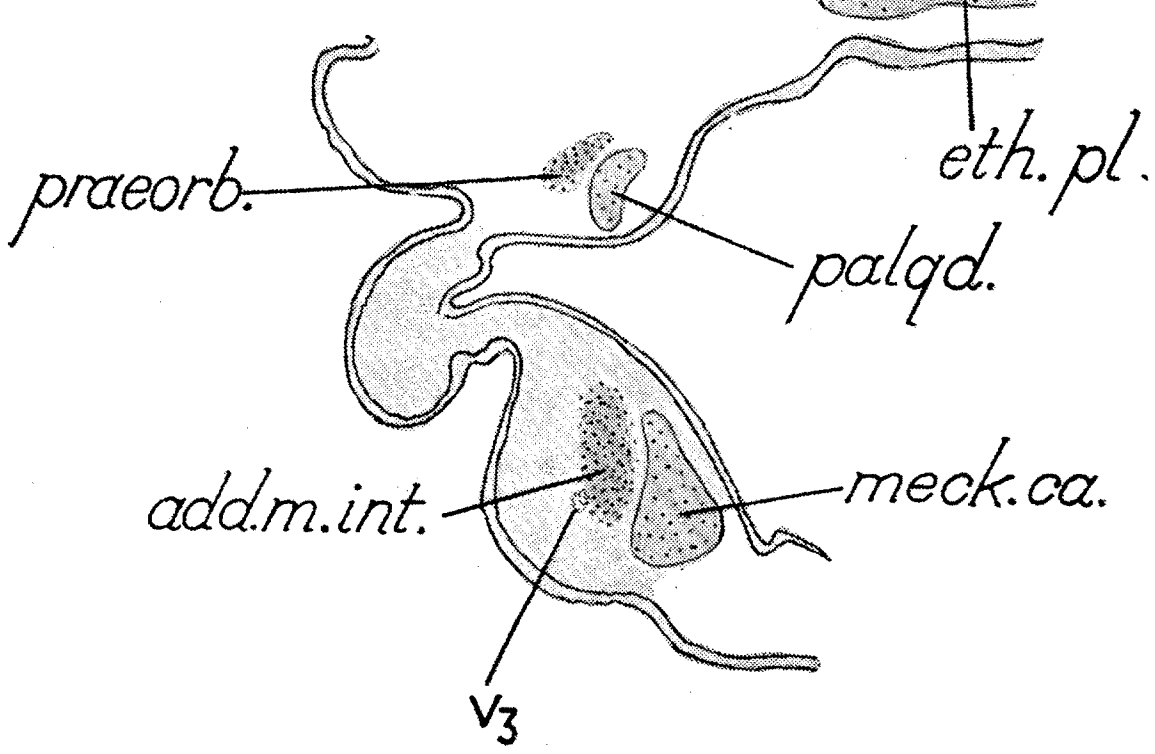

89

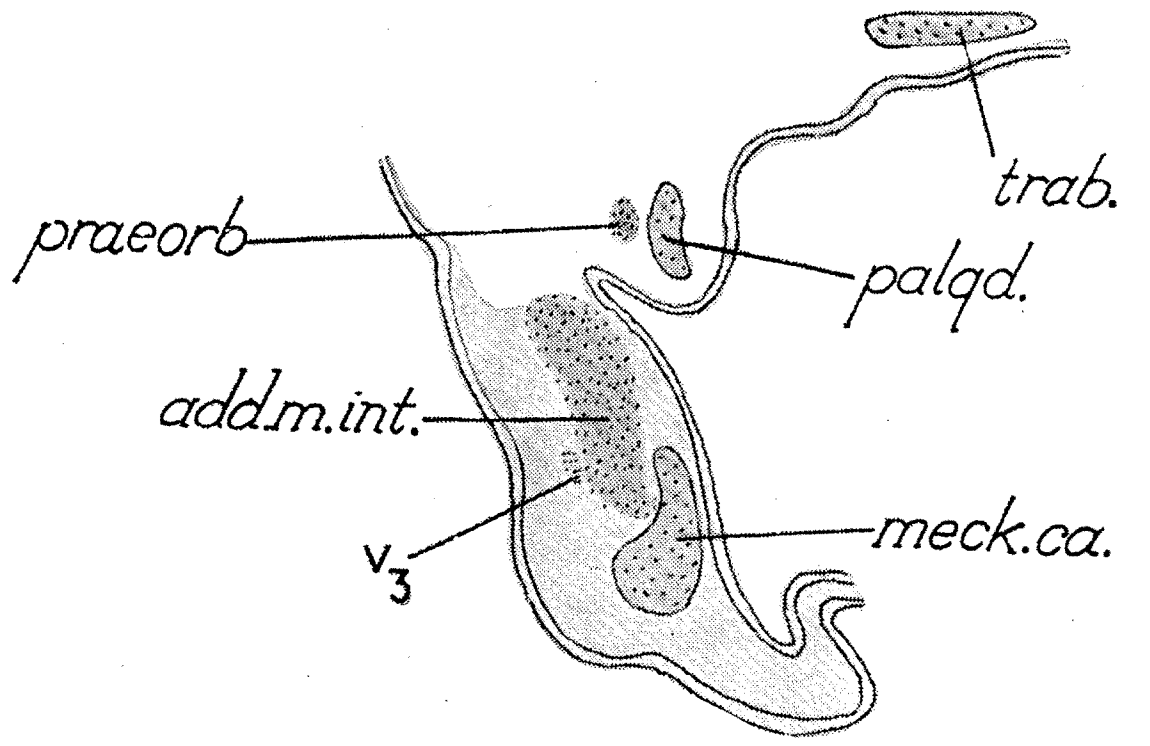
trab.
praeorb
palqd.
add.m.int.
meck.ca.
V_3

90

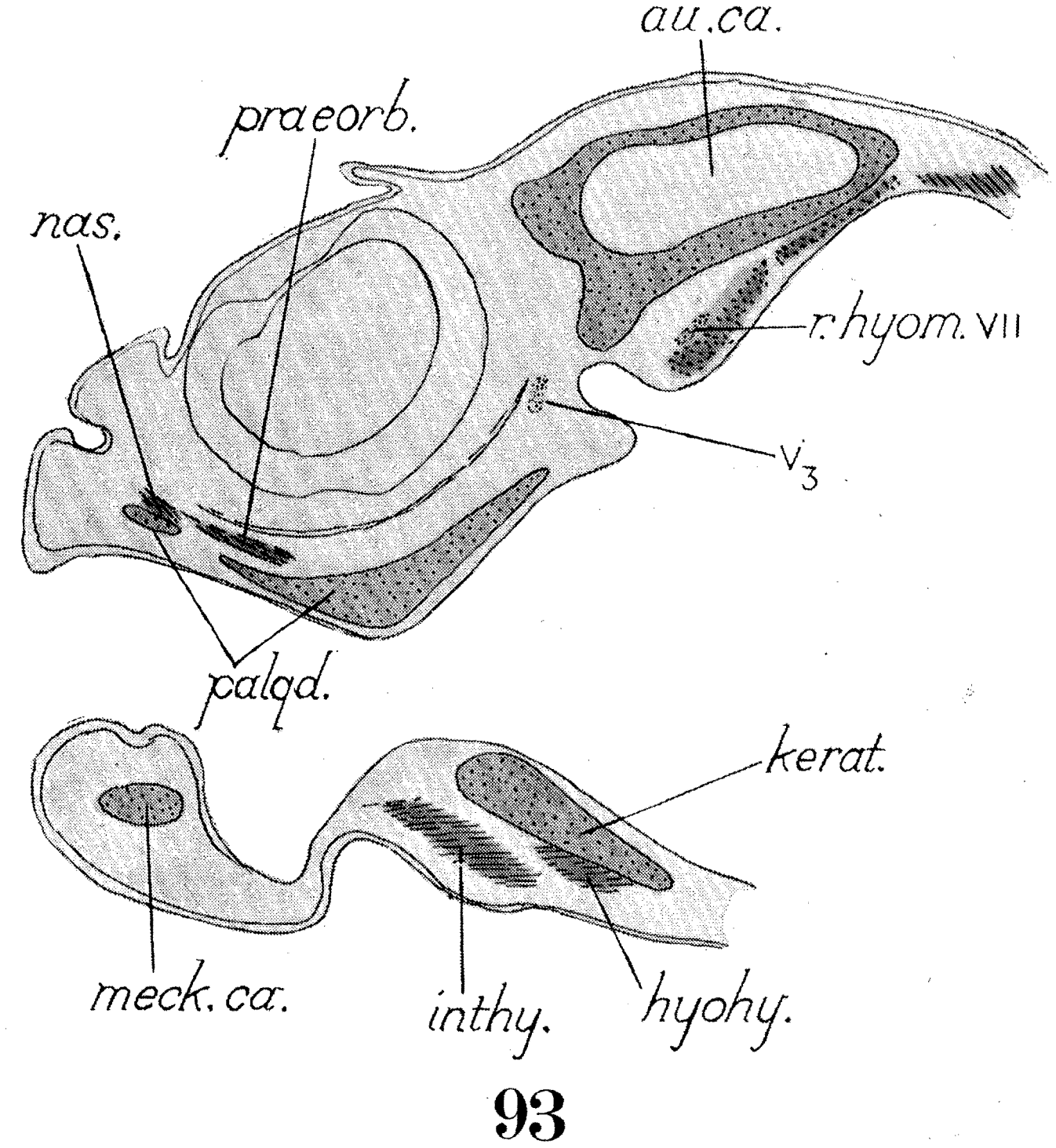
au.ca.
praeorb.
nas.
r.hyom.VII
V_3
palqd.
kerat.
meck.ca.
inthy.
hyohy.

93

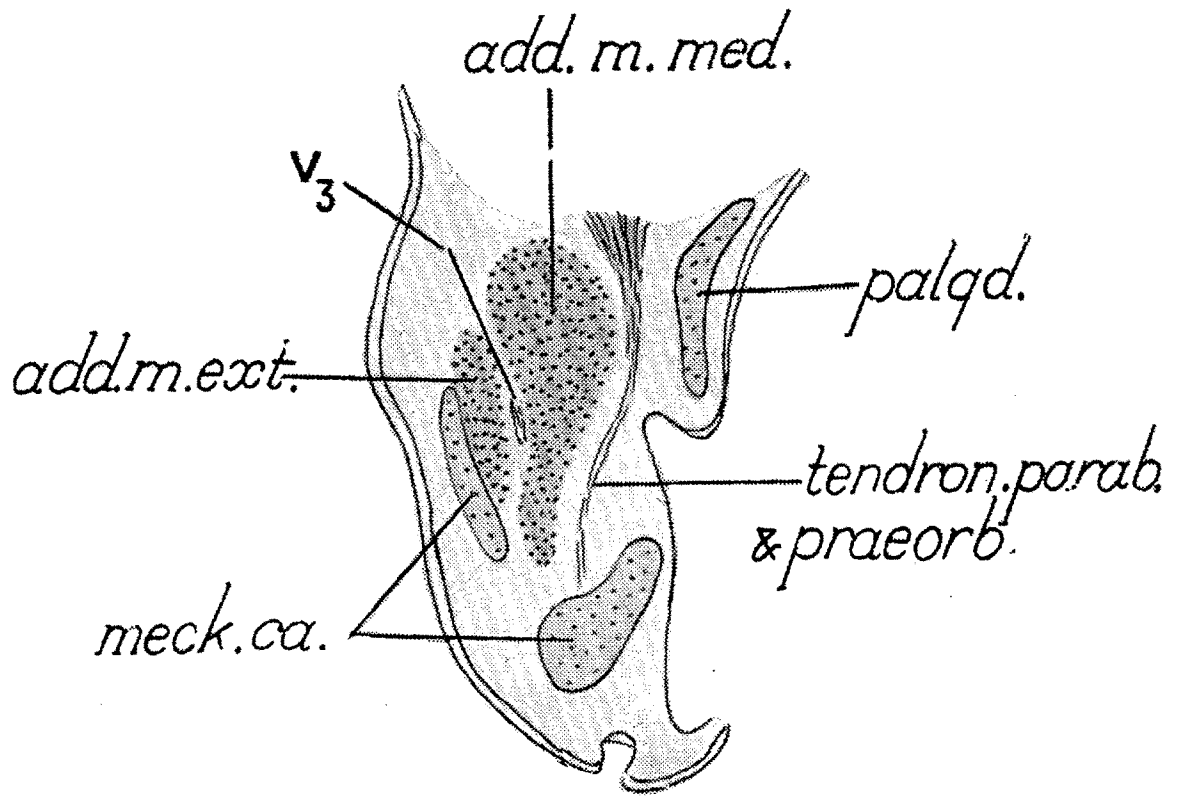
add.m.med.
V_3
palqd.
add.m.ext.
tendron.parab. & praeorb.
meck.ca.

94

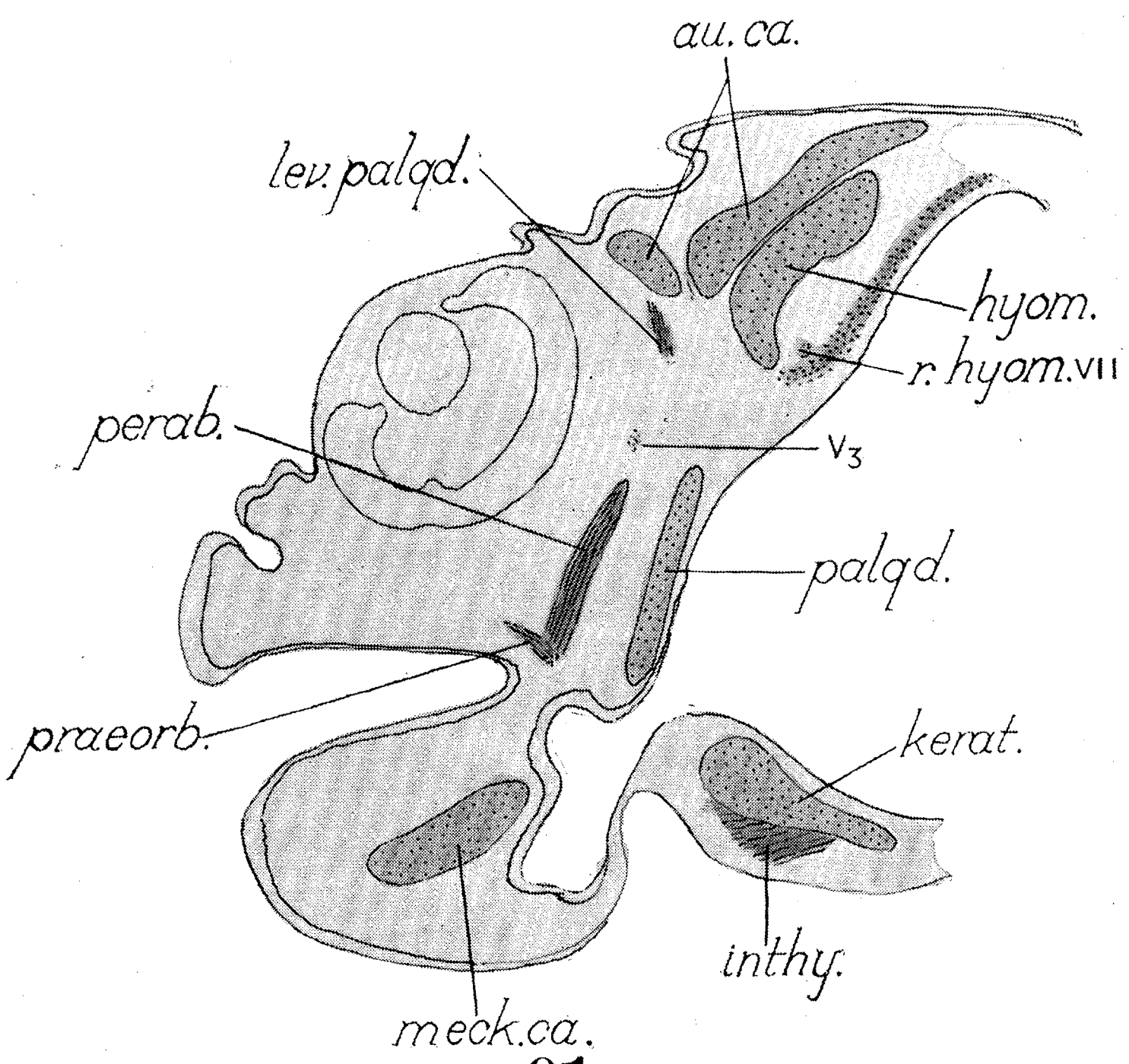
au.ca.
lev.palqd.
hyom.
r.hyom.VII
V_3
perab.
palqd.
praeorb.
kerat.
inthy.
meck.ca.

91

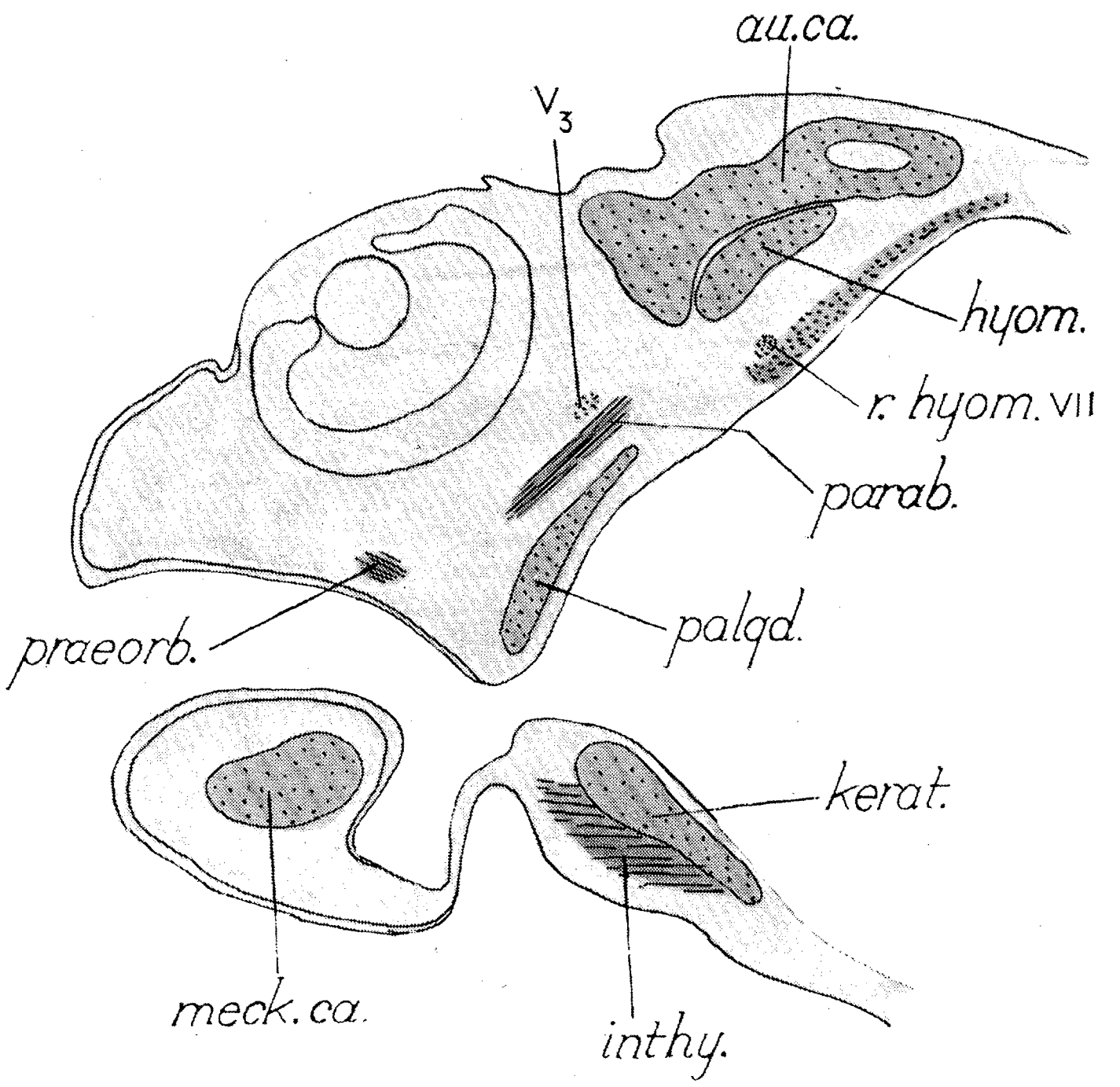
au.ca.
V_3
hyom.
r.hyom.VII
parab.
praeorb.
palqd.
kerat.
meck.ca.
inthy.

92

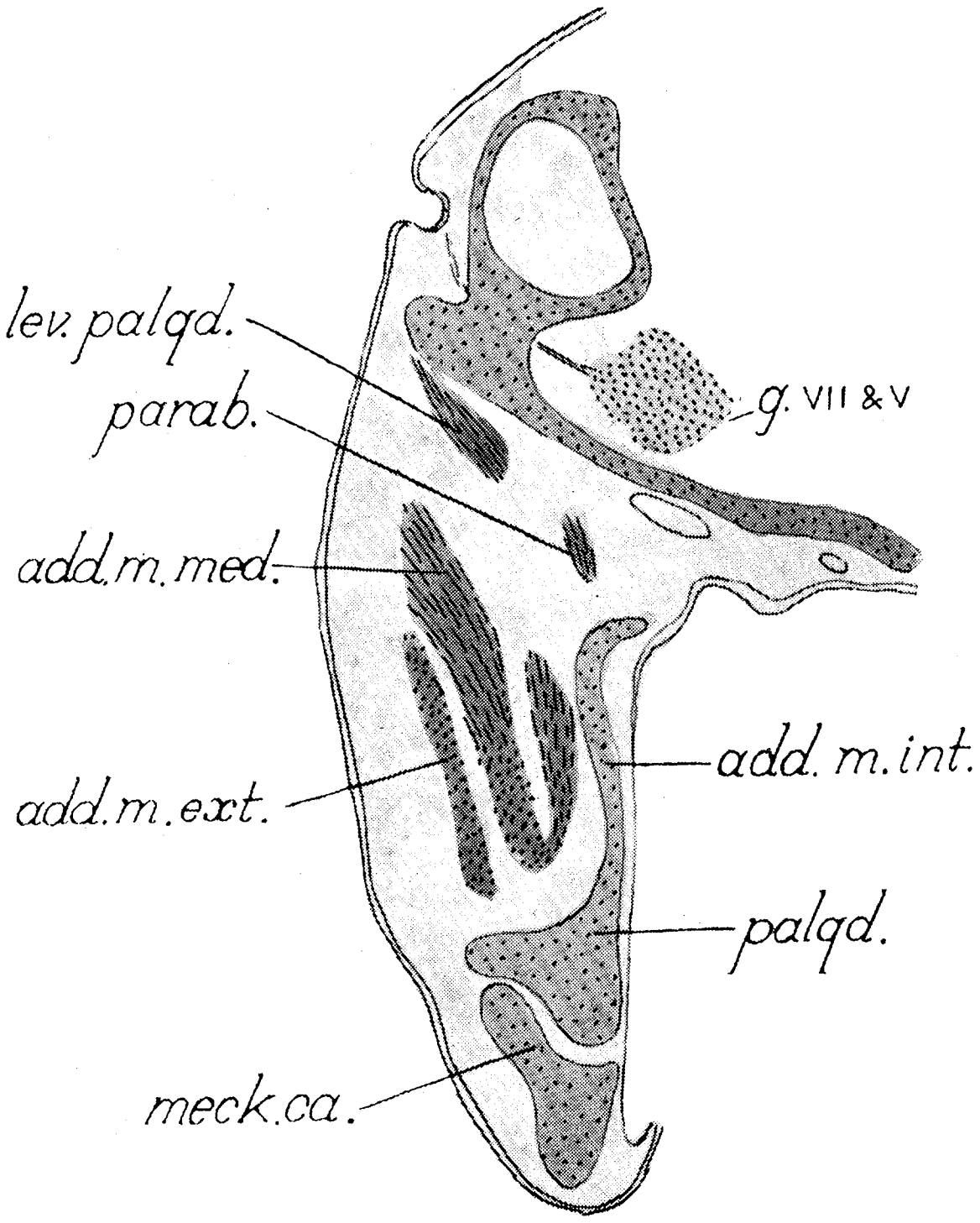

95

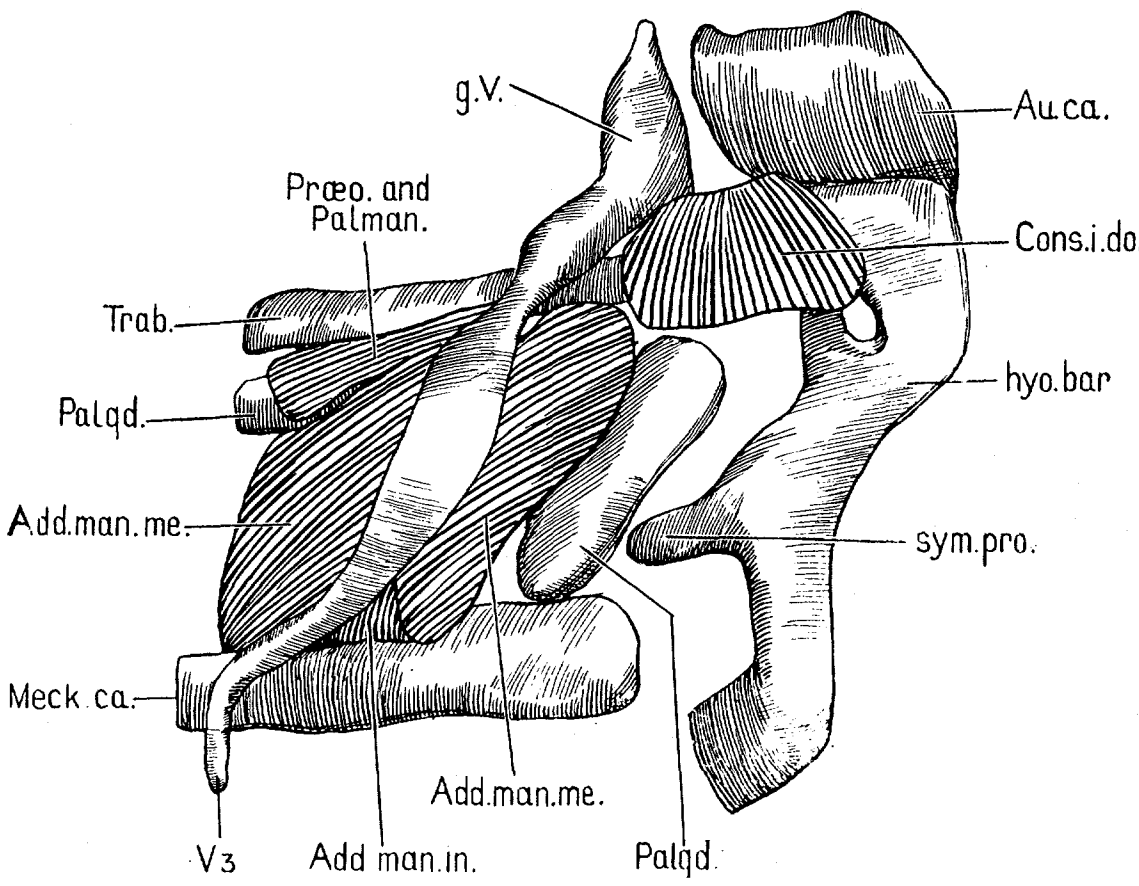

96

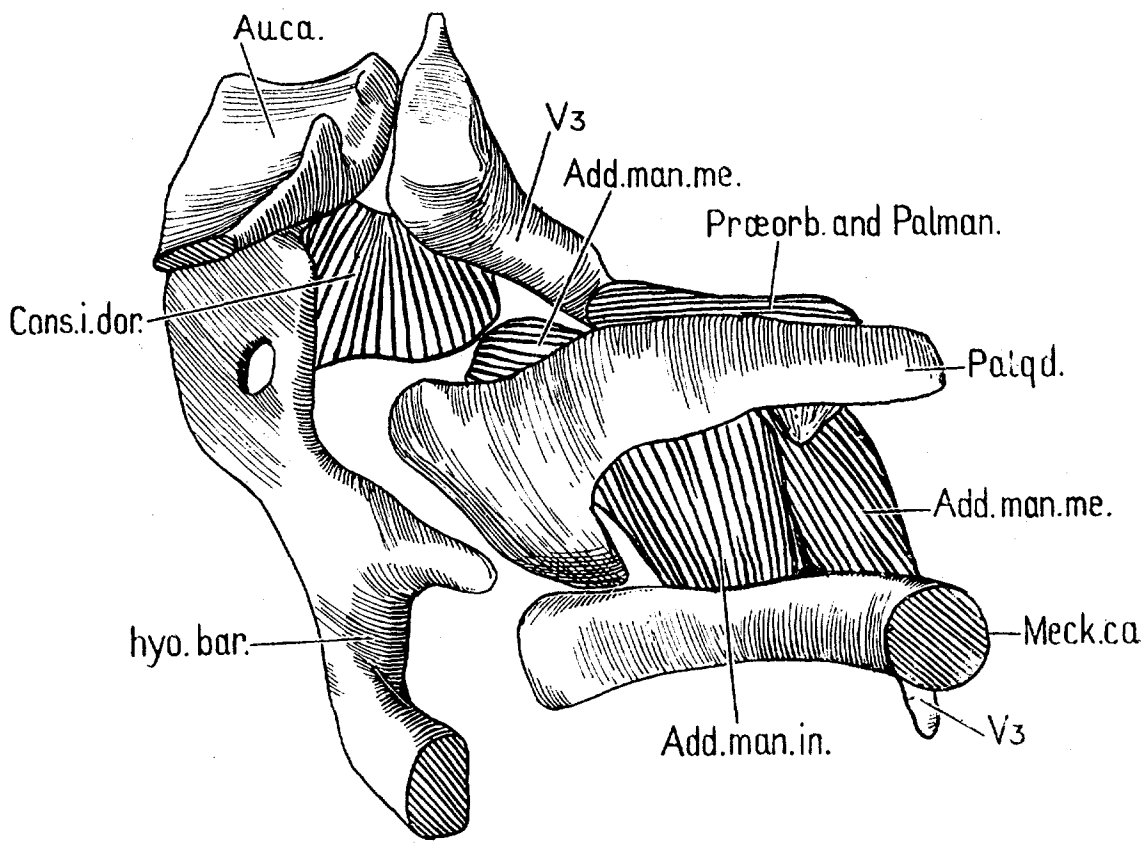

97

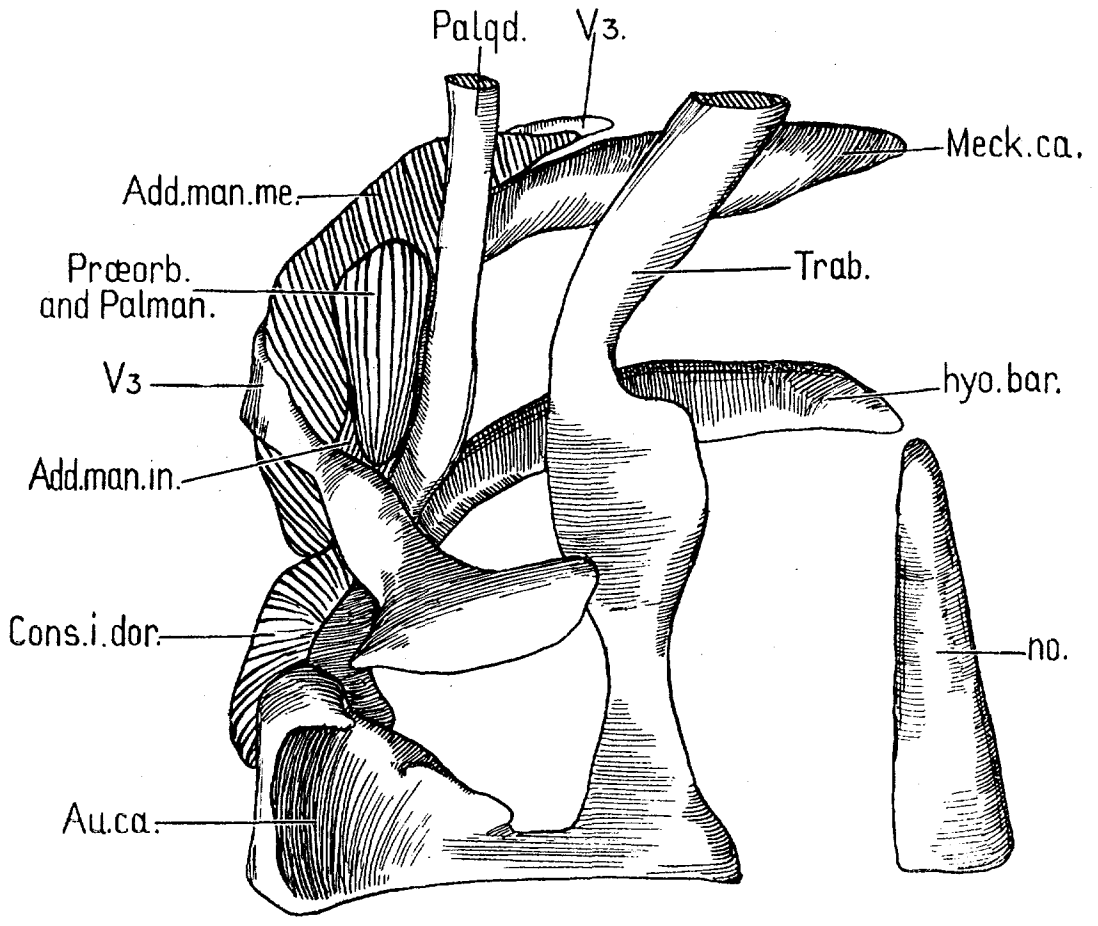

98

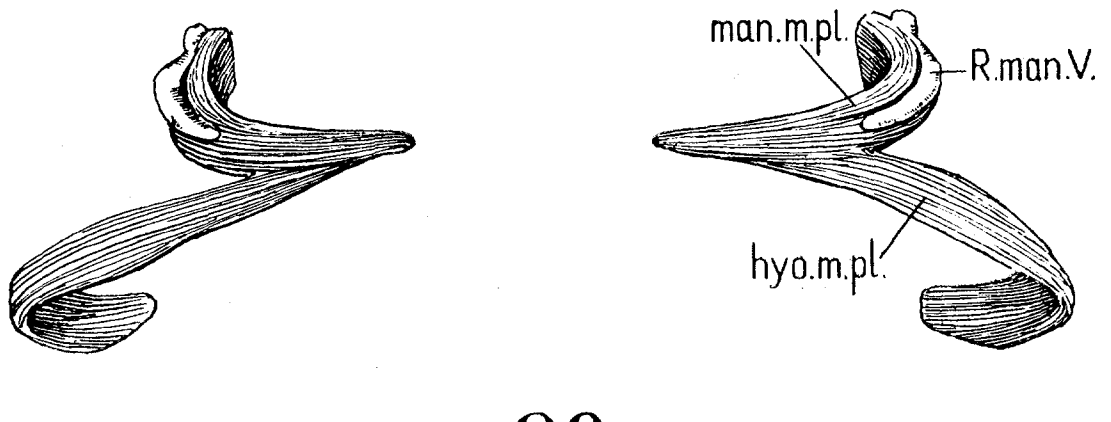

99

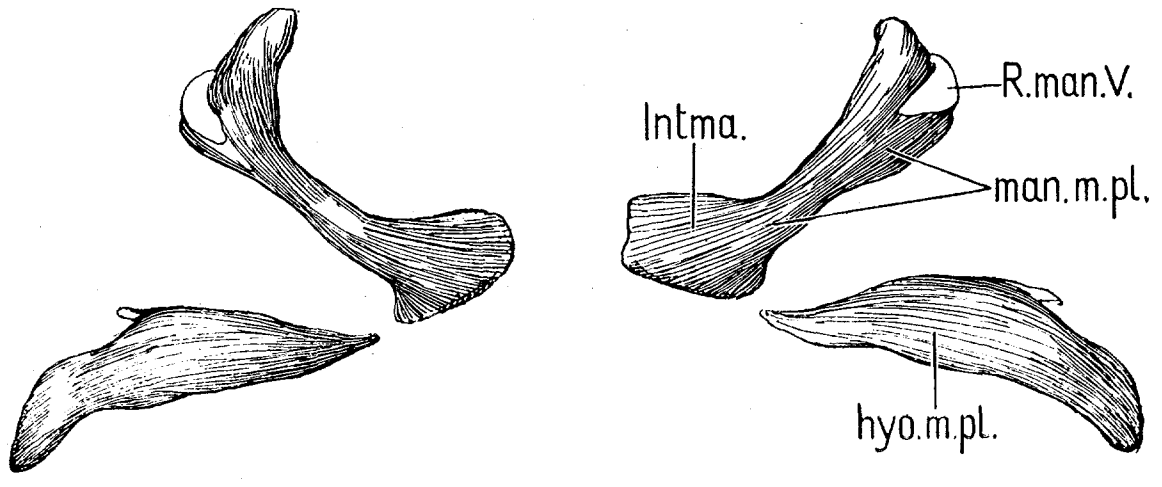

100

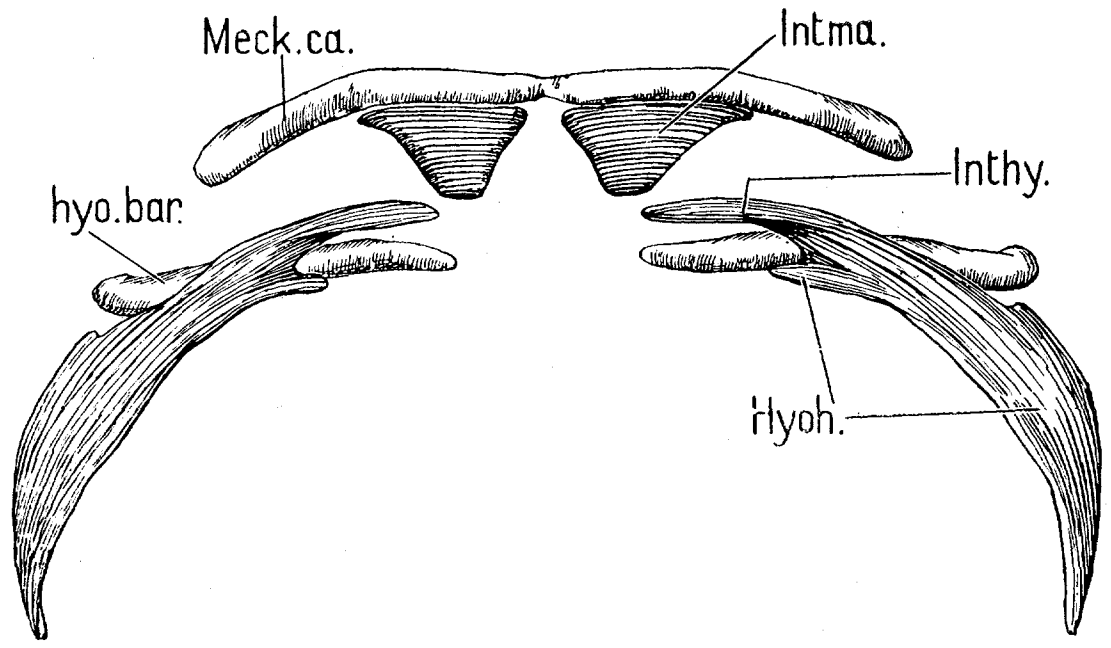

101

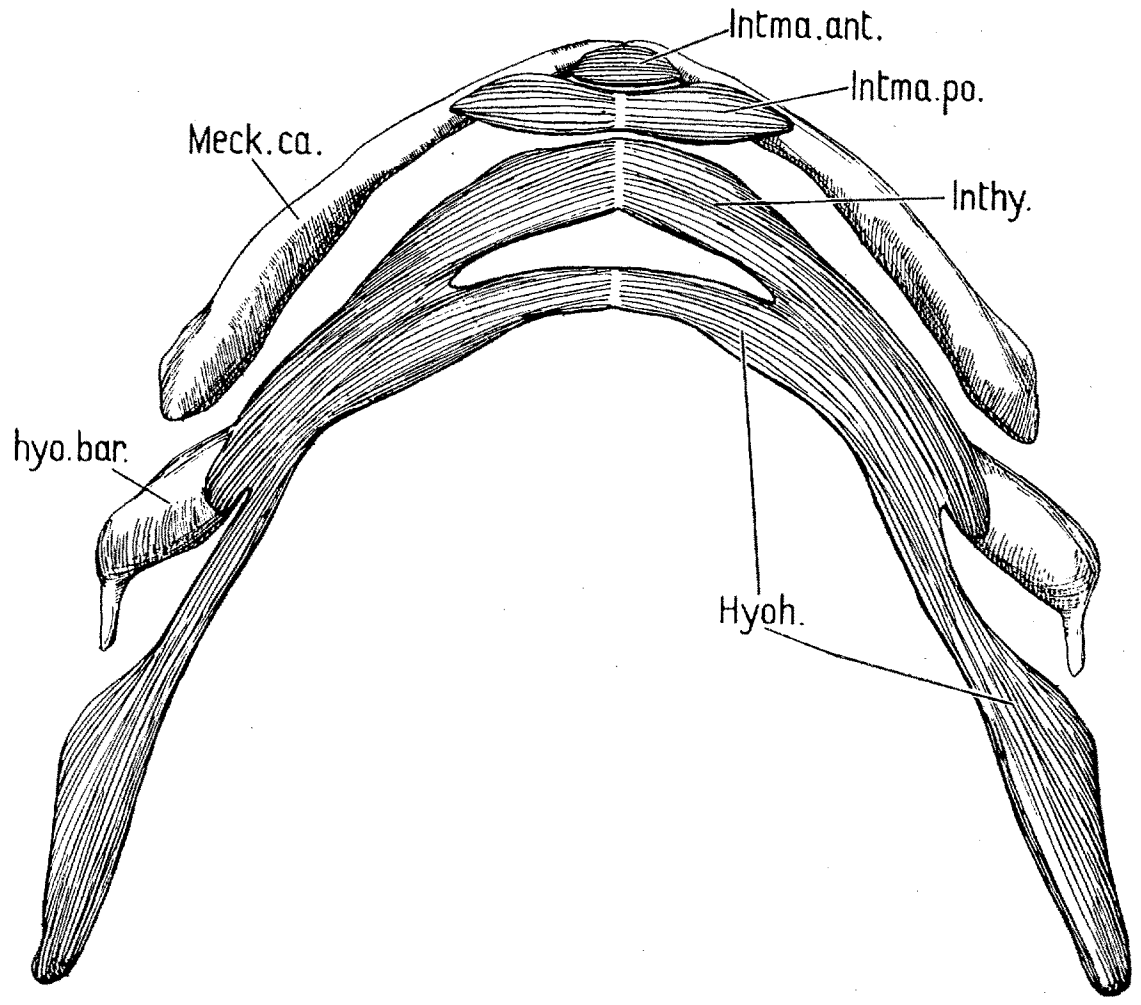

102

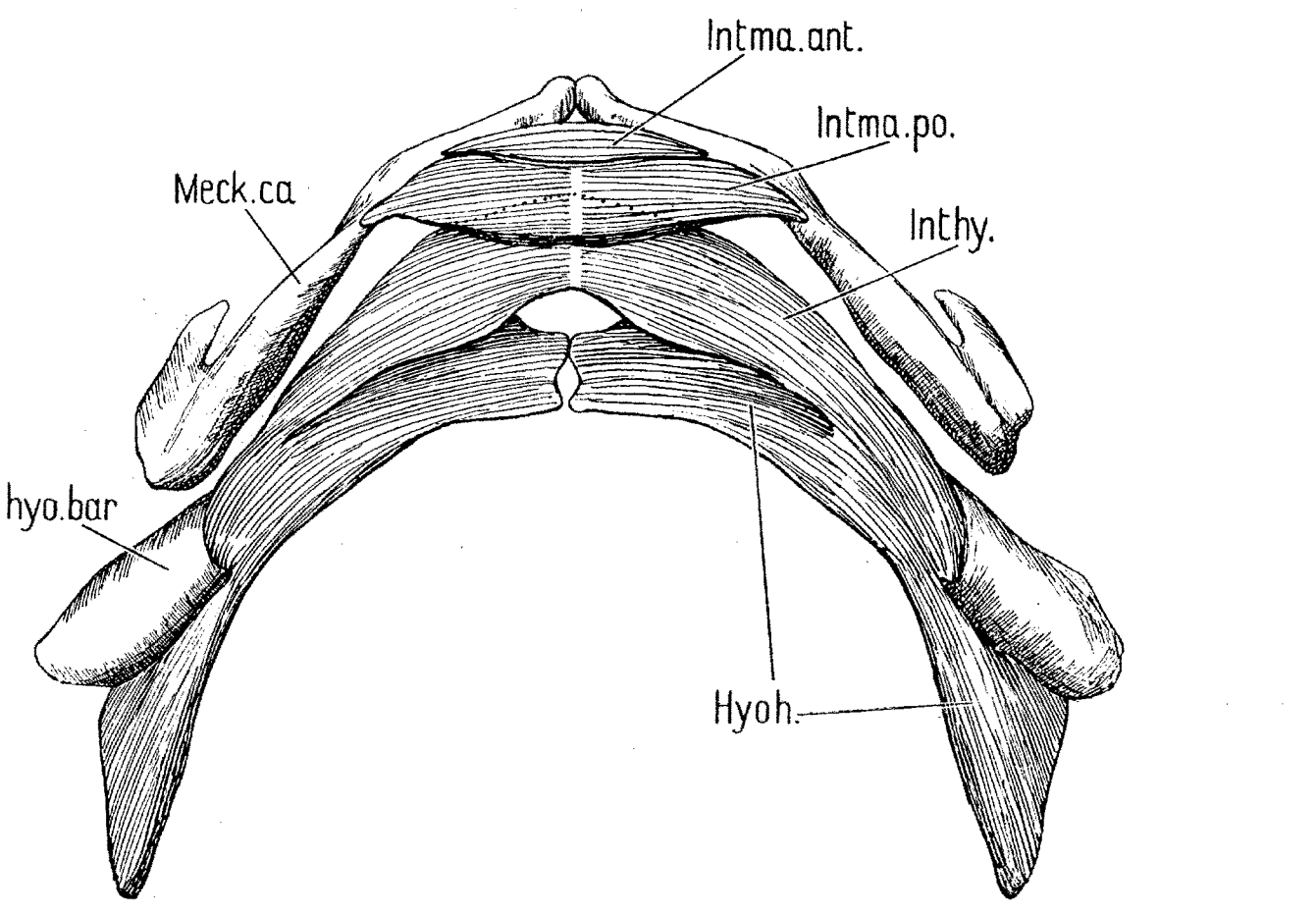

103

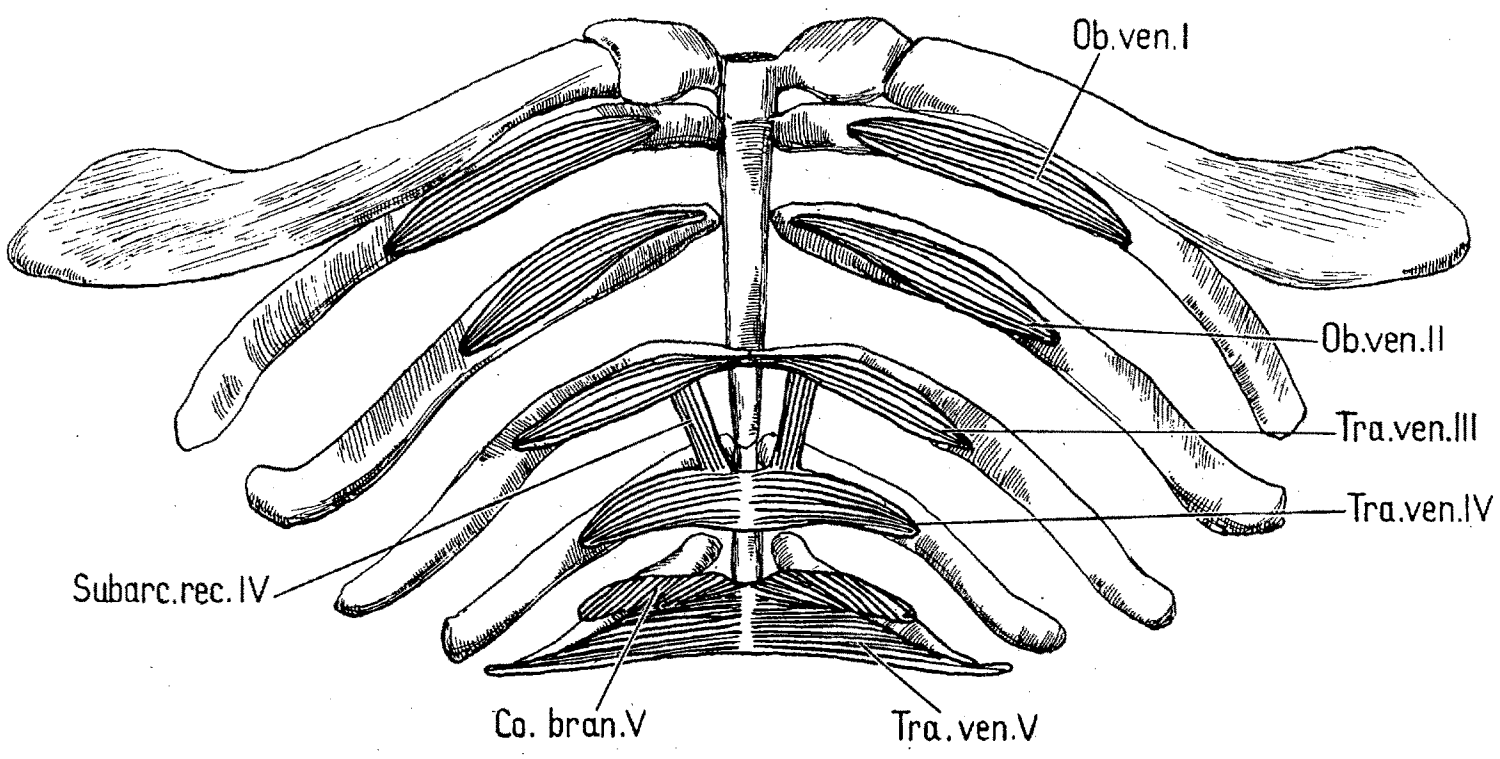

104

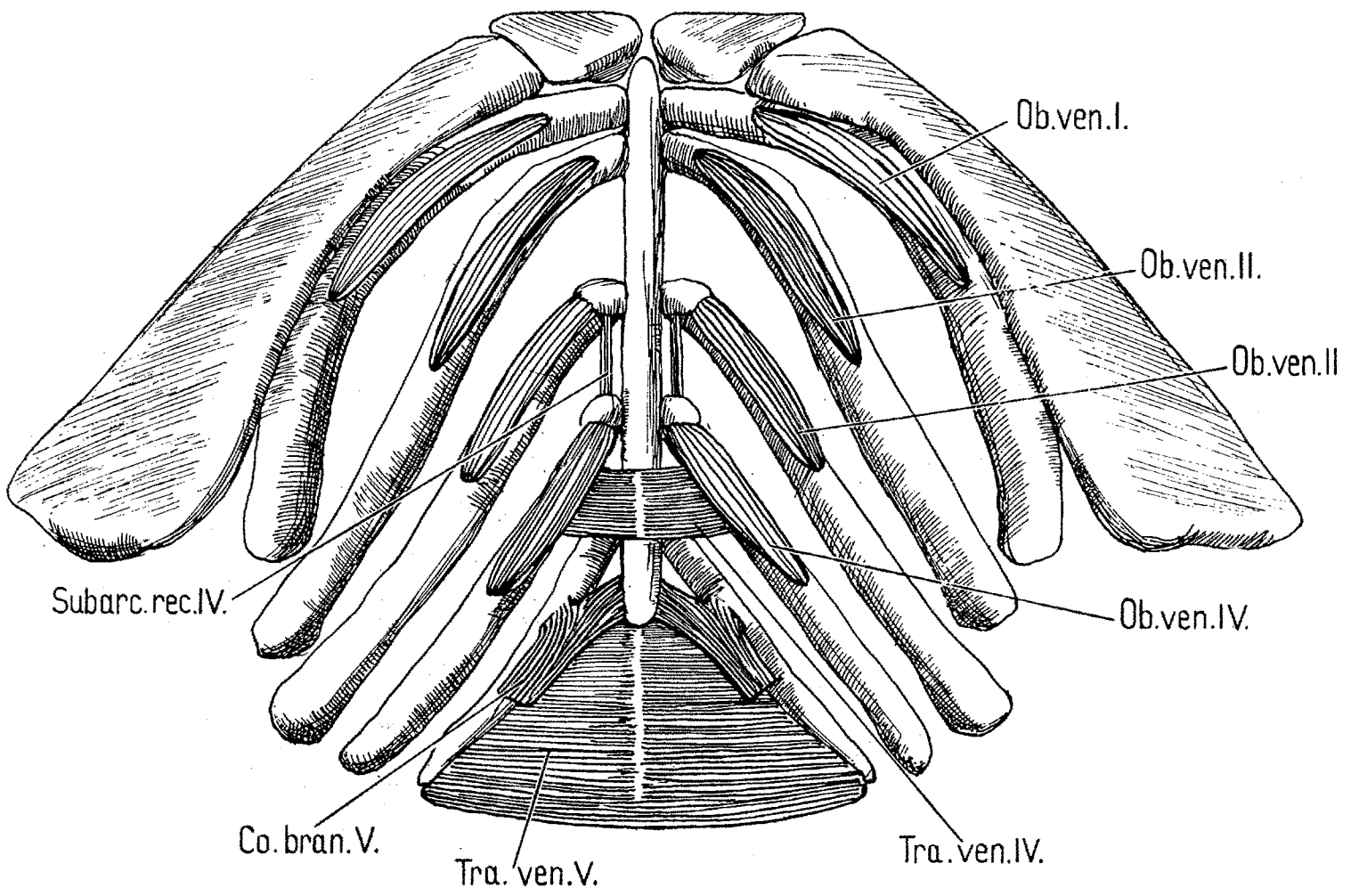

105

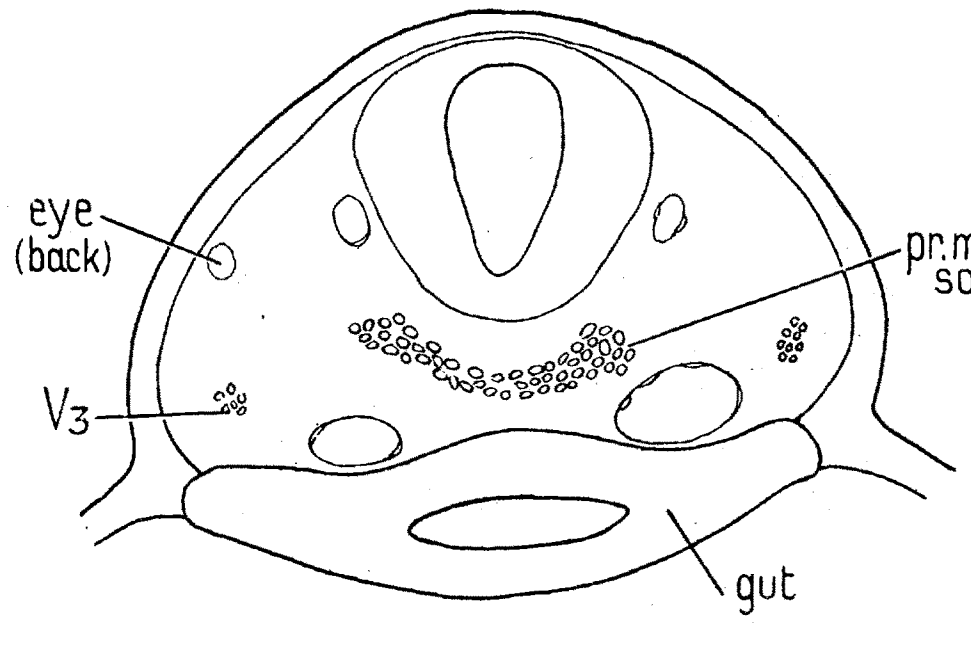

106

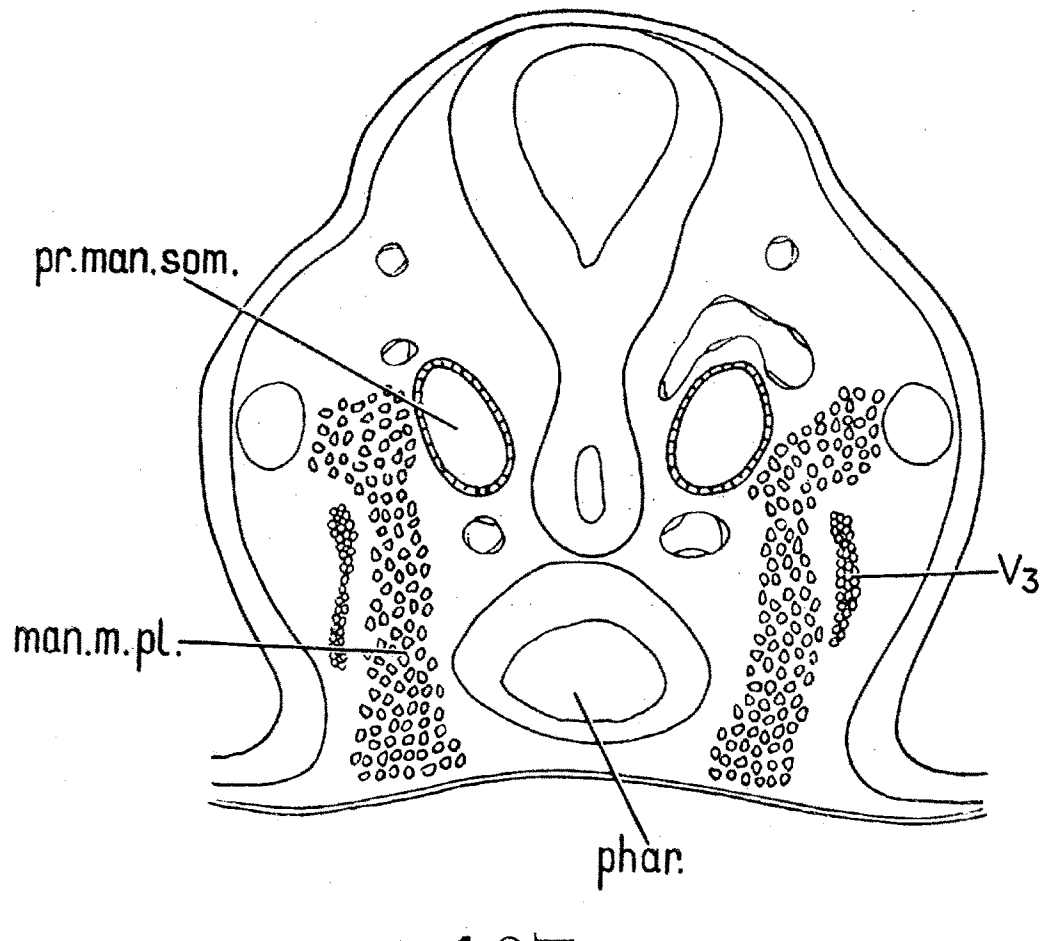

107

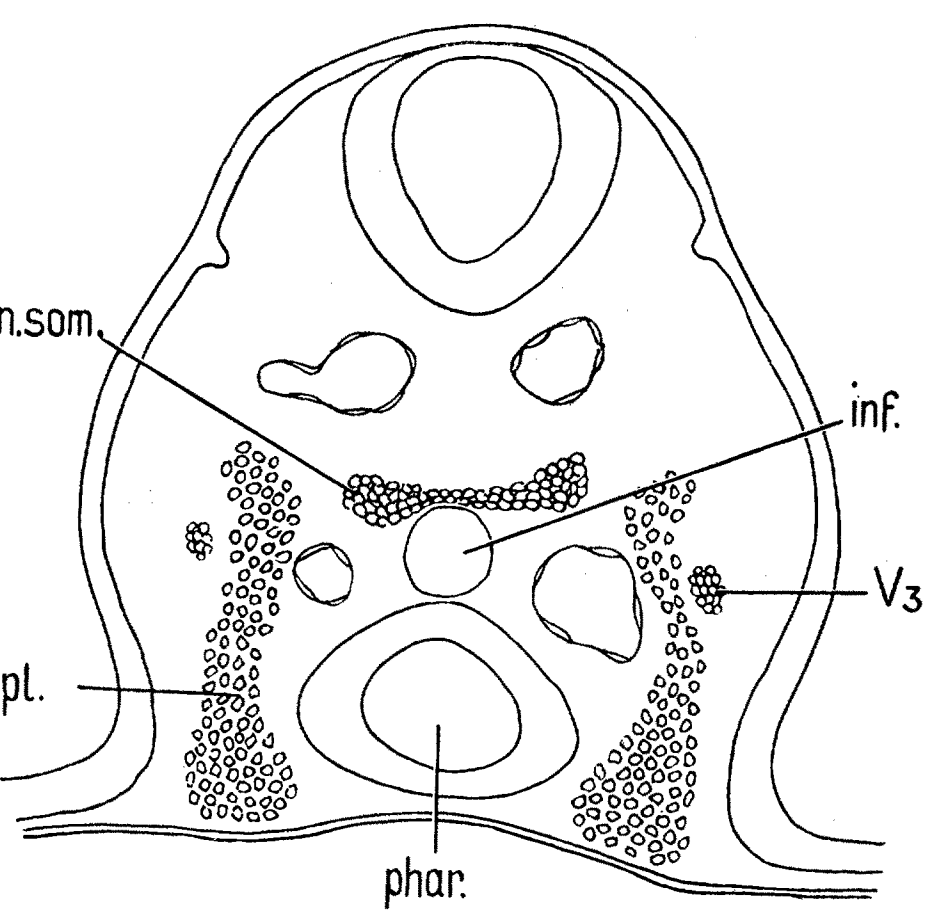

108

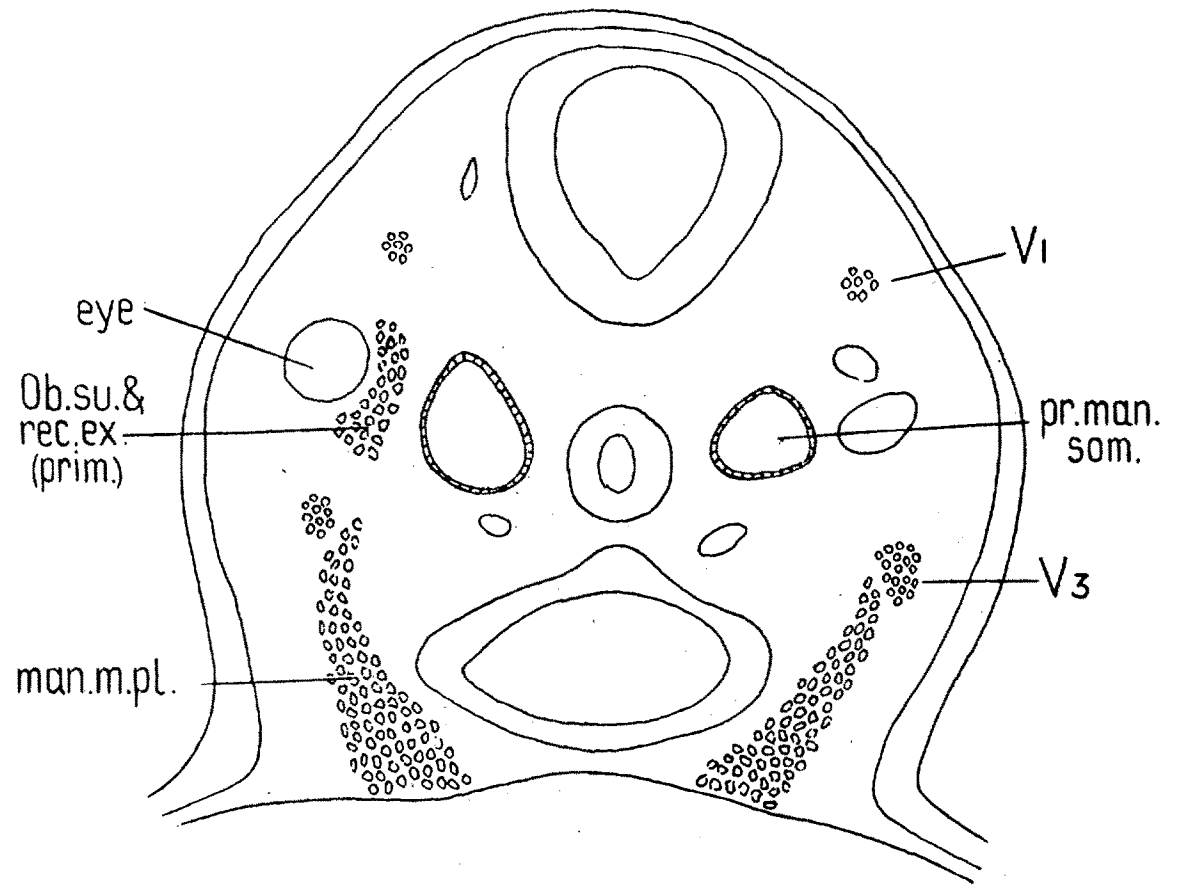

109

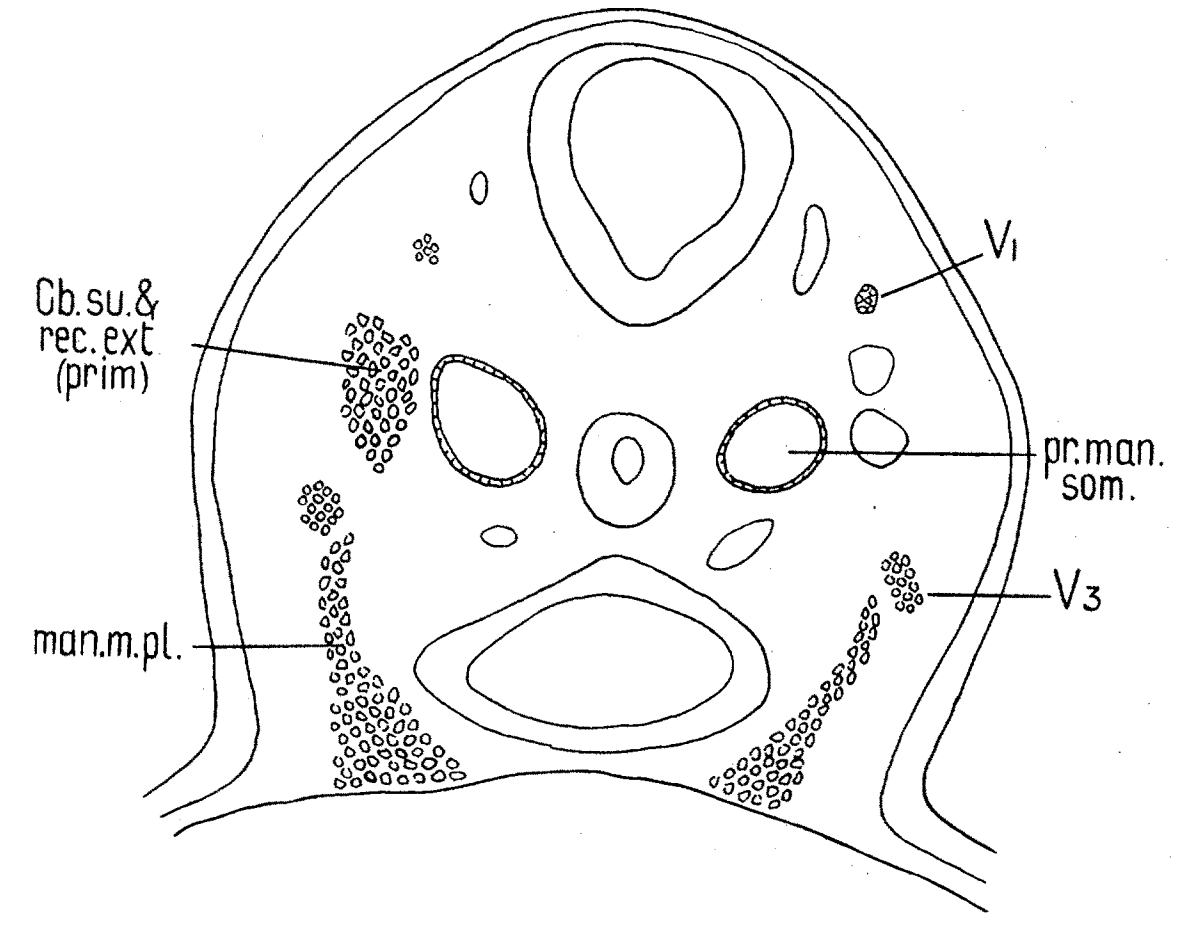

110

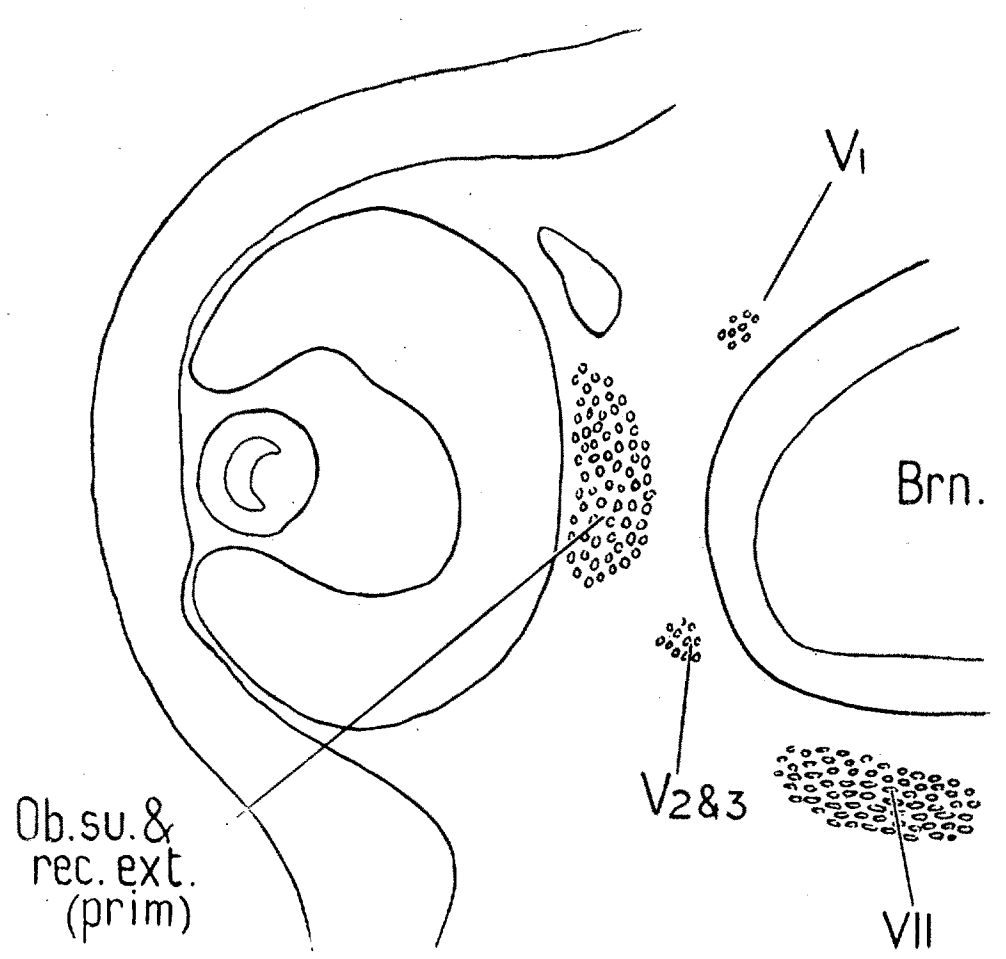

111

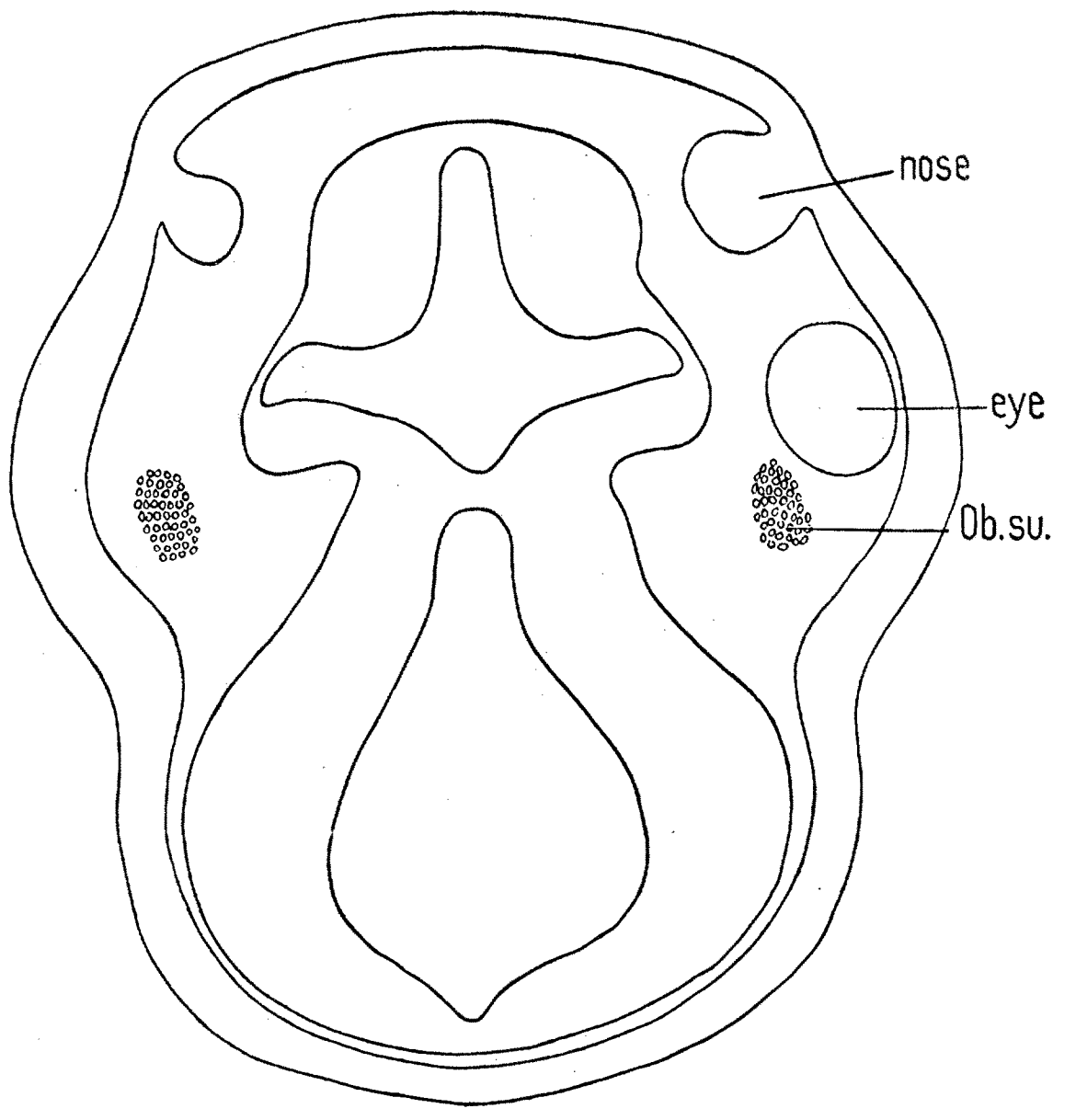

112

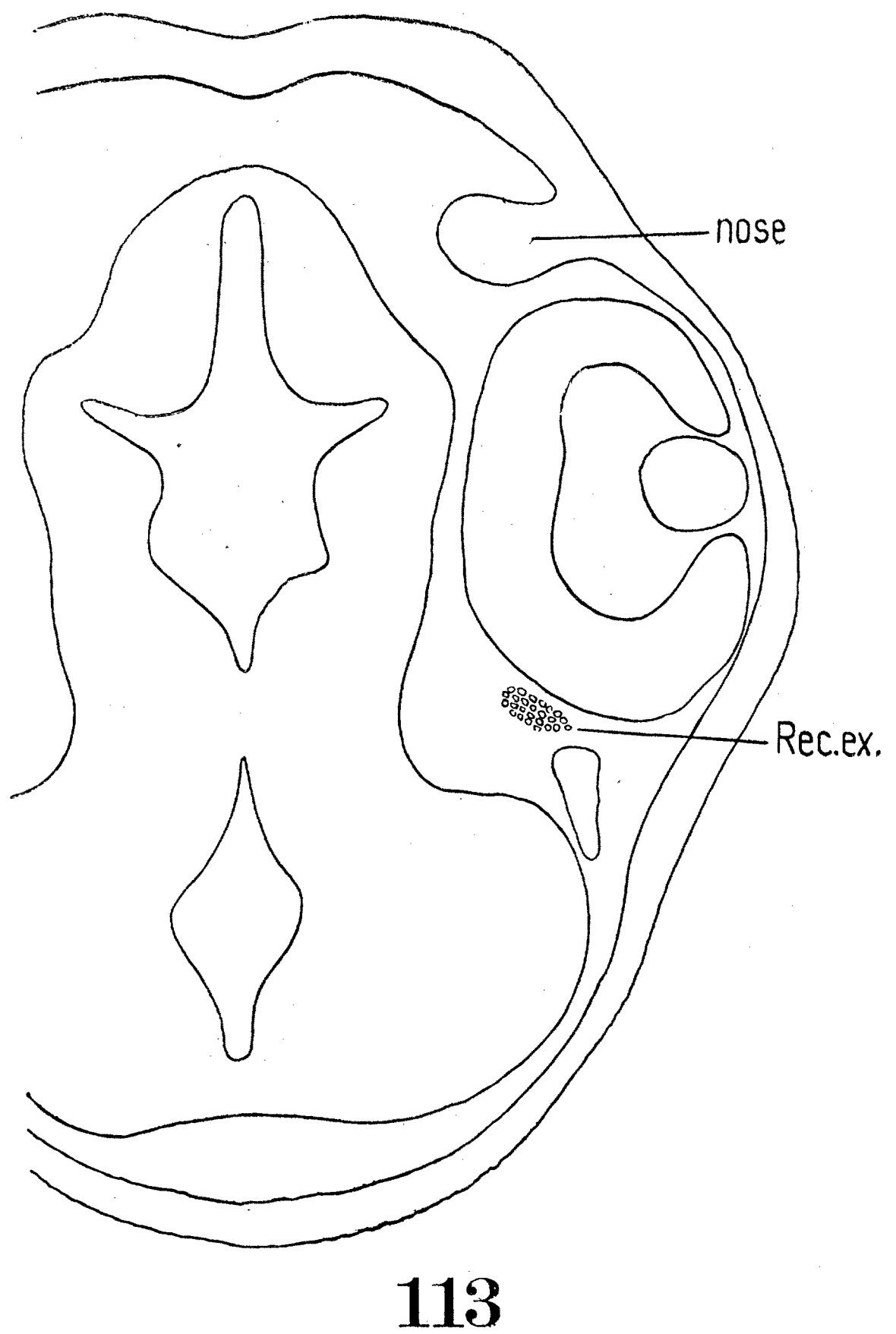

113

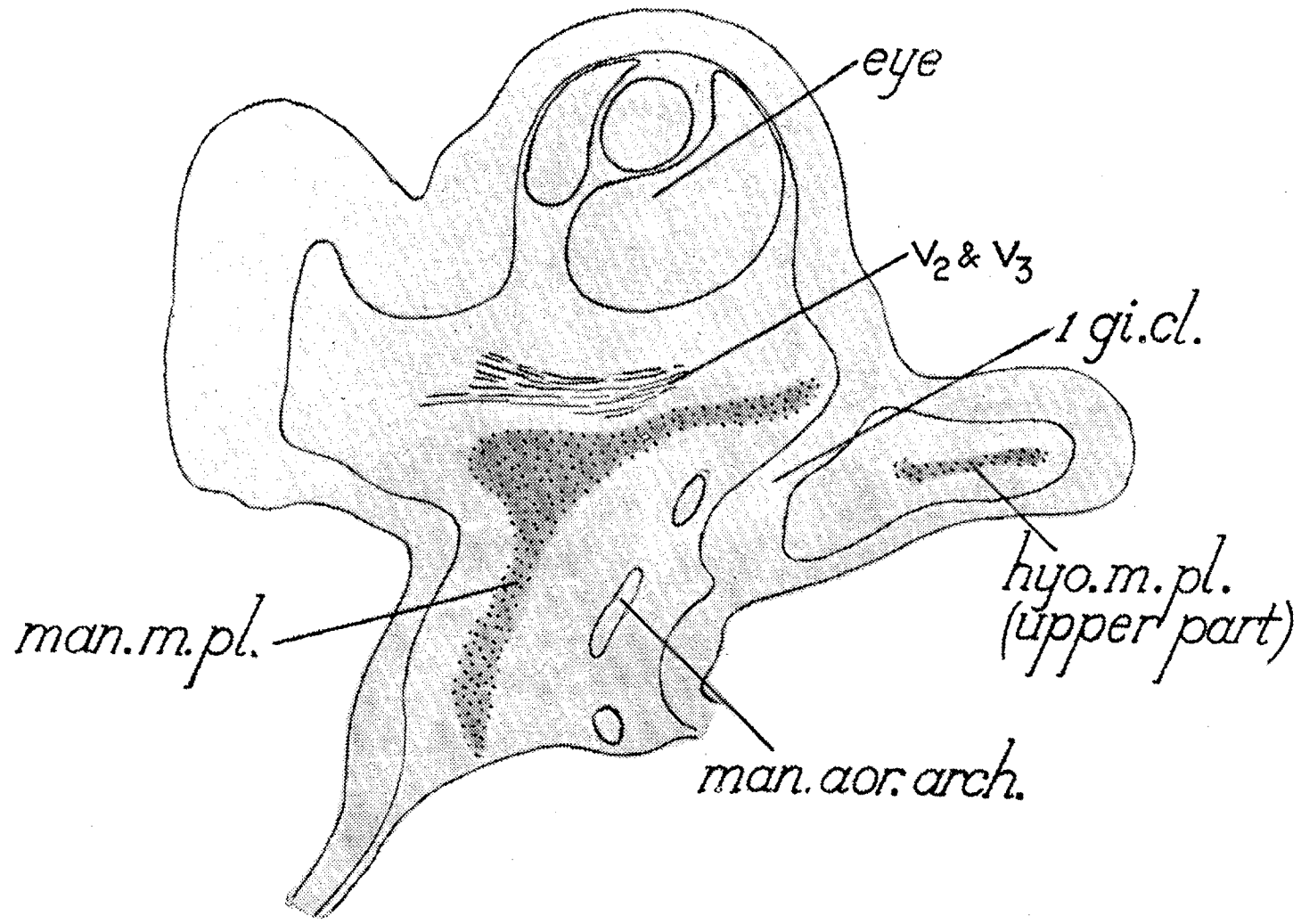

114

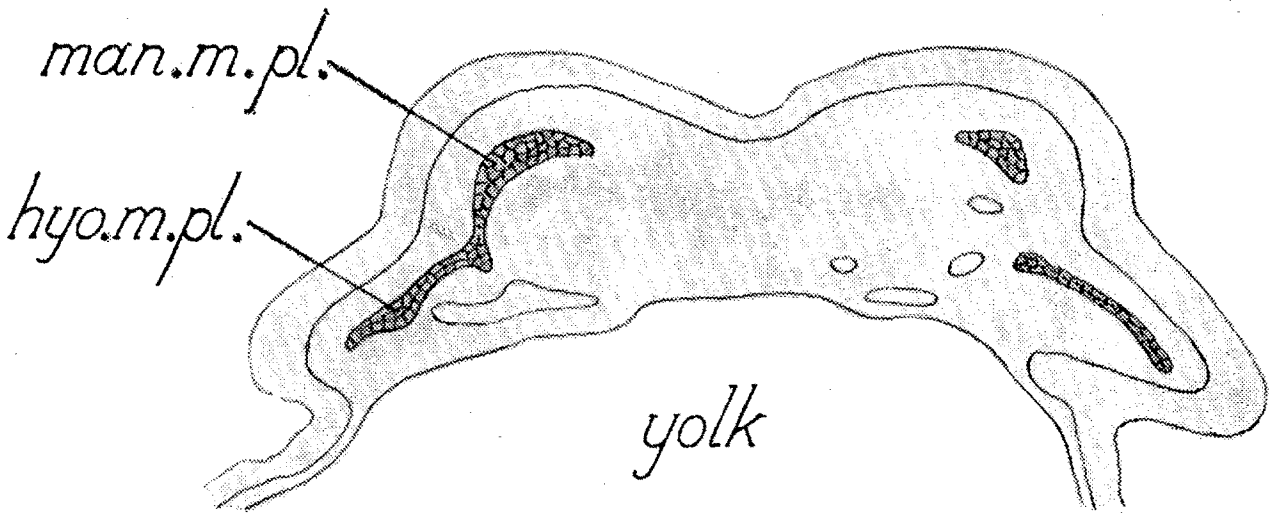

115

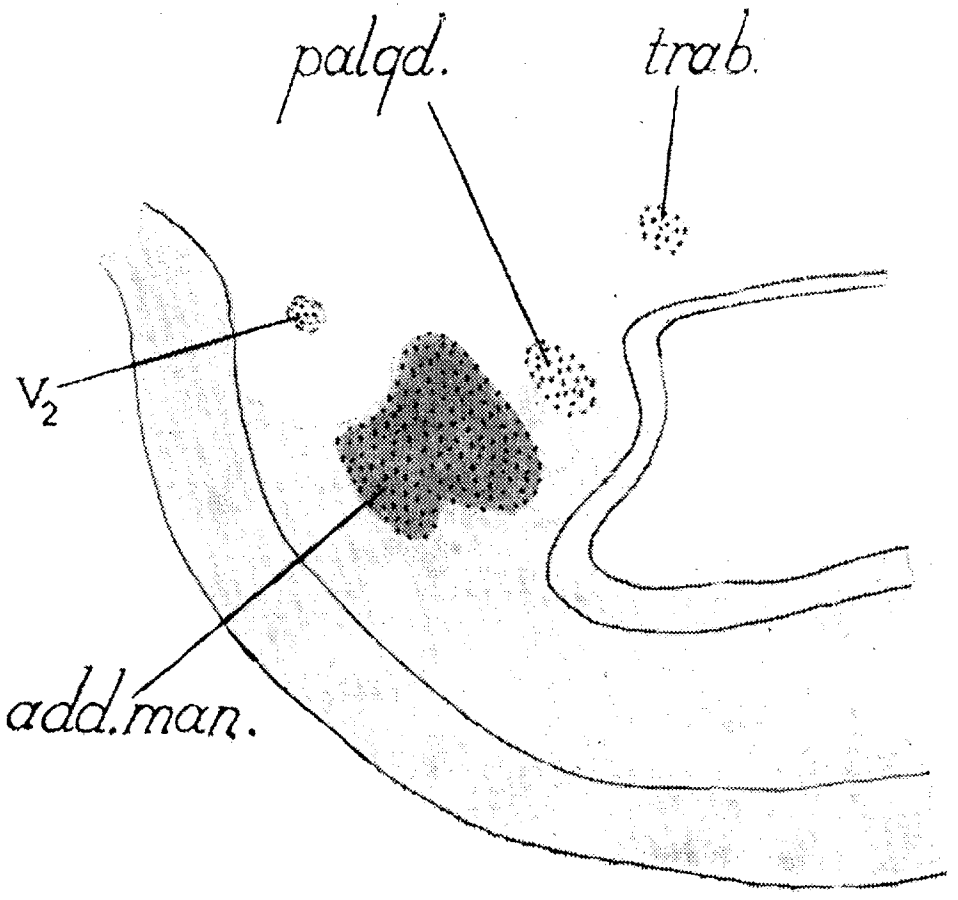

116

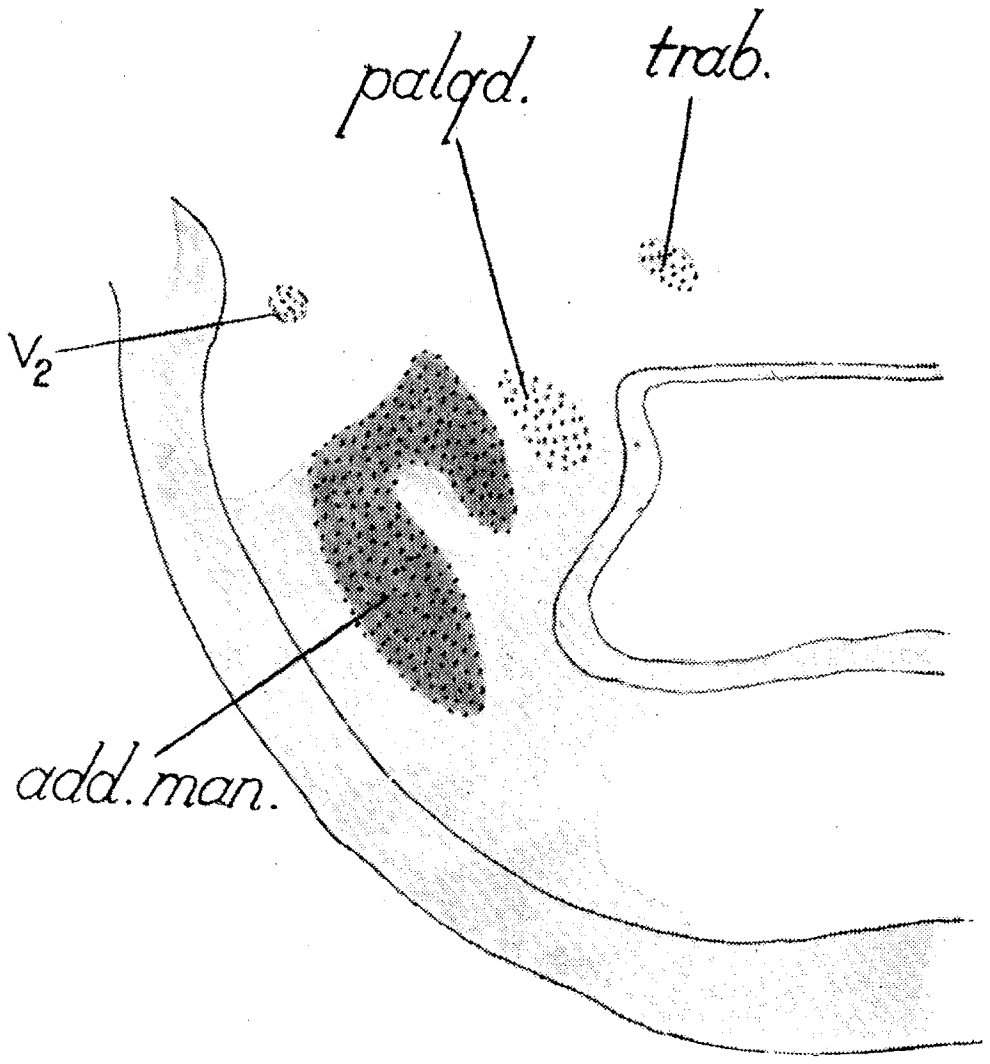

117

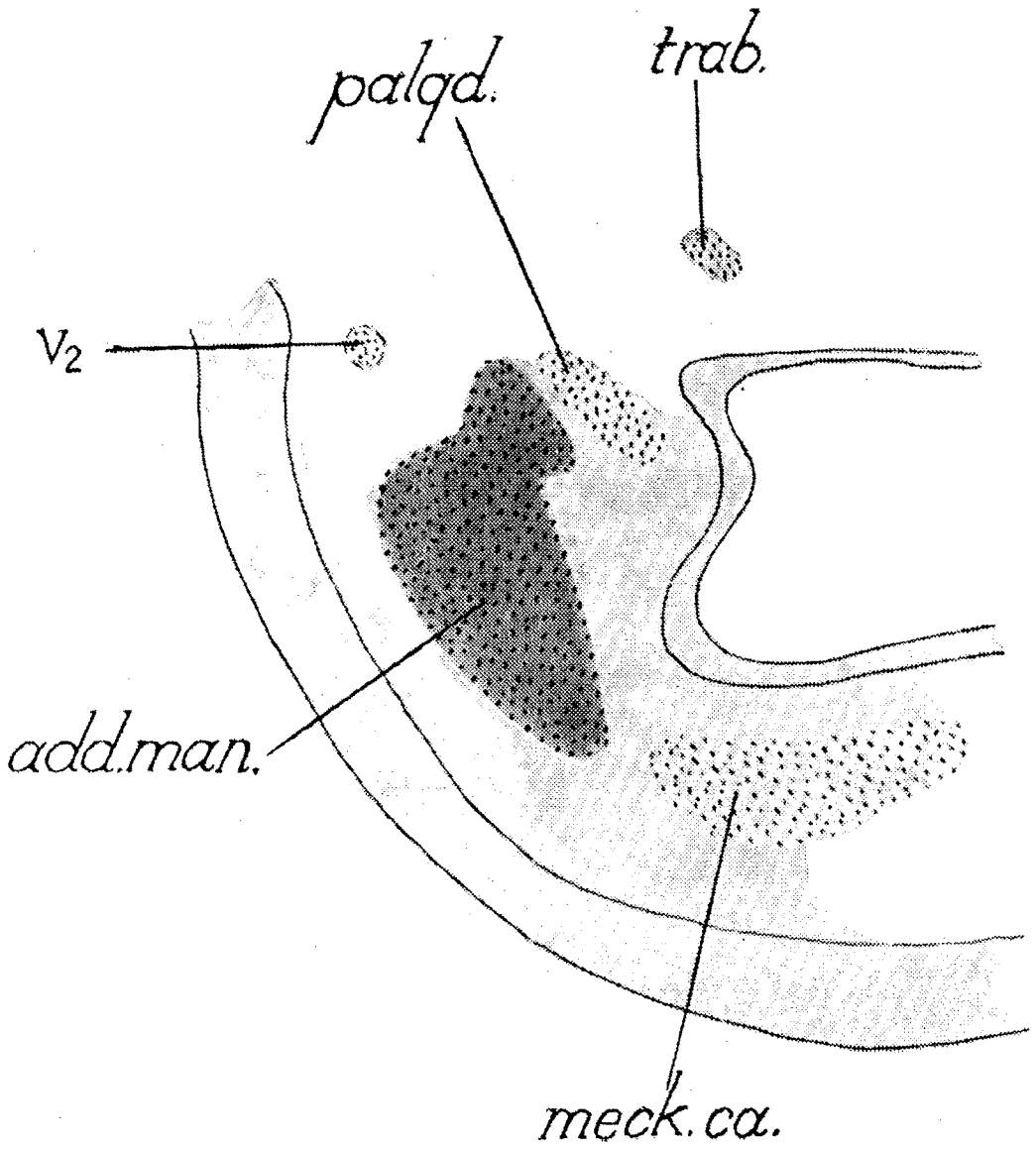

118

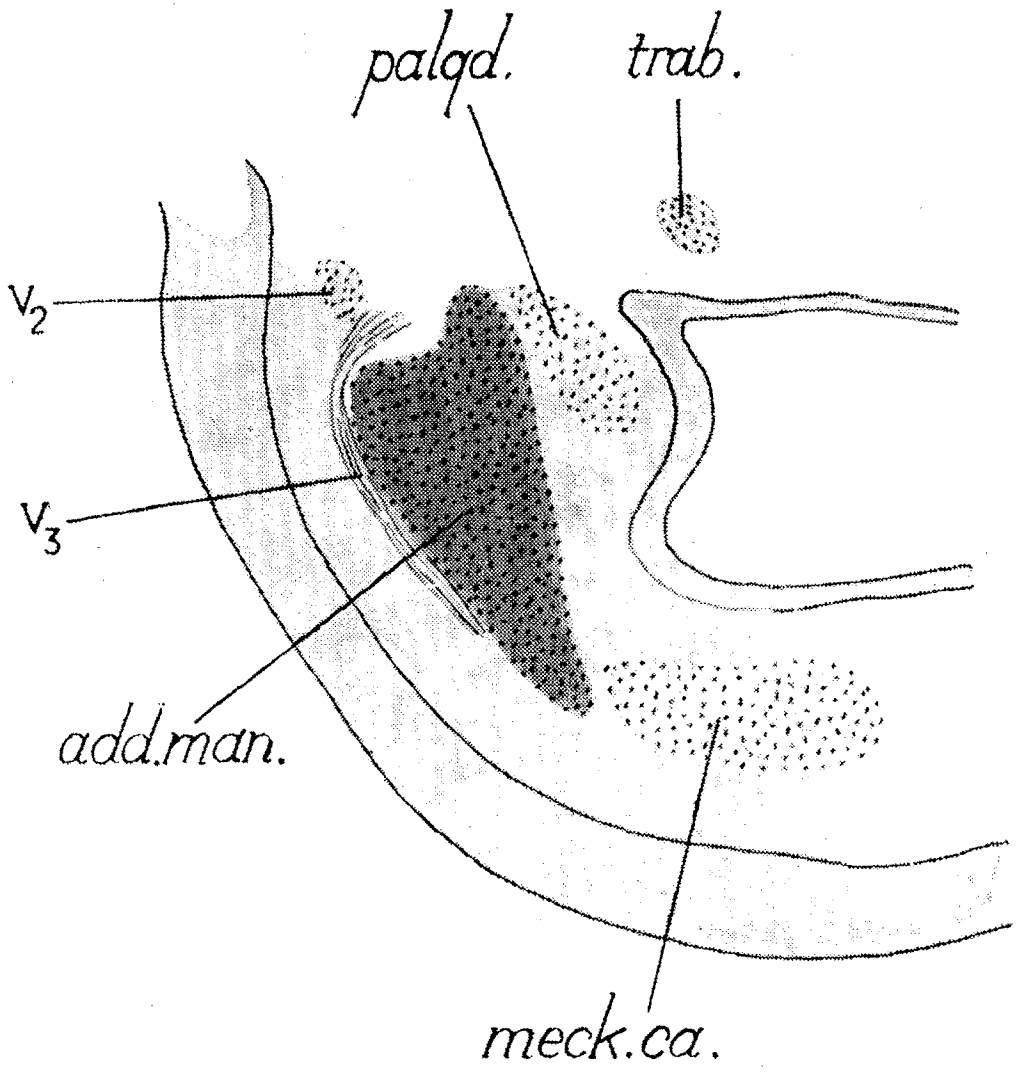

119

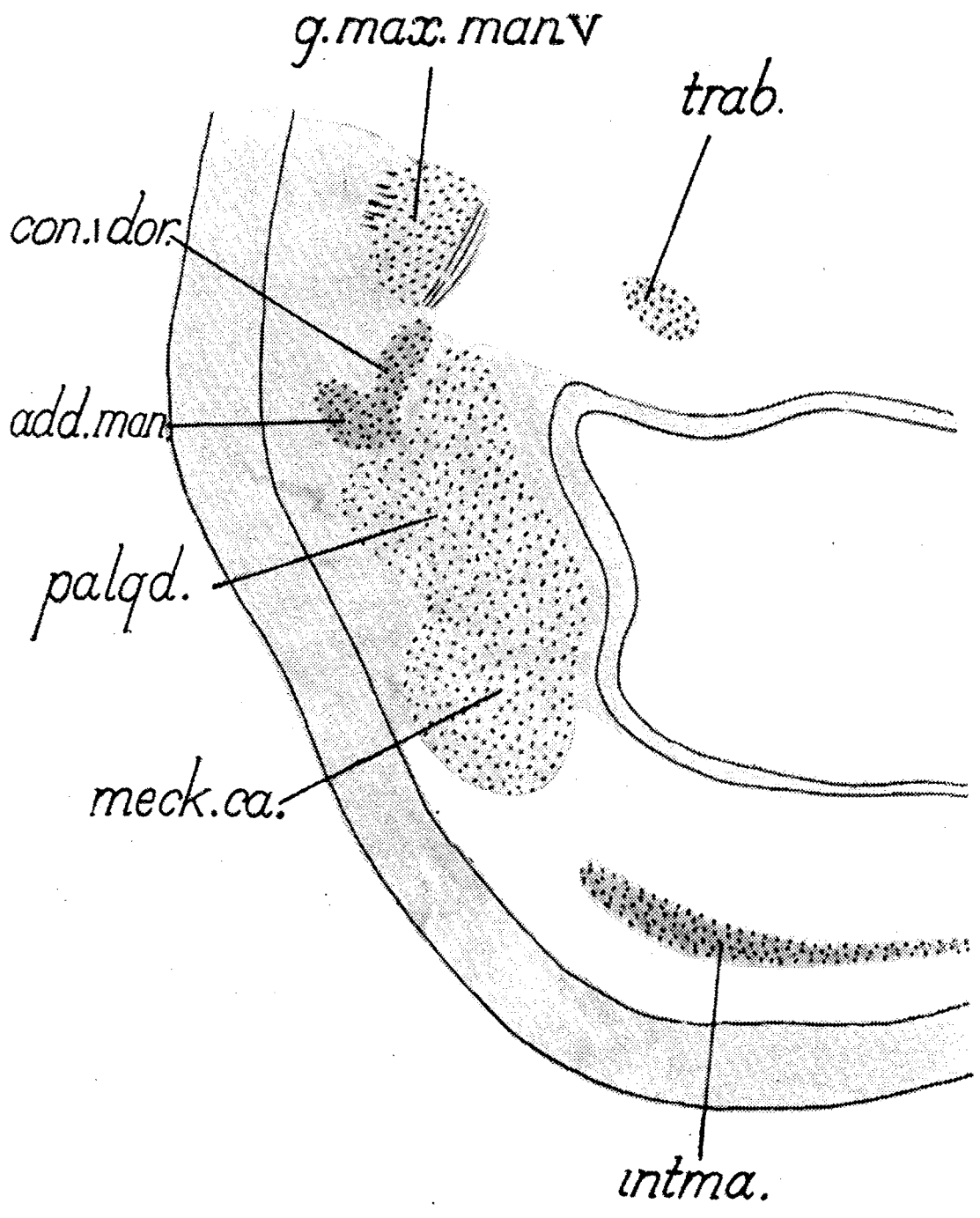

120

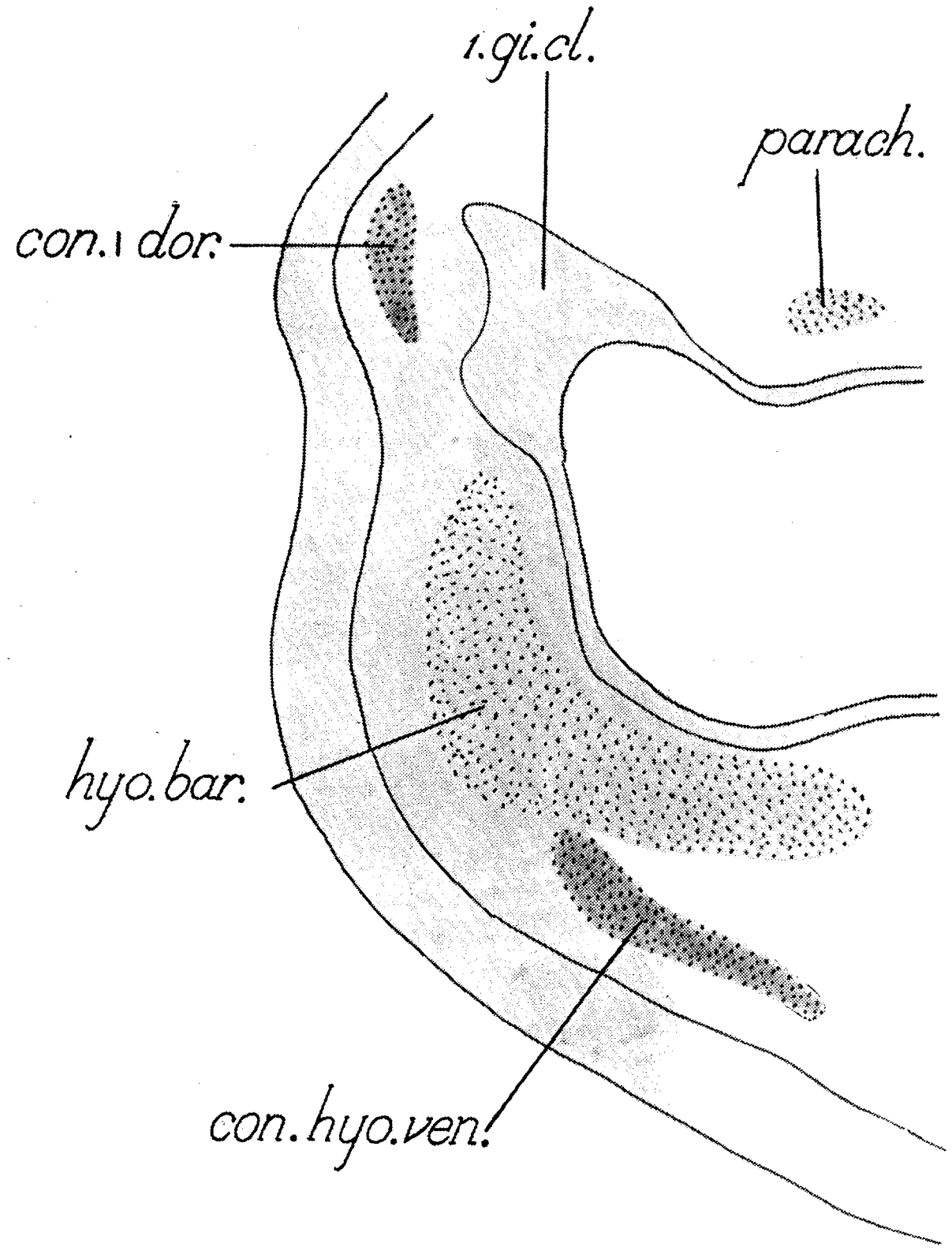

121

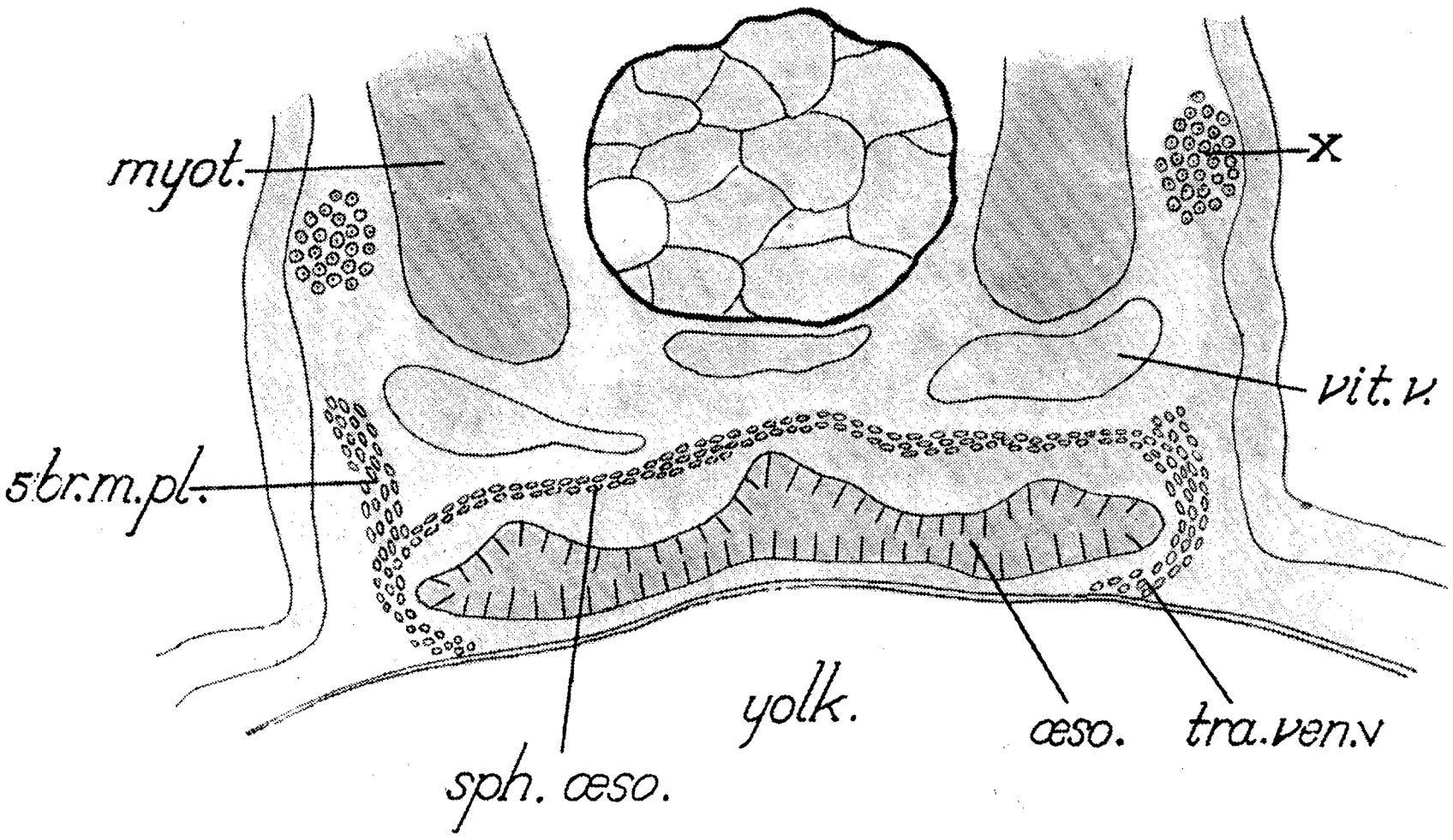

122

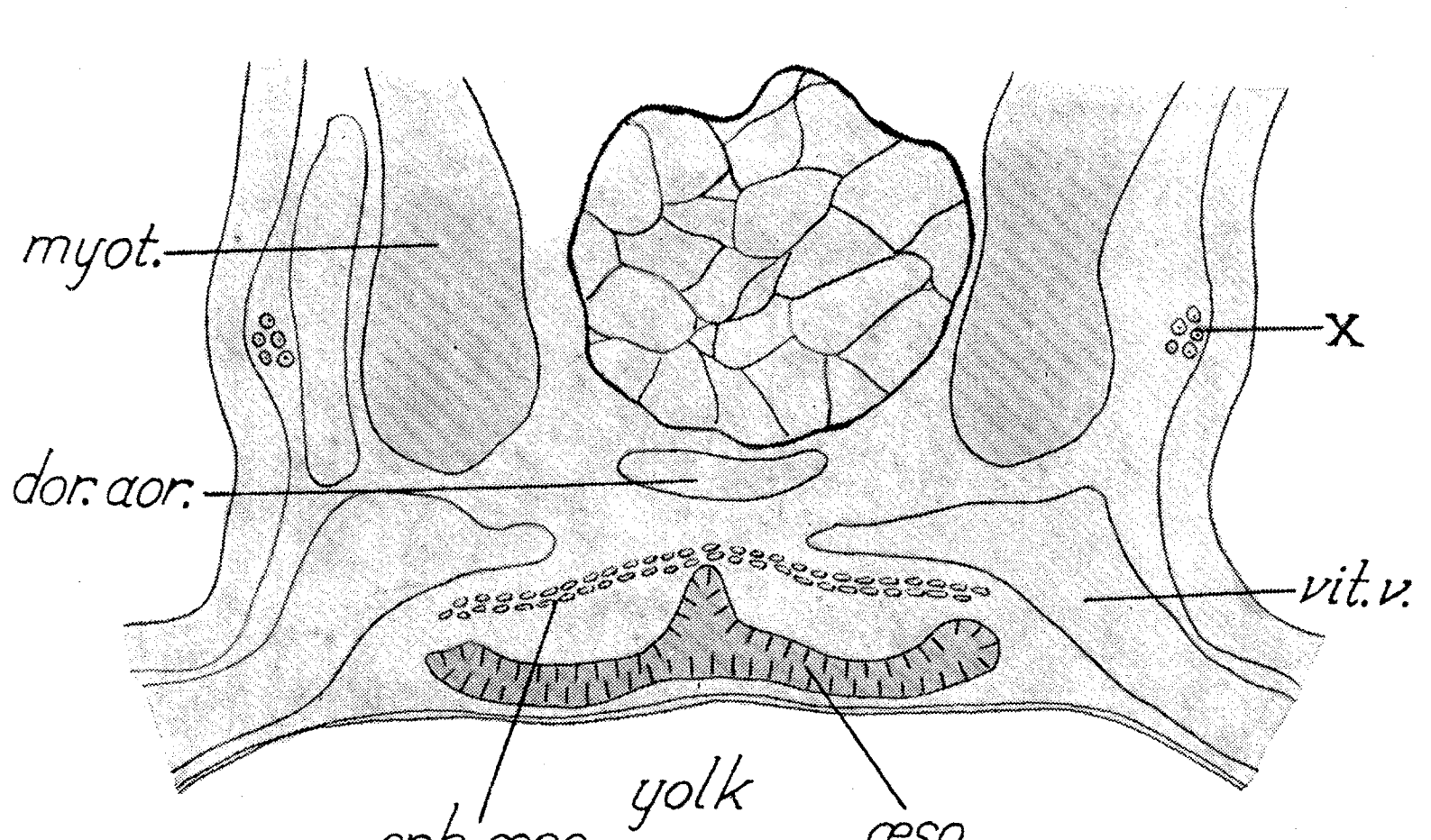

123

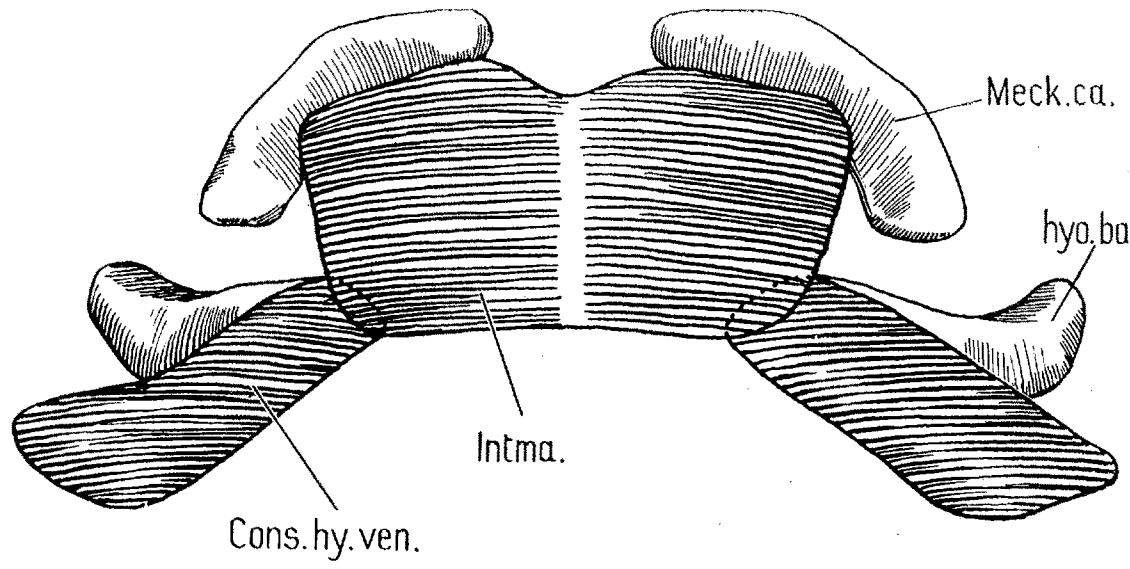

124

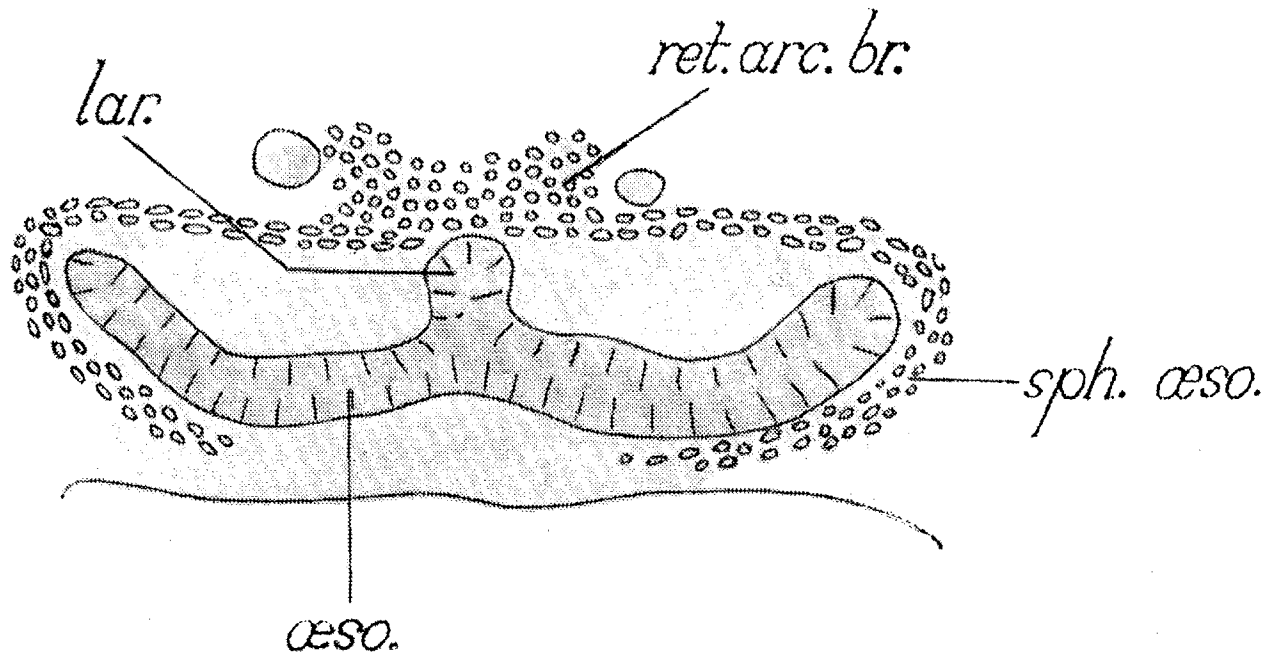

125

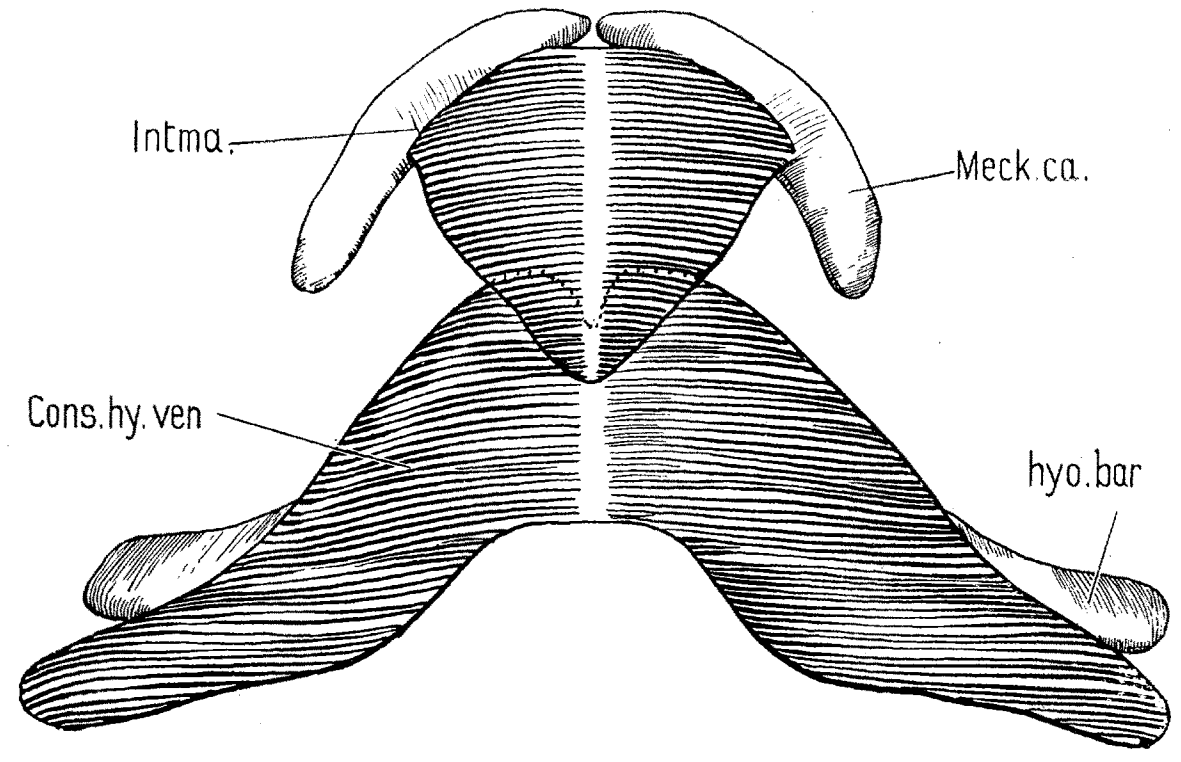

126

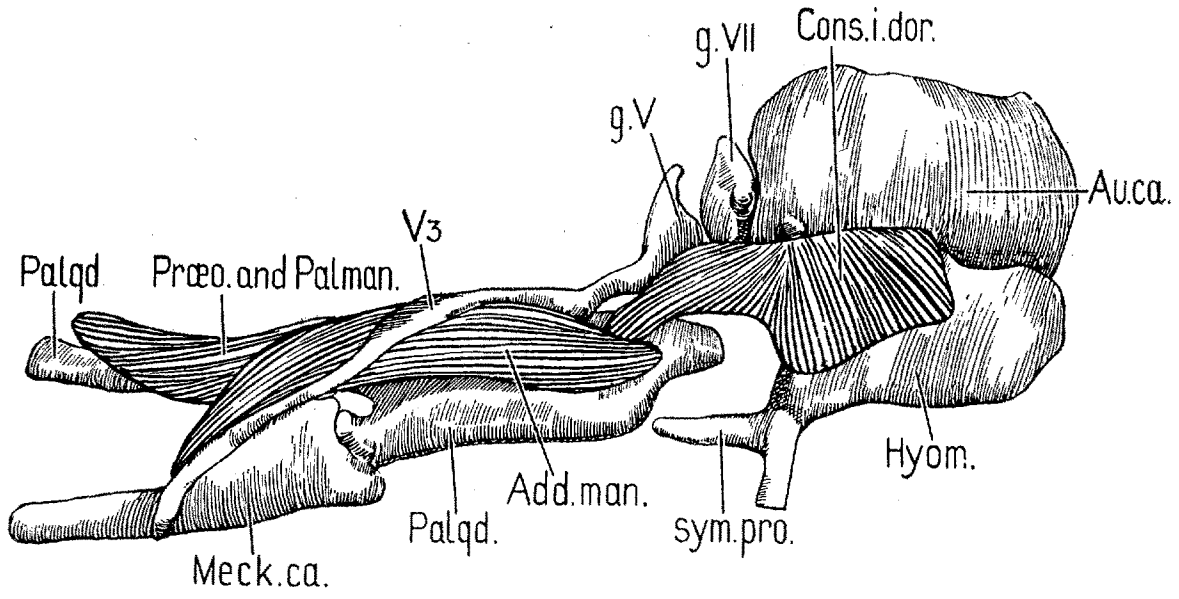

127

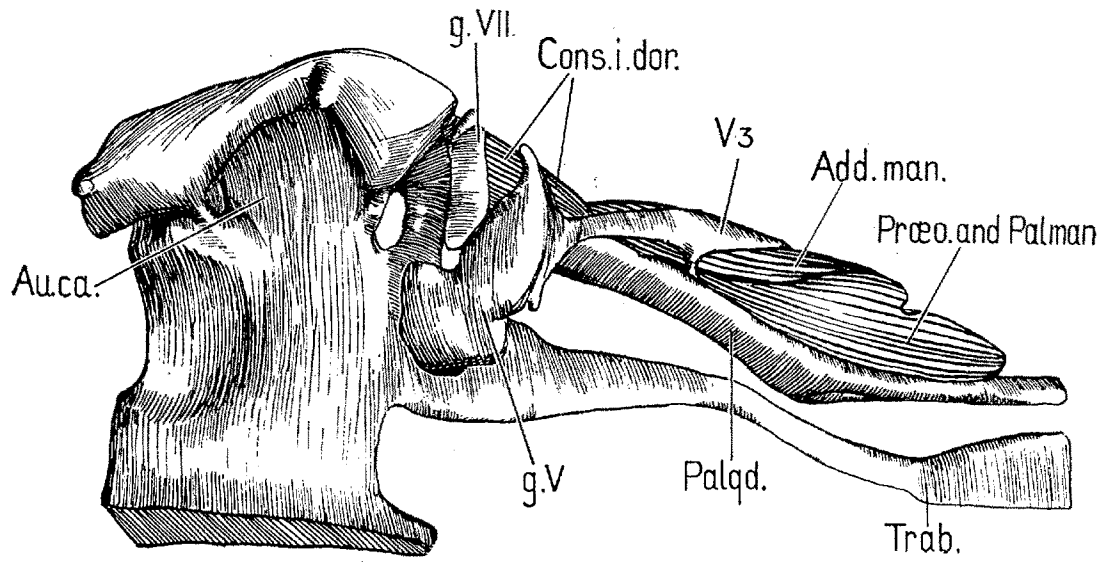

128

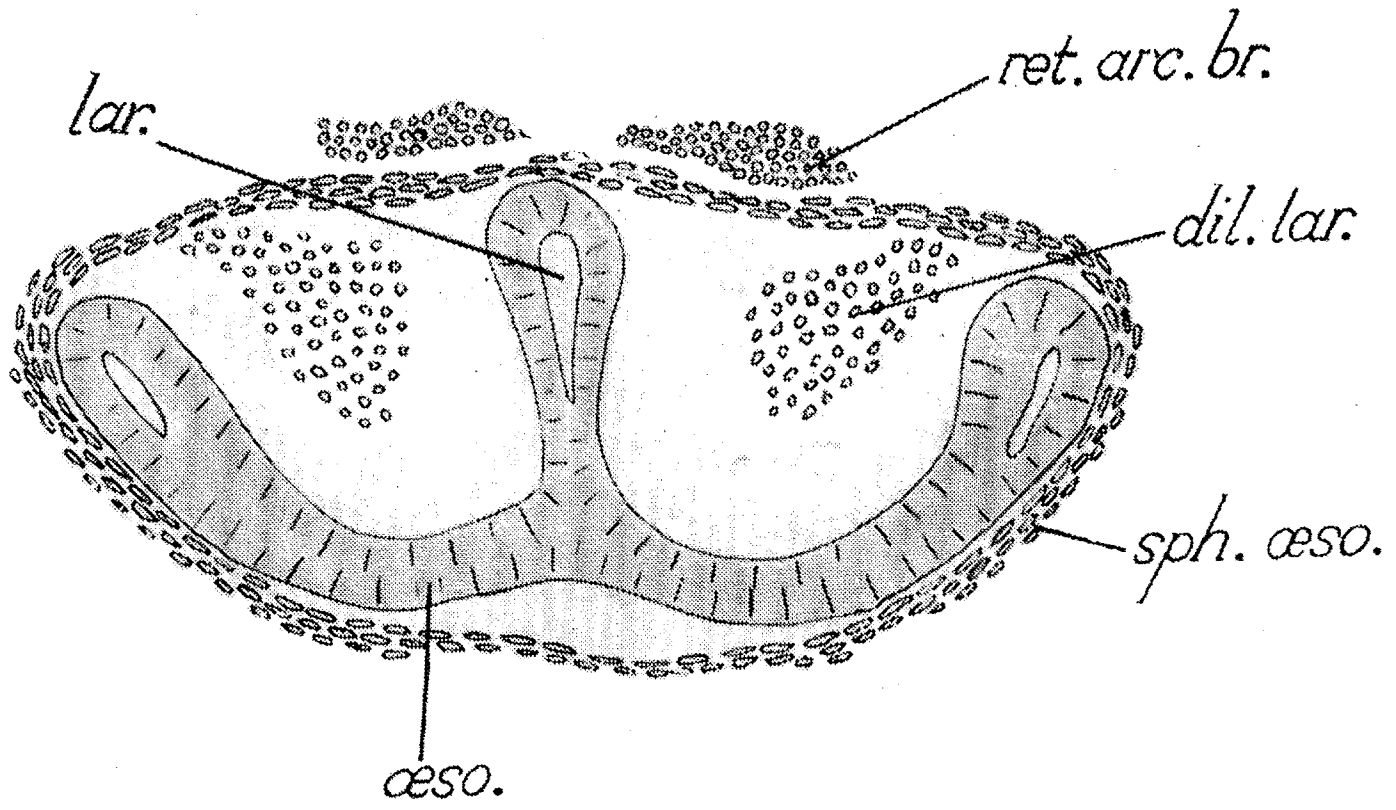

129

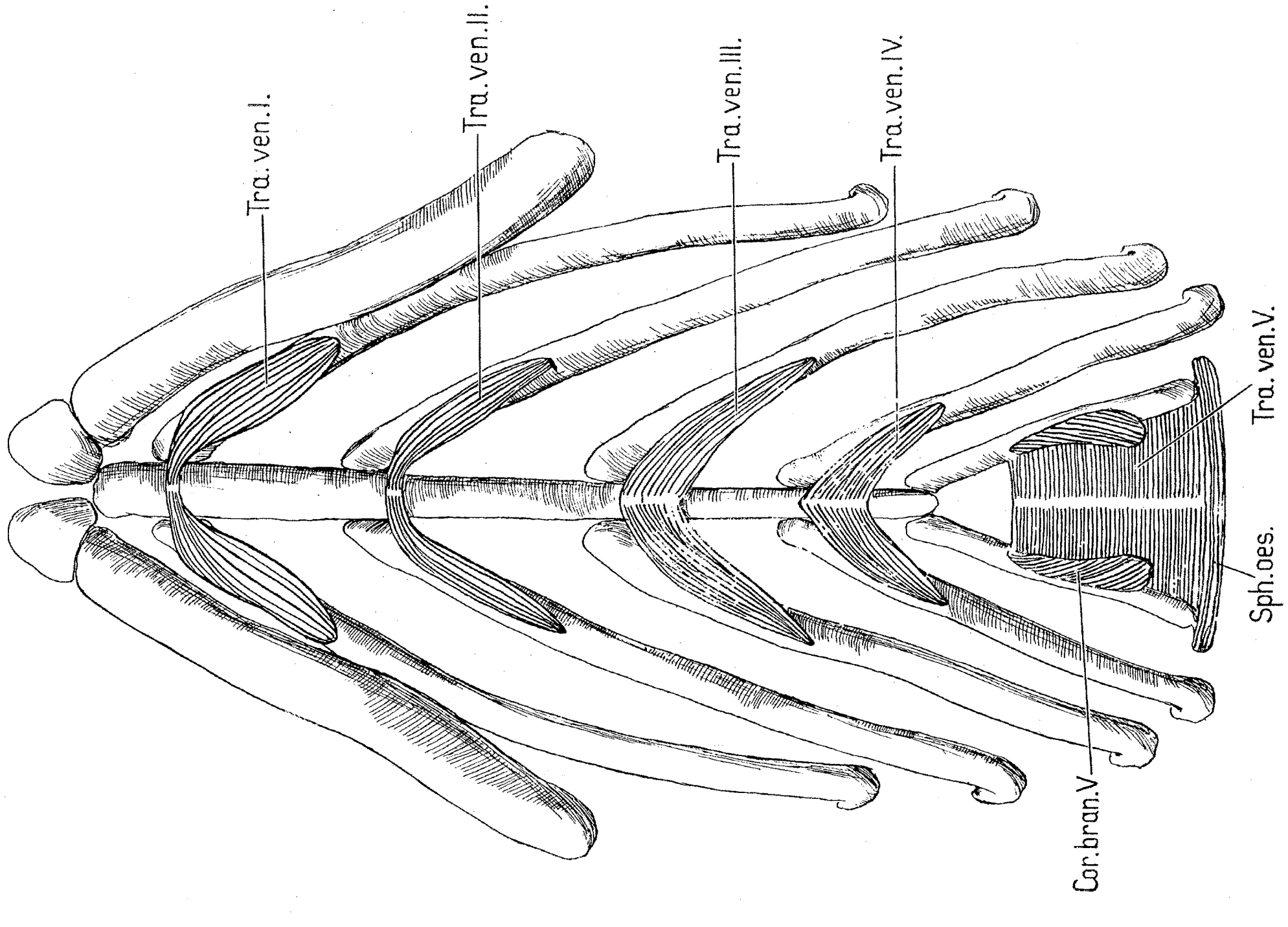

130

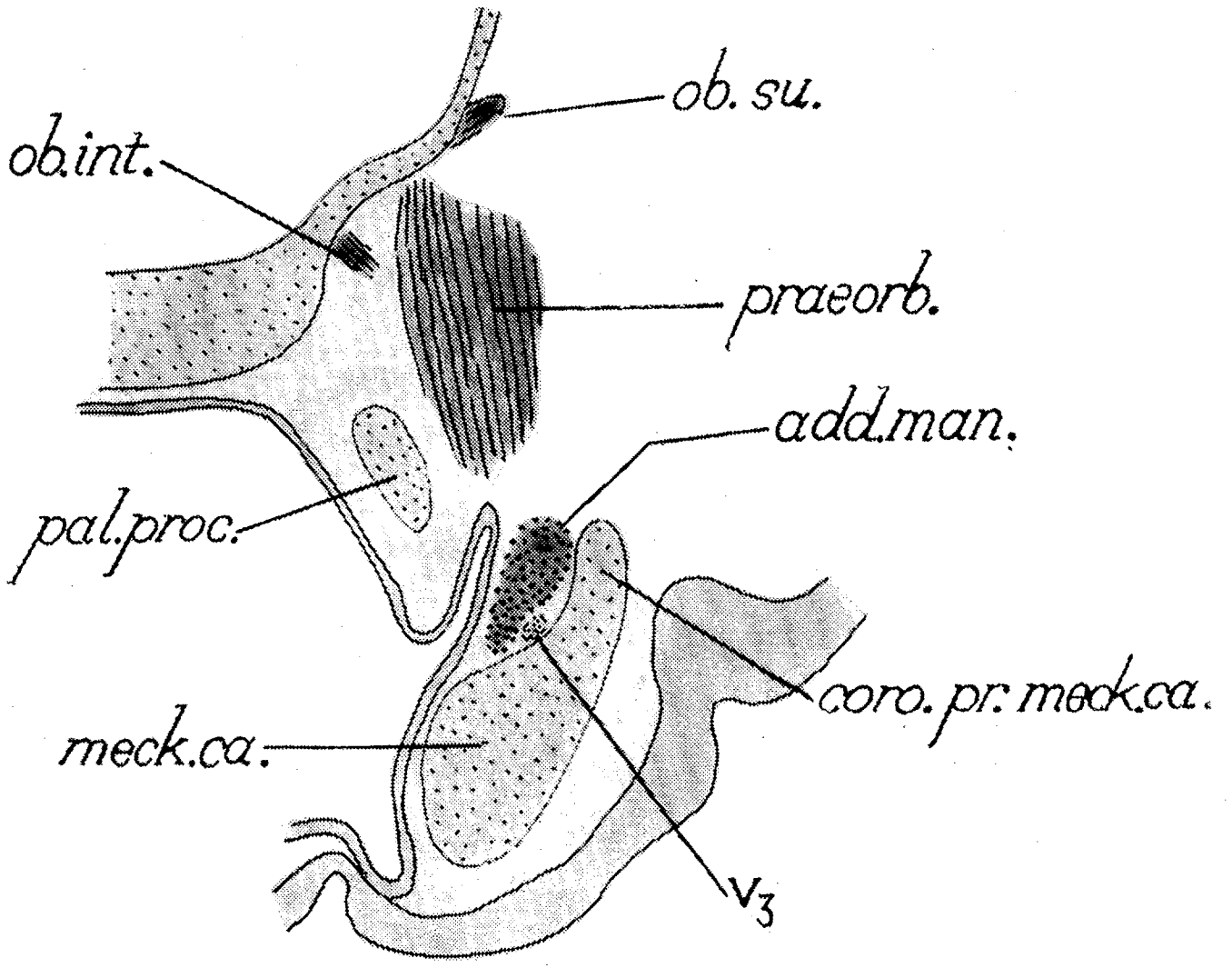

131

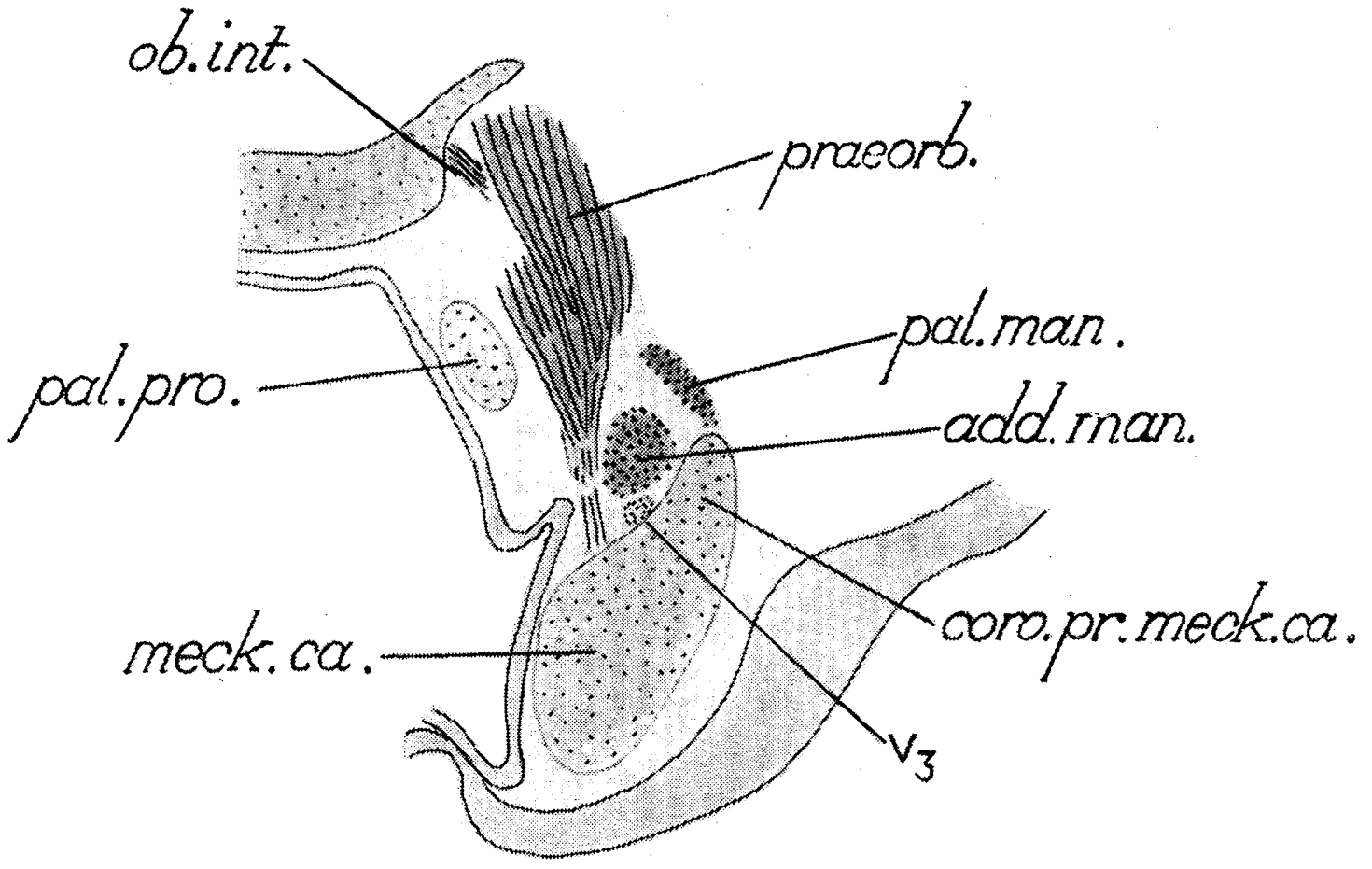

132

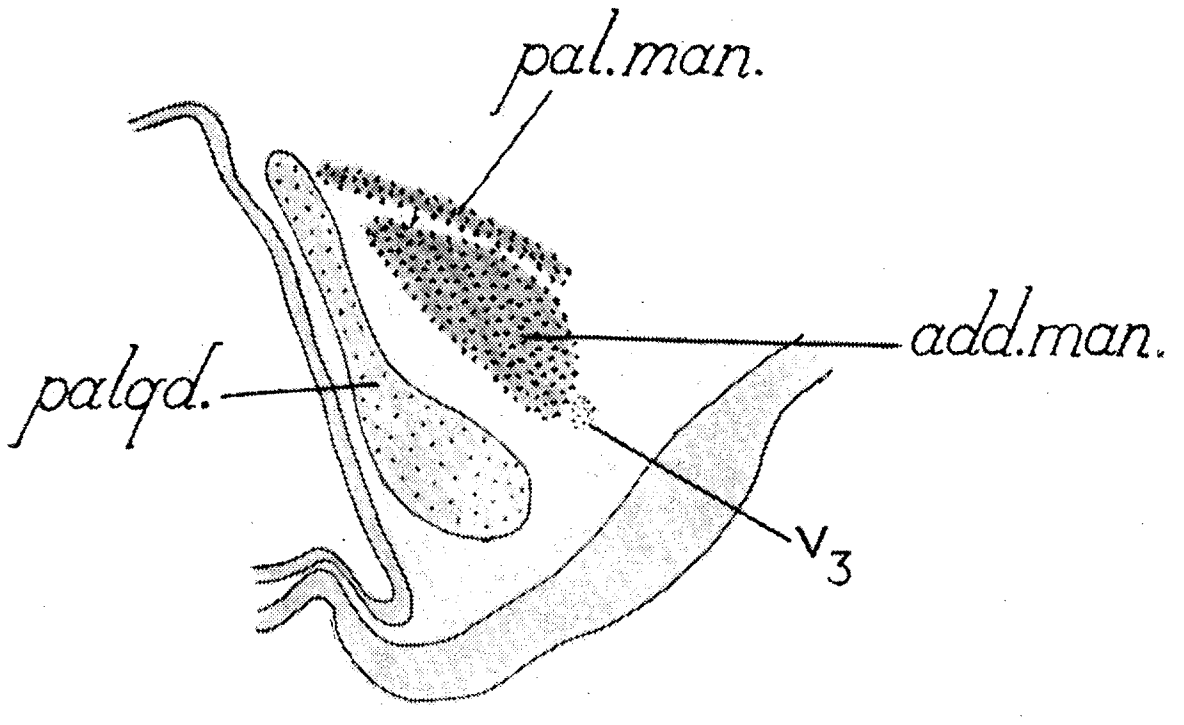

133

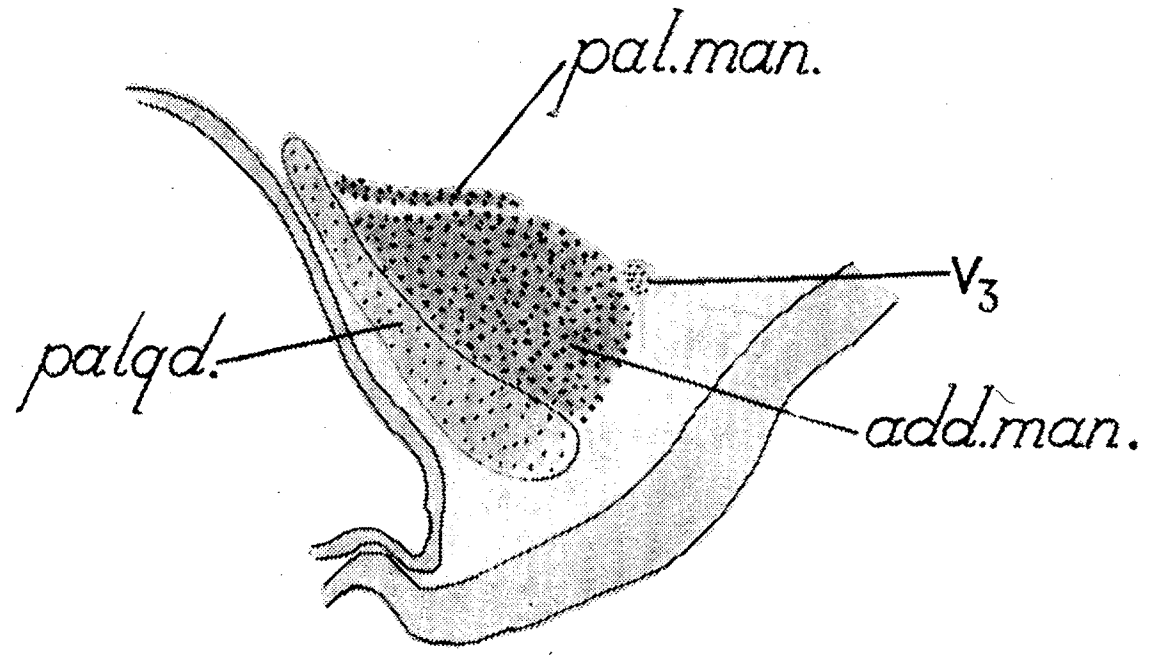

134

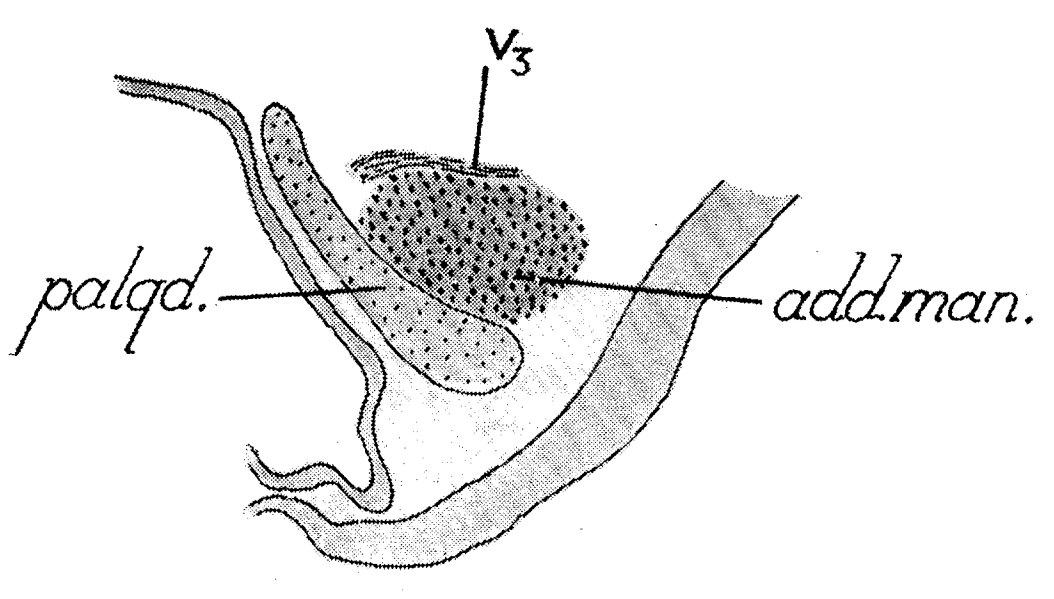

135

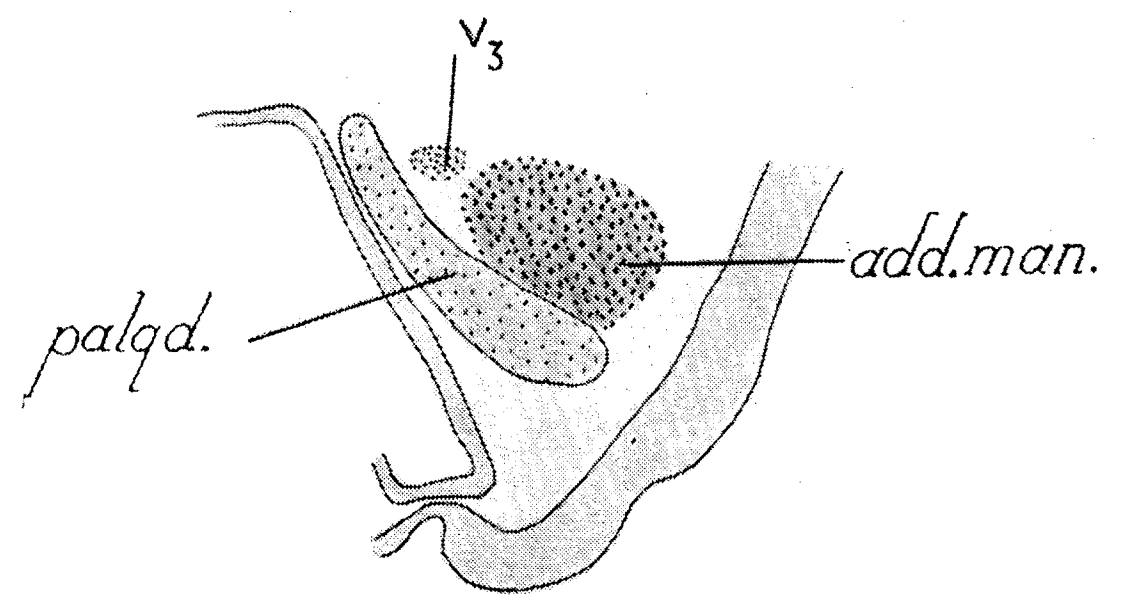

136

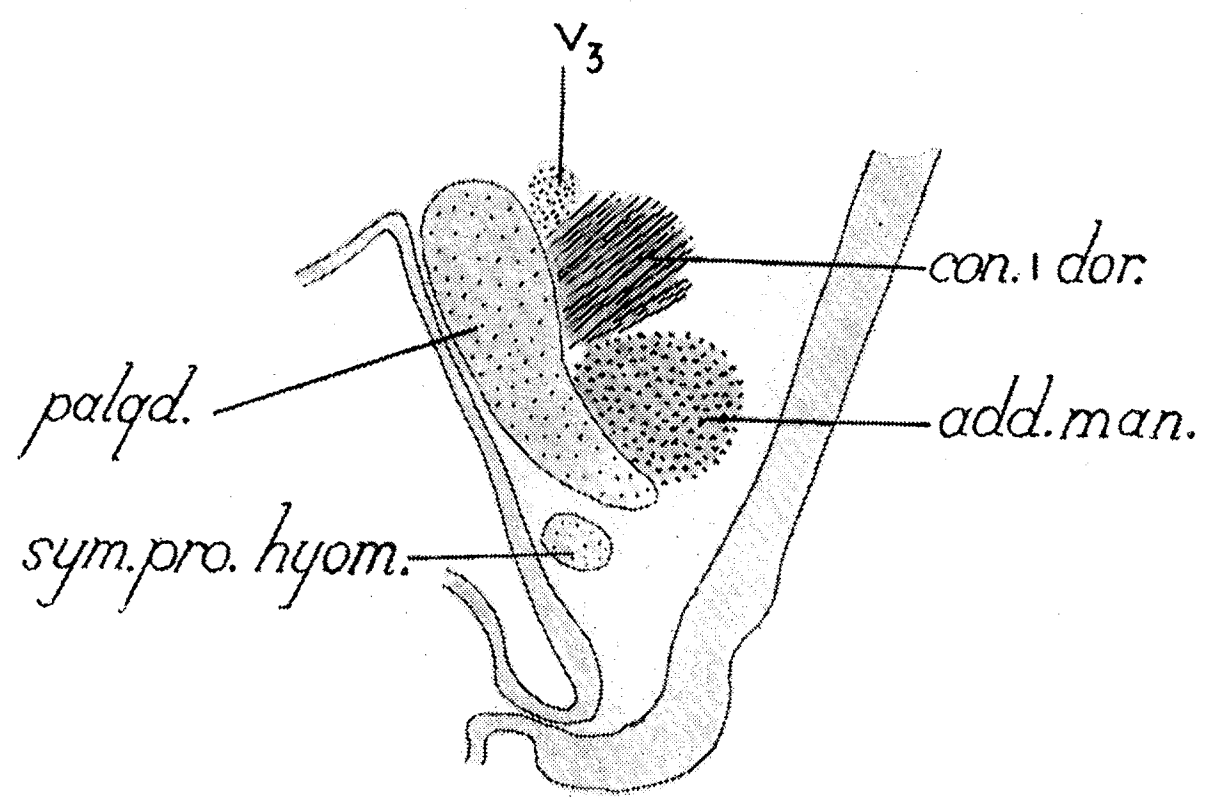

137

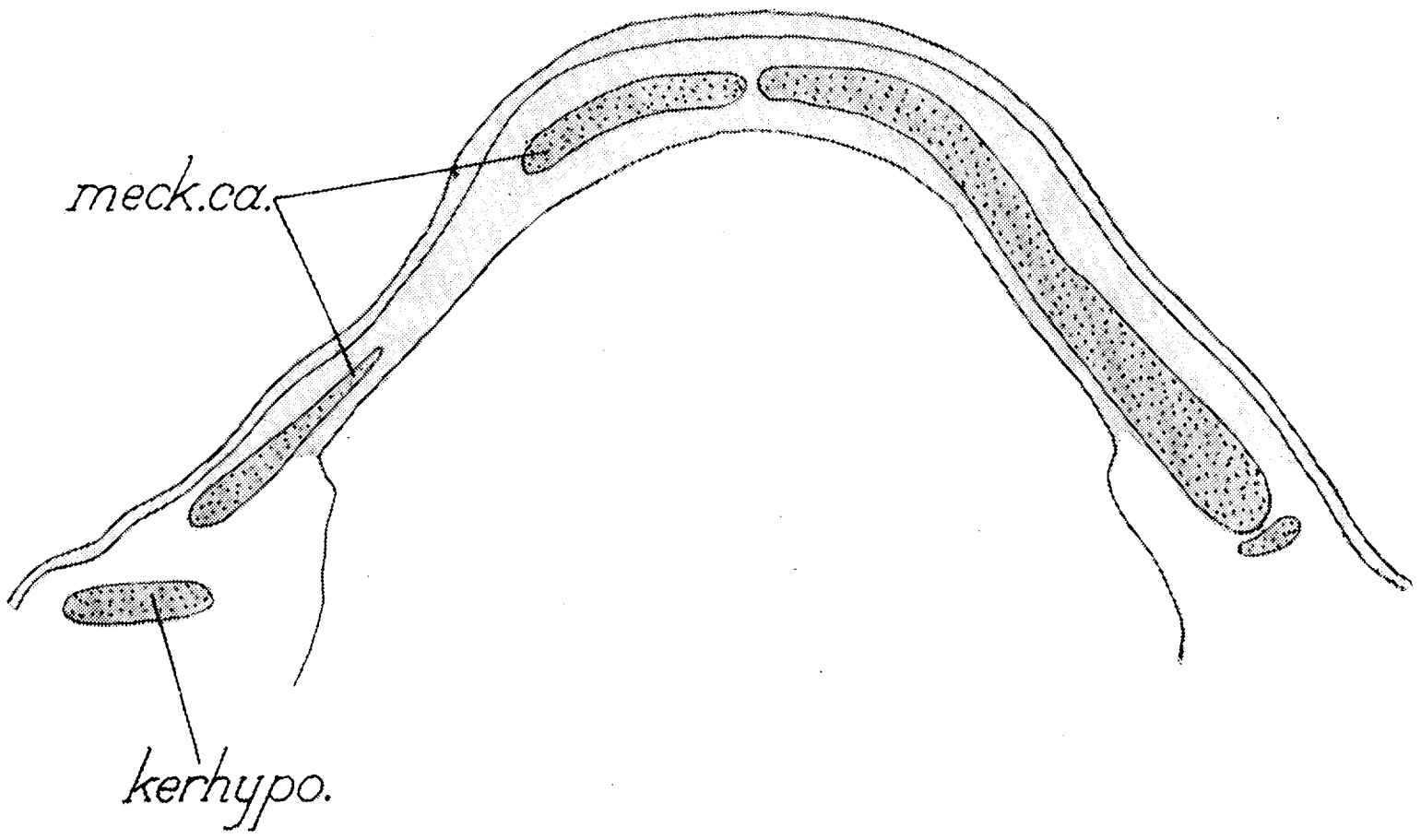

138

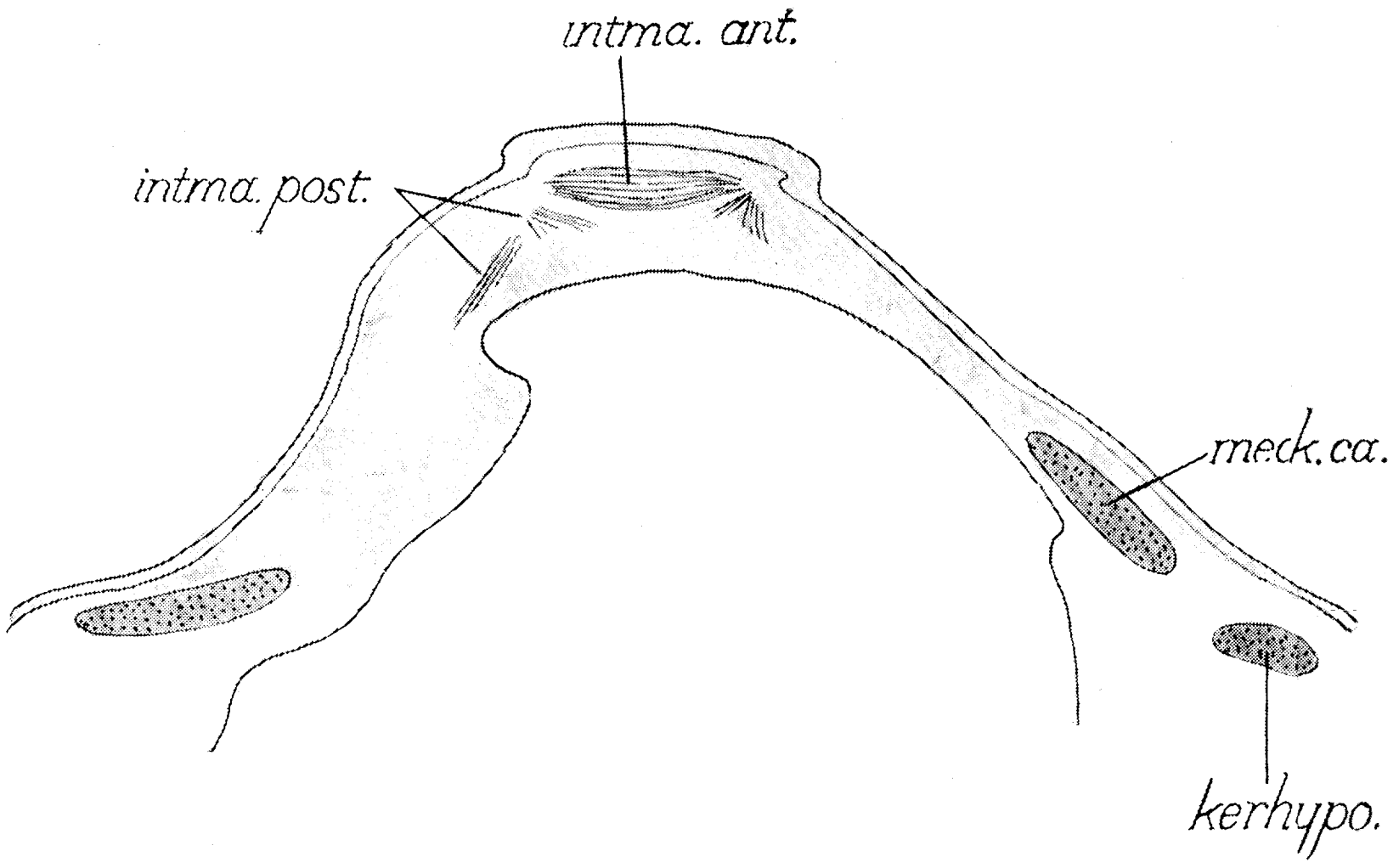

139

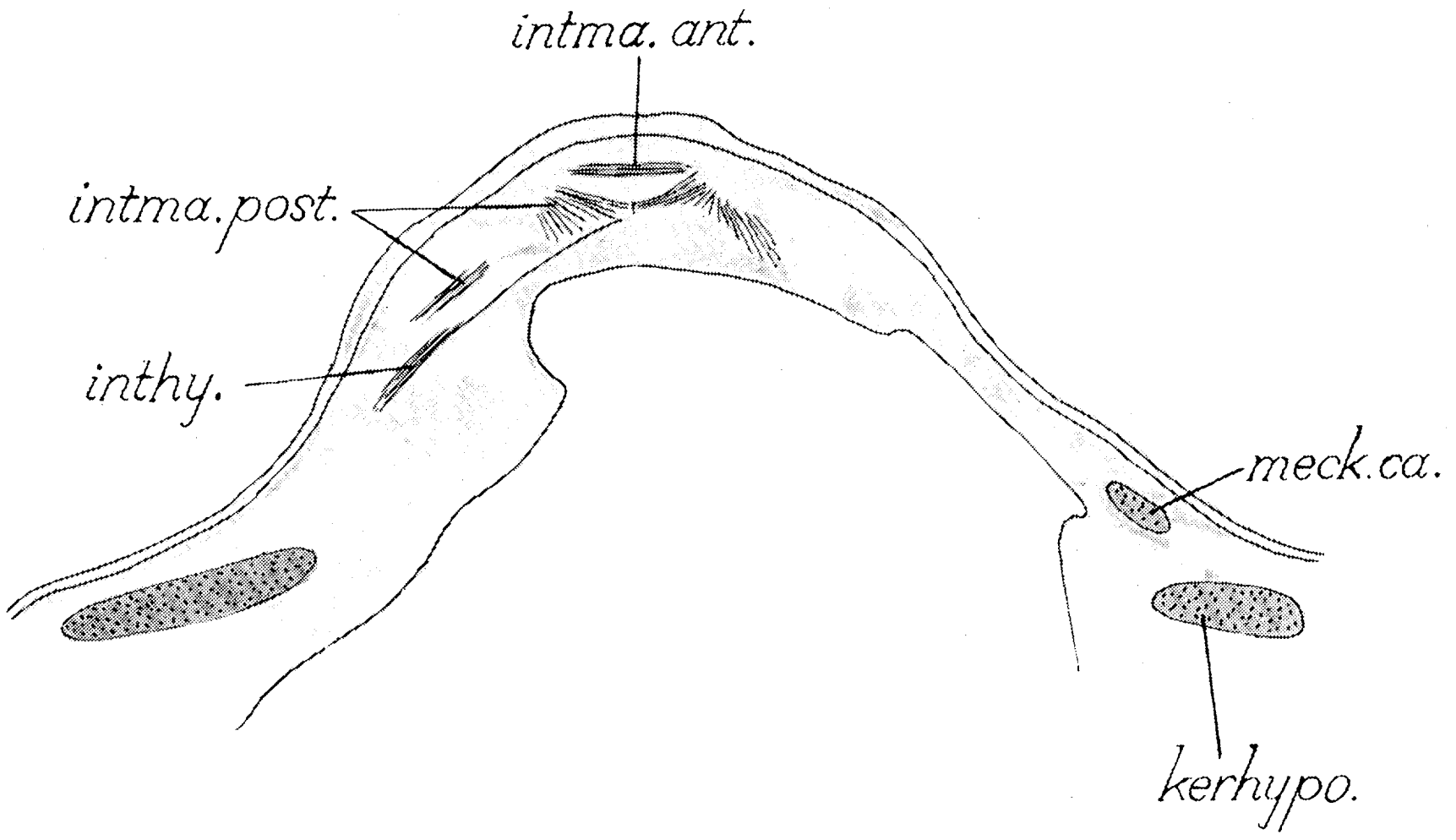

140

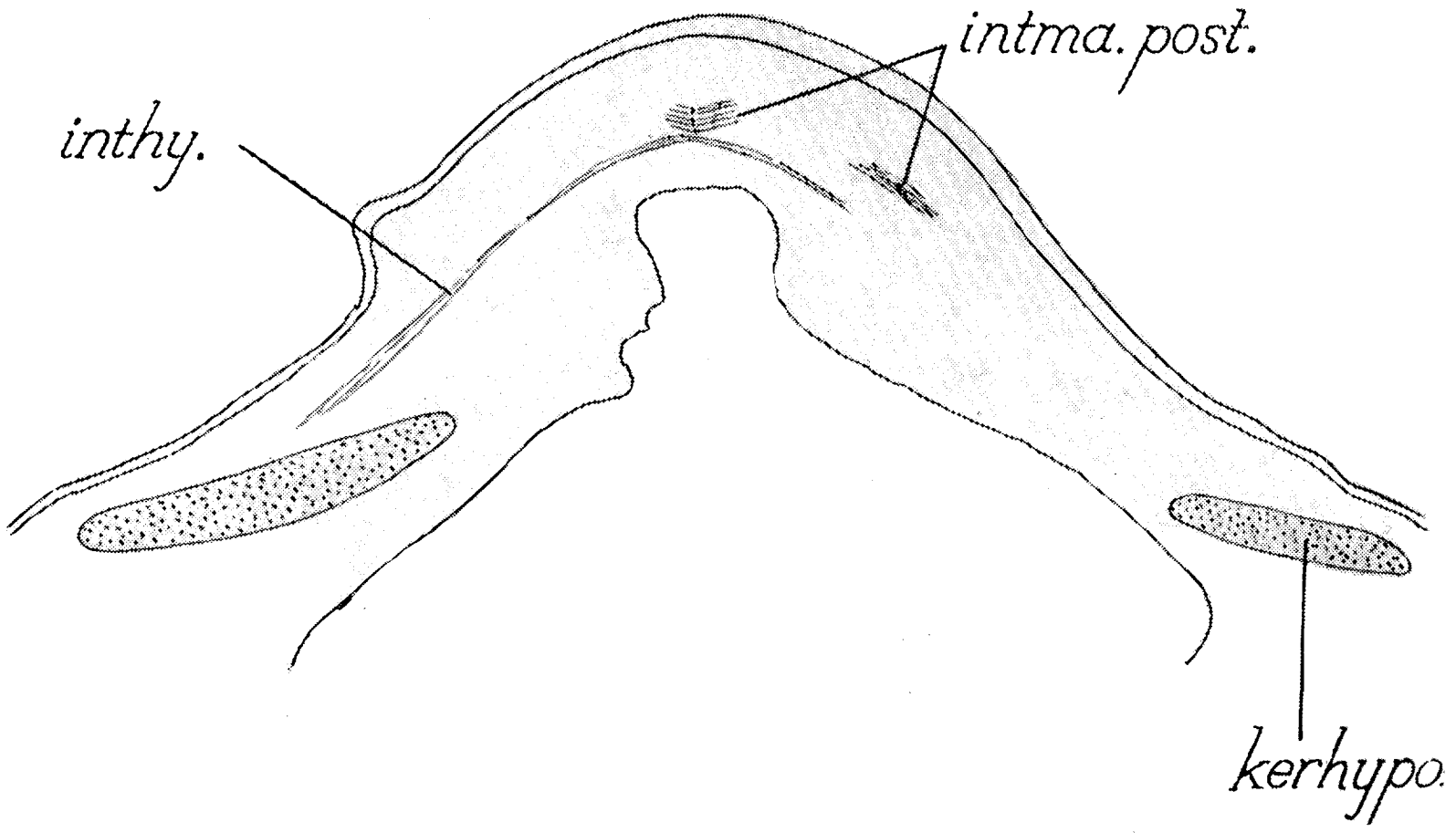

141

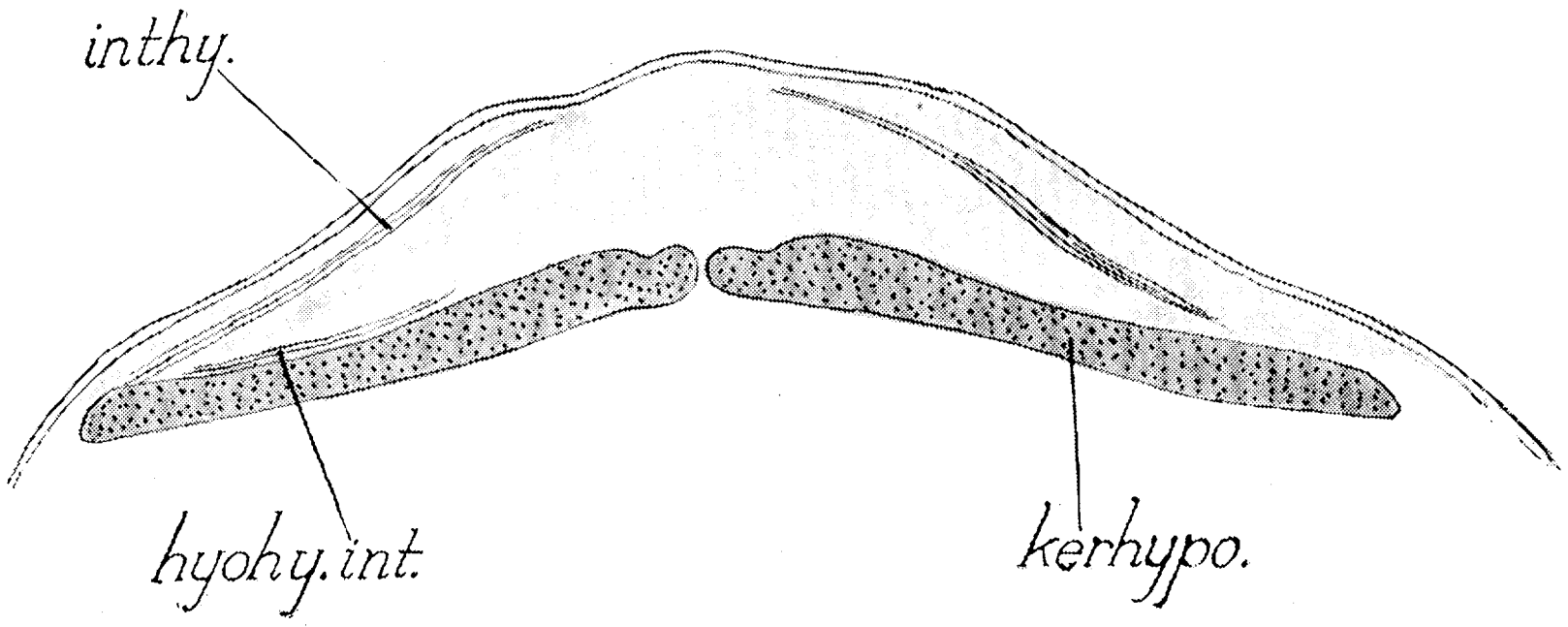

142

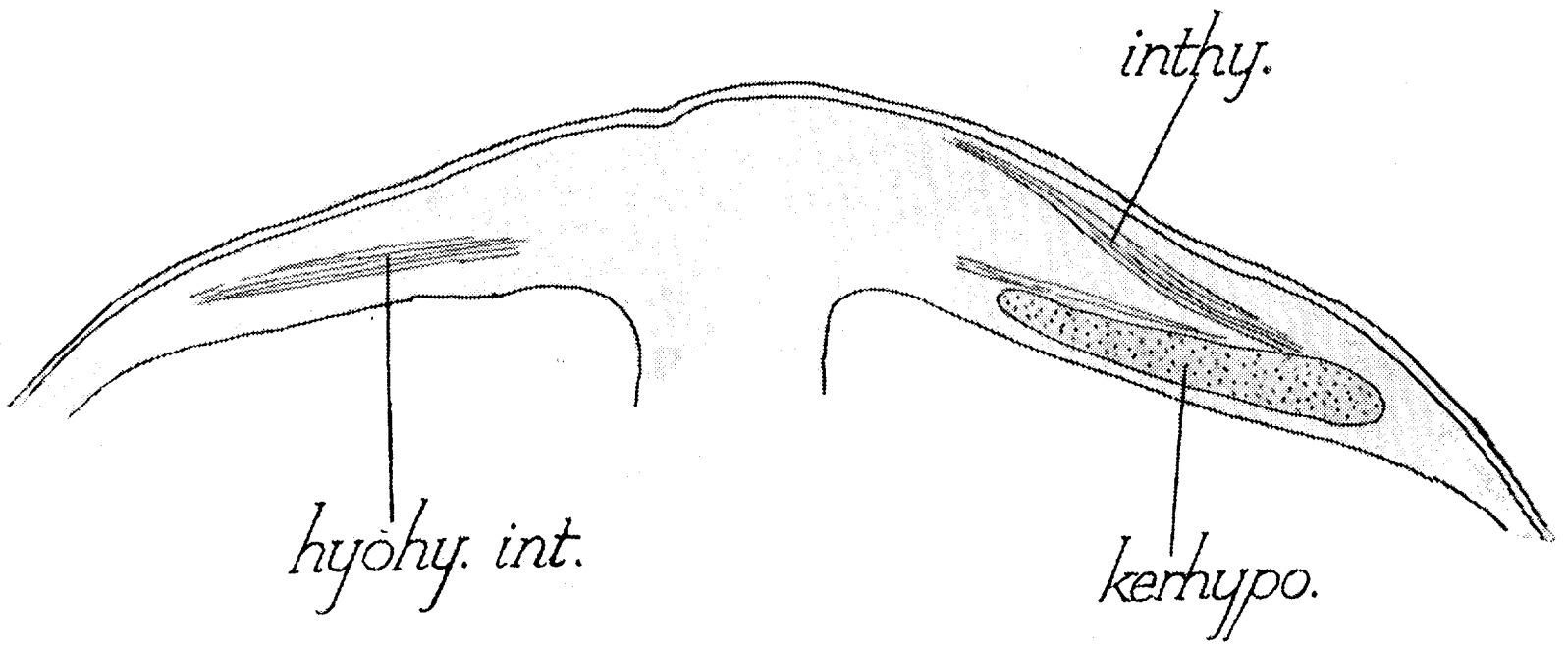

143

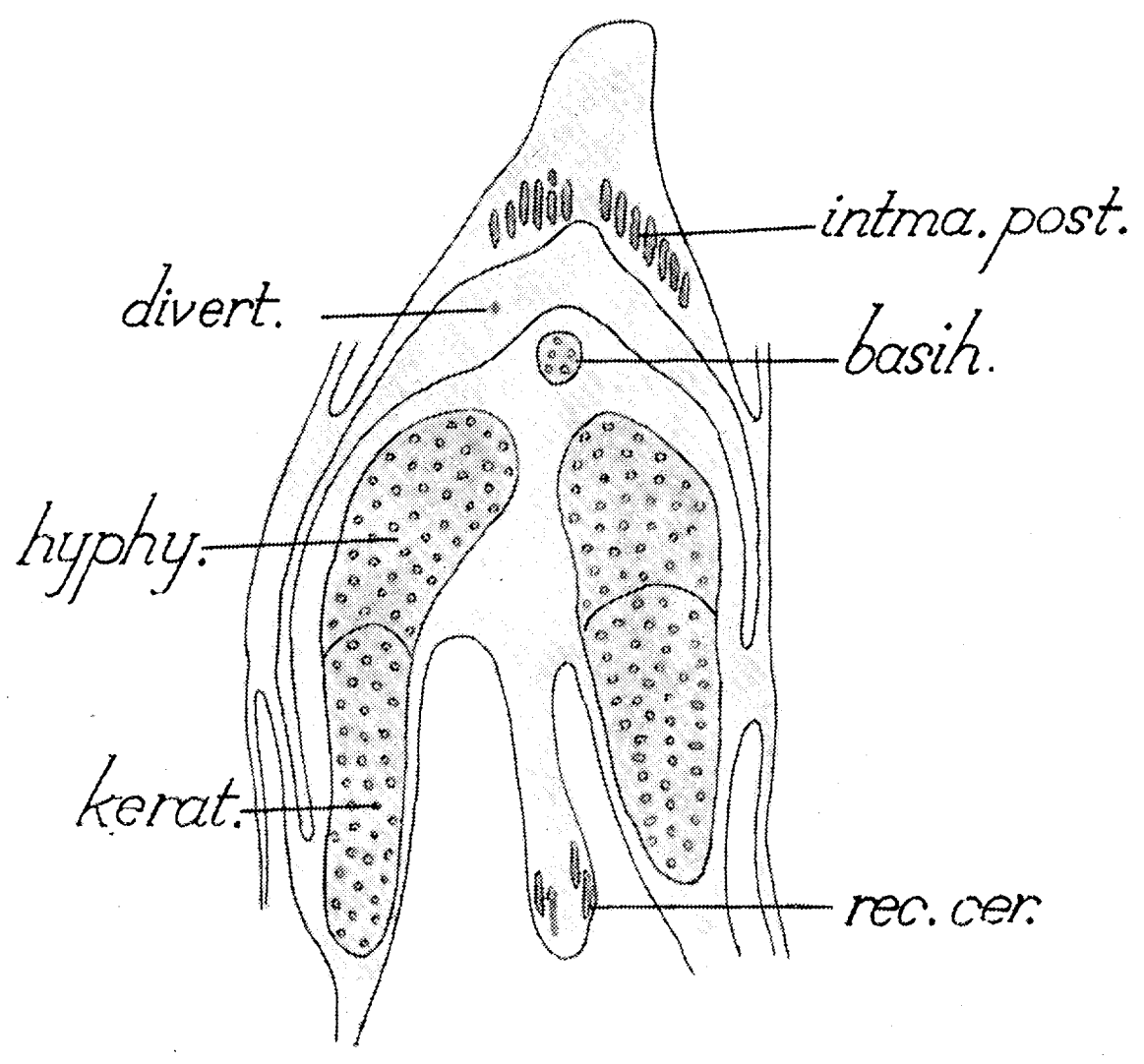

144

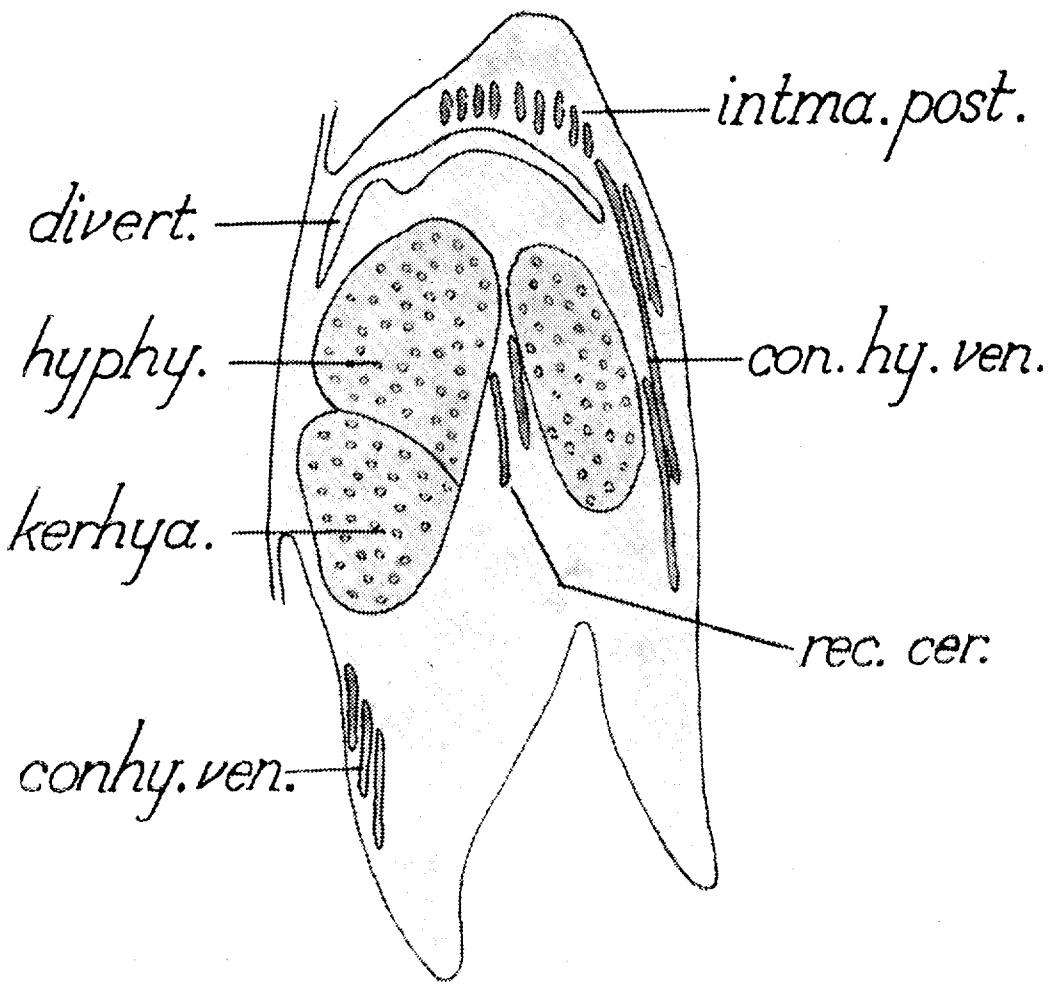

145

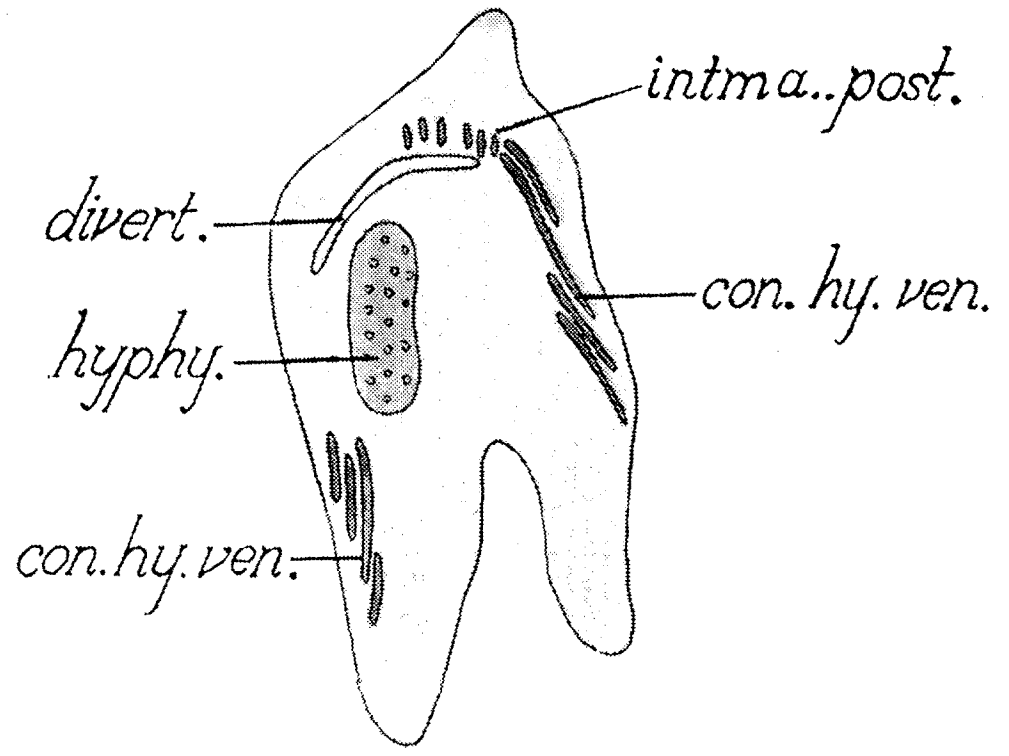

146

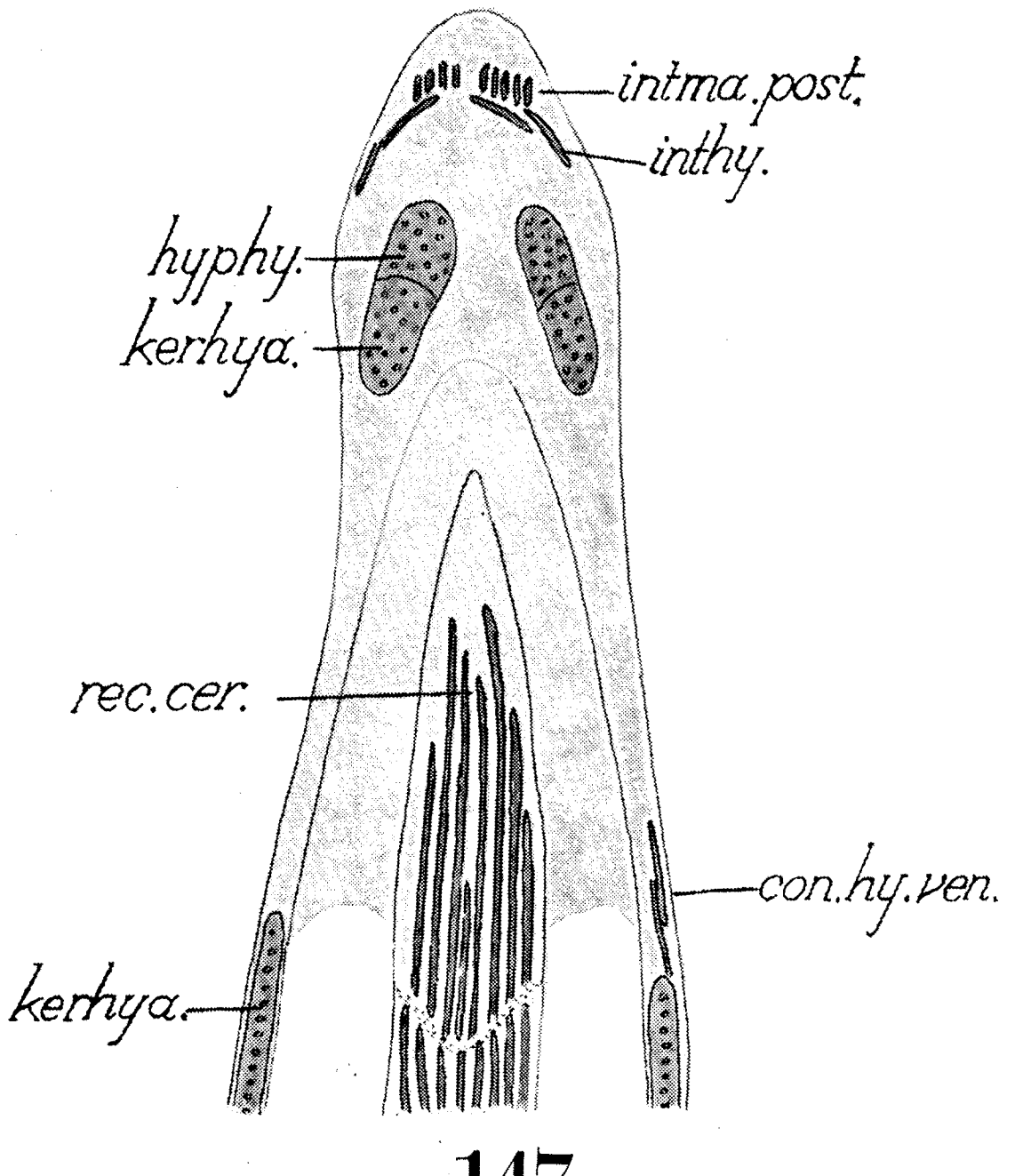

147

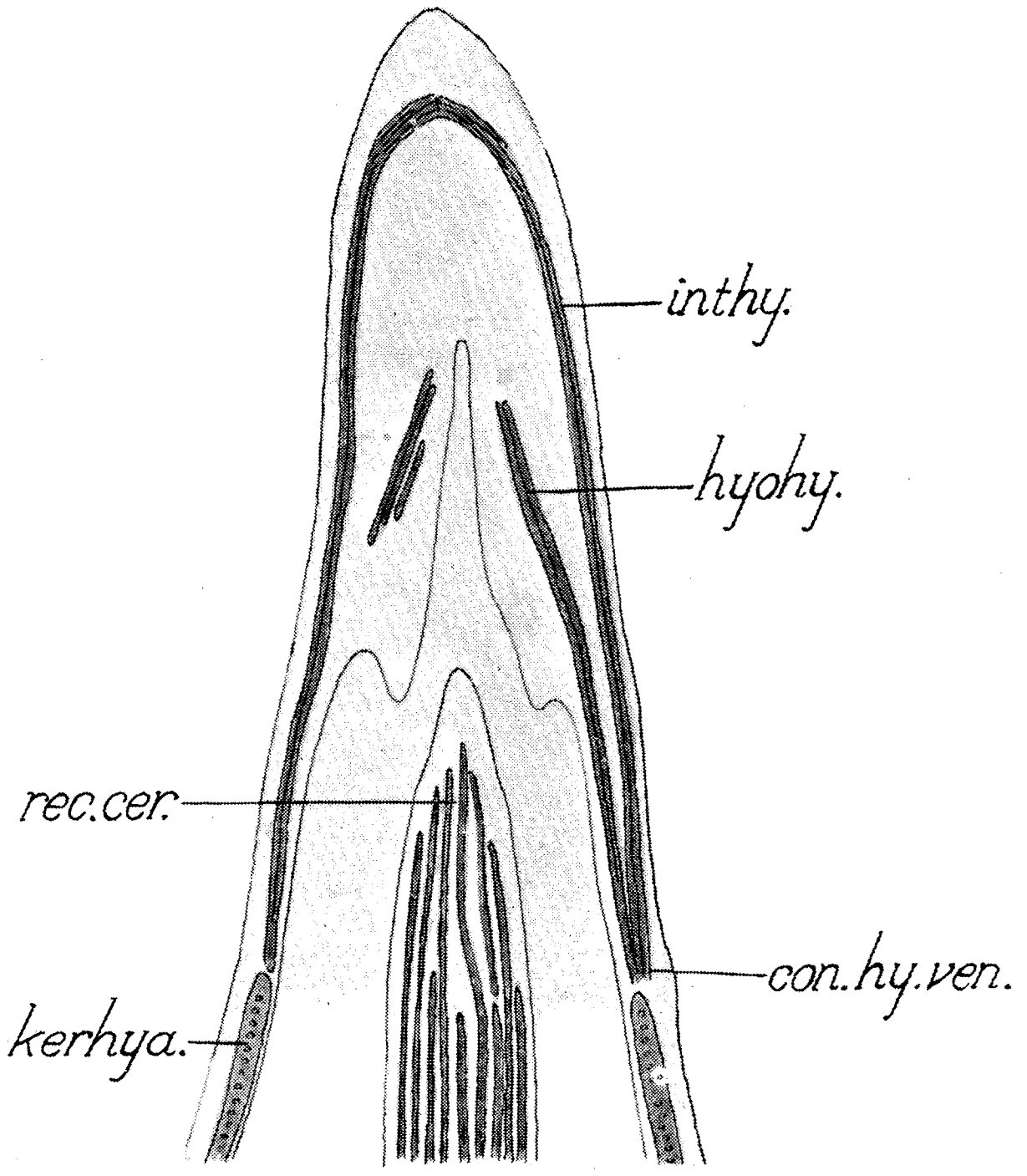

148

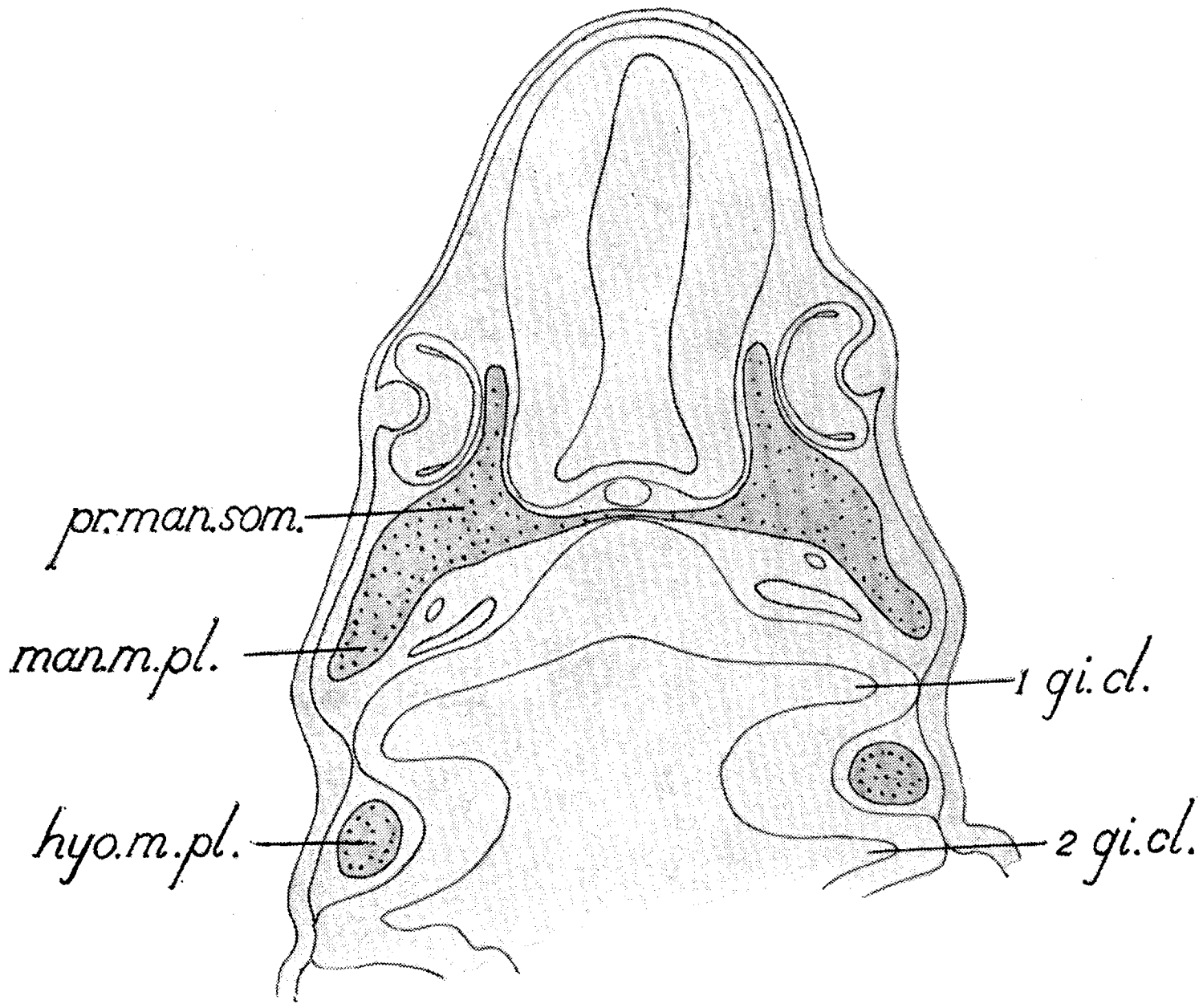

149

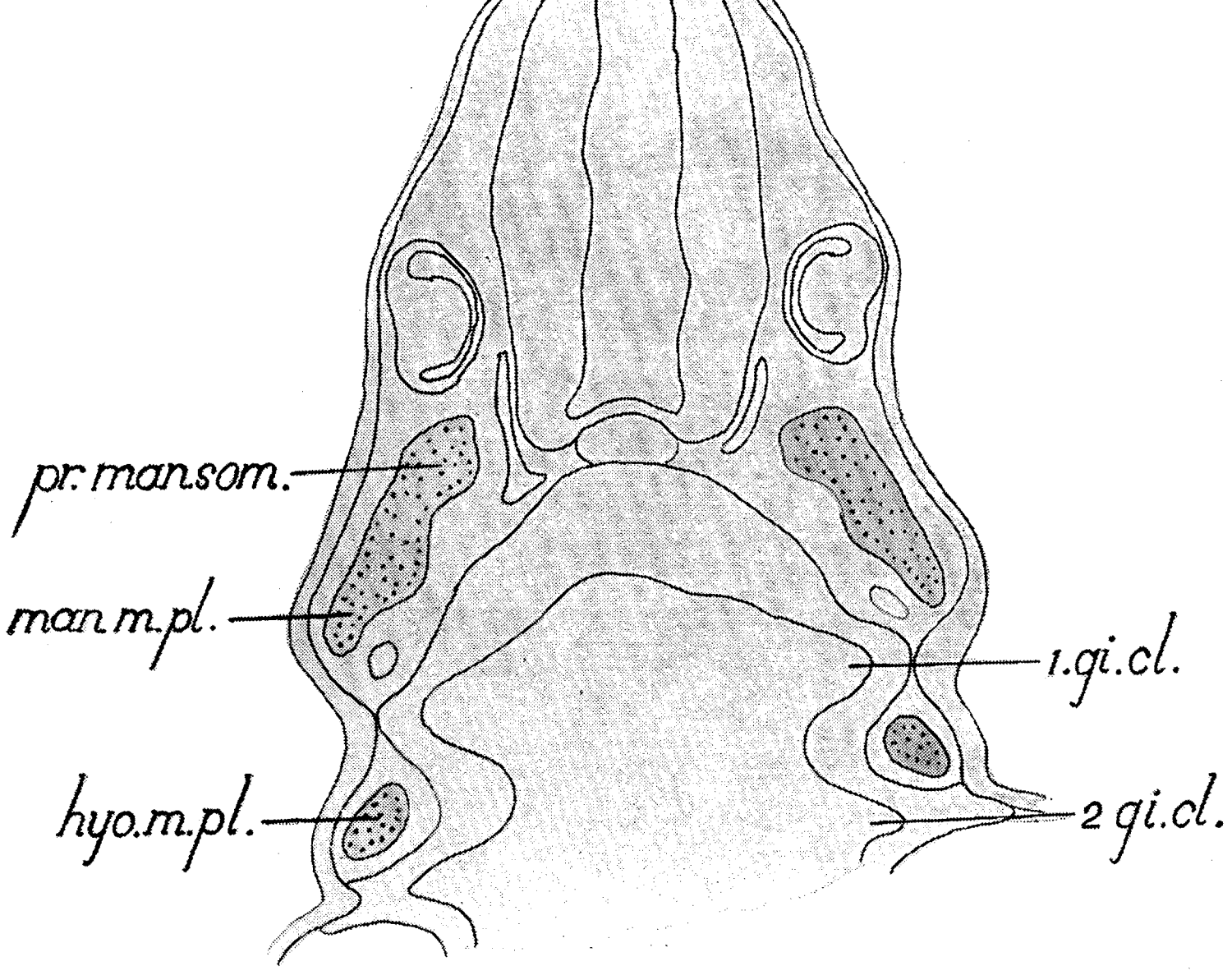

150

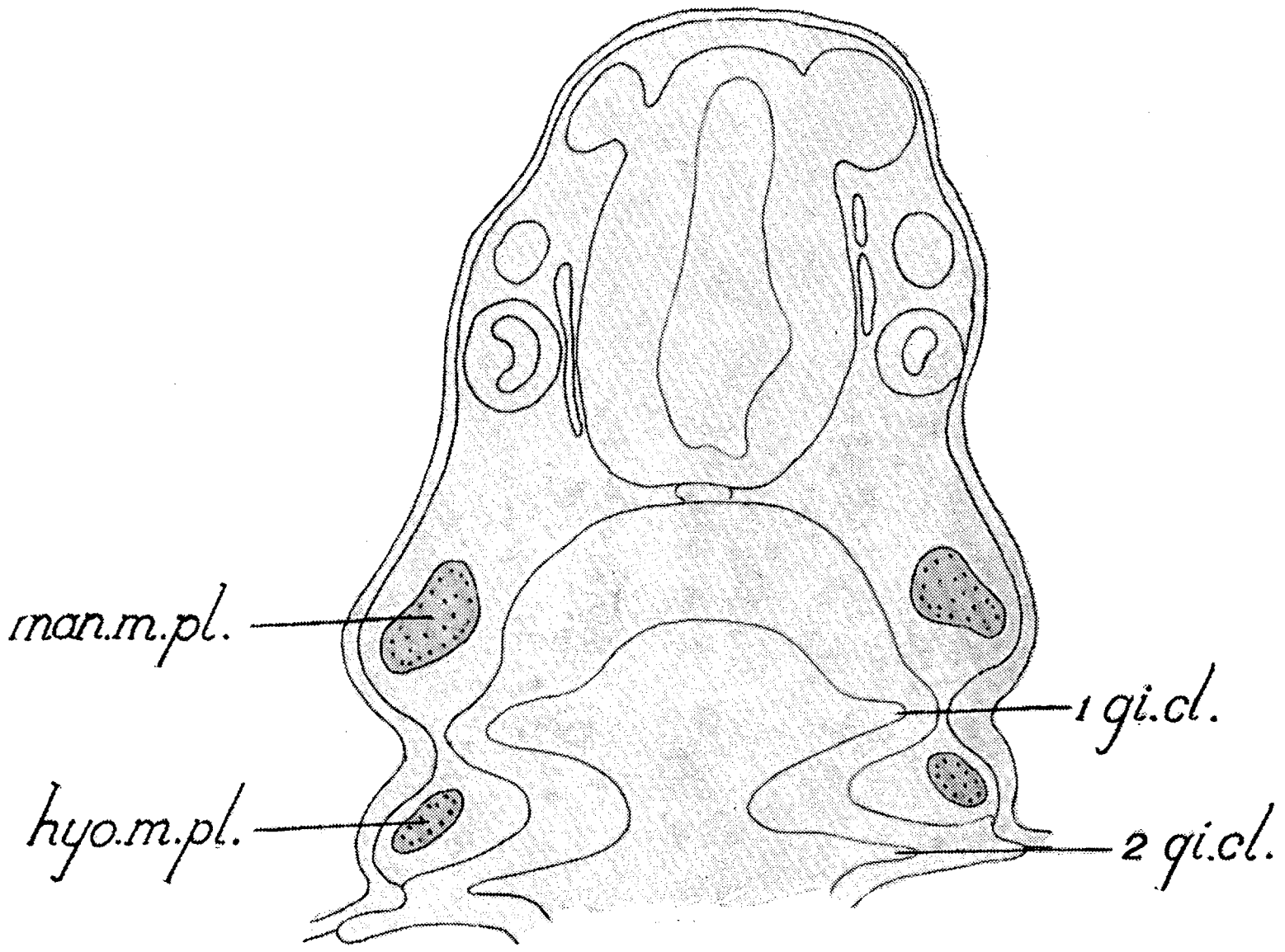

151

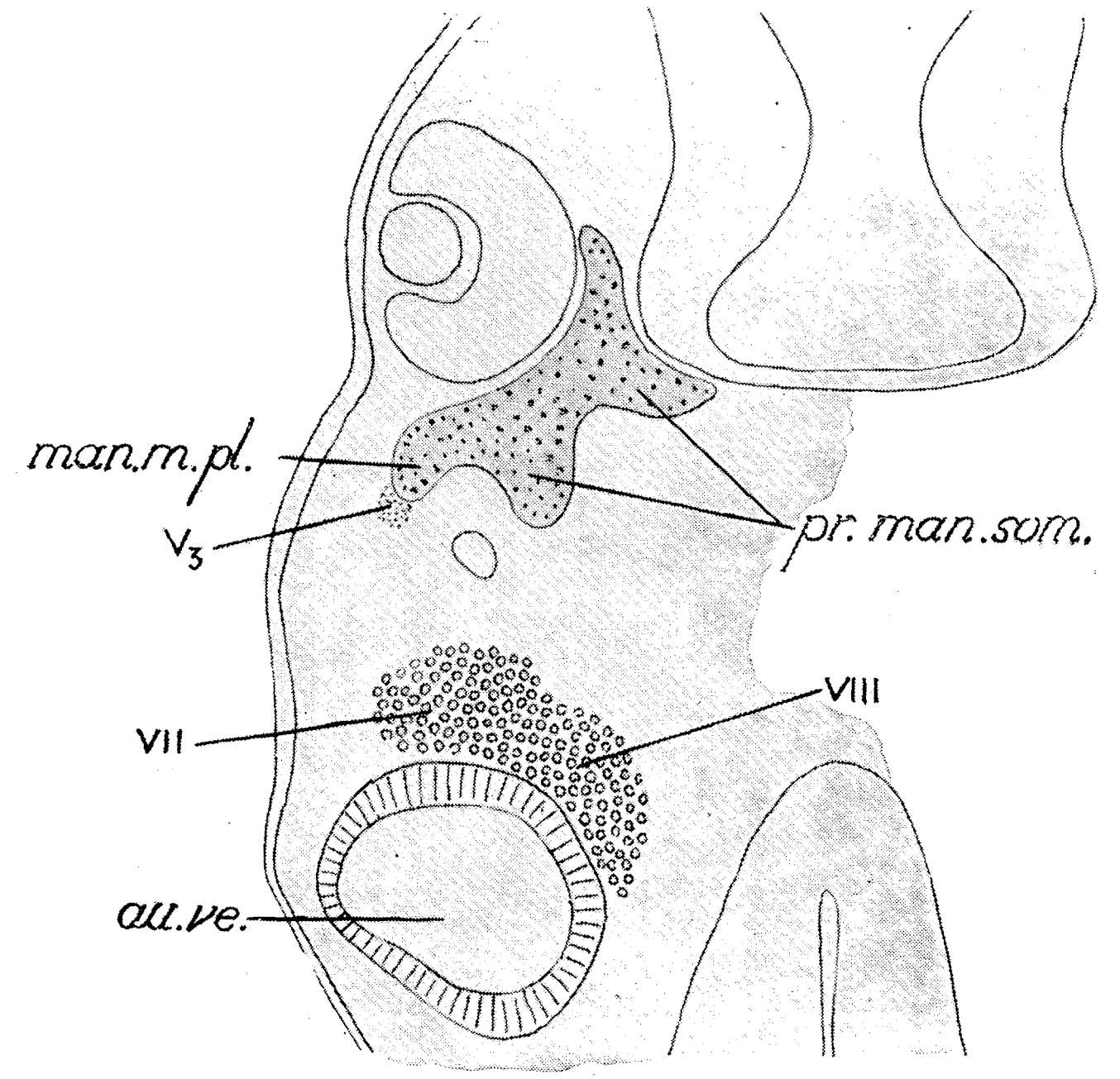

152

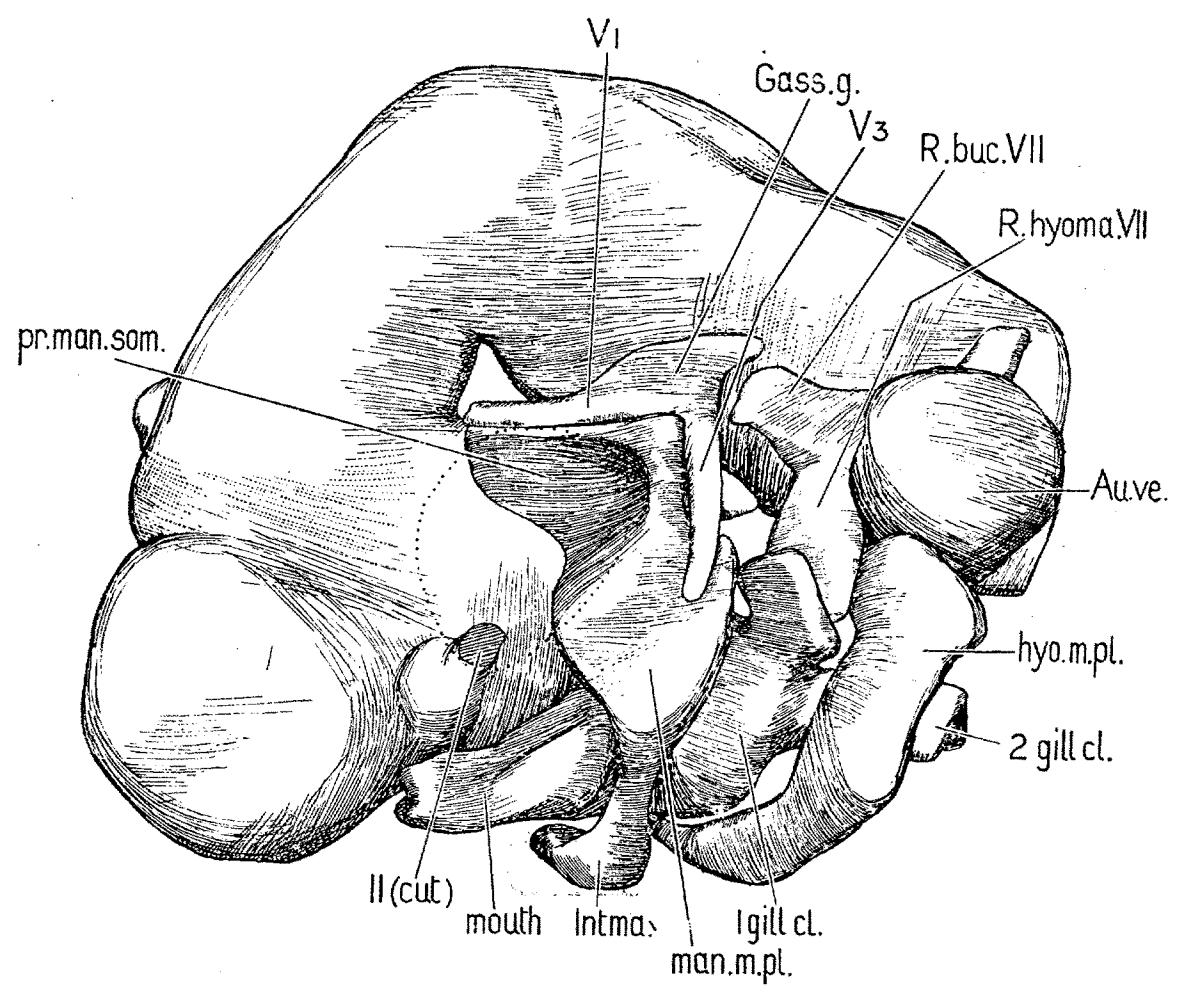

153

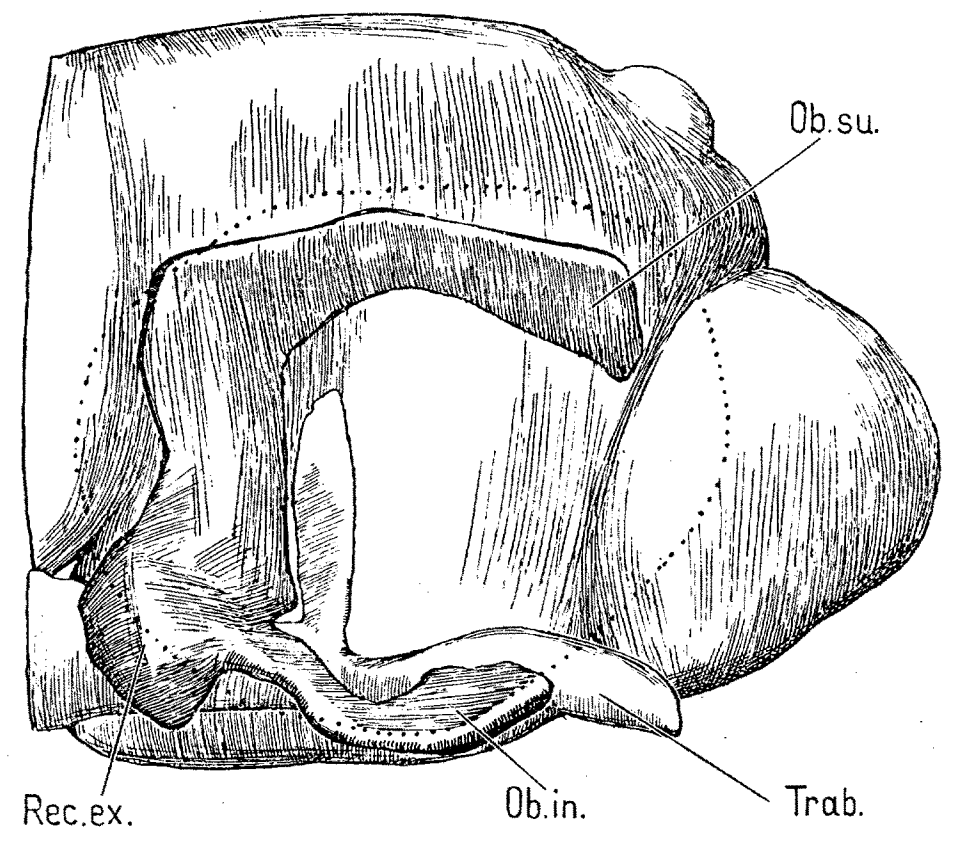

154

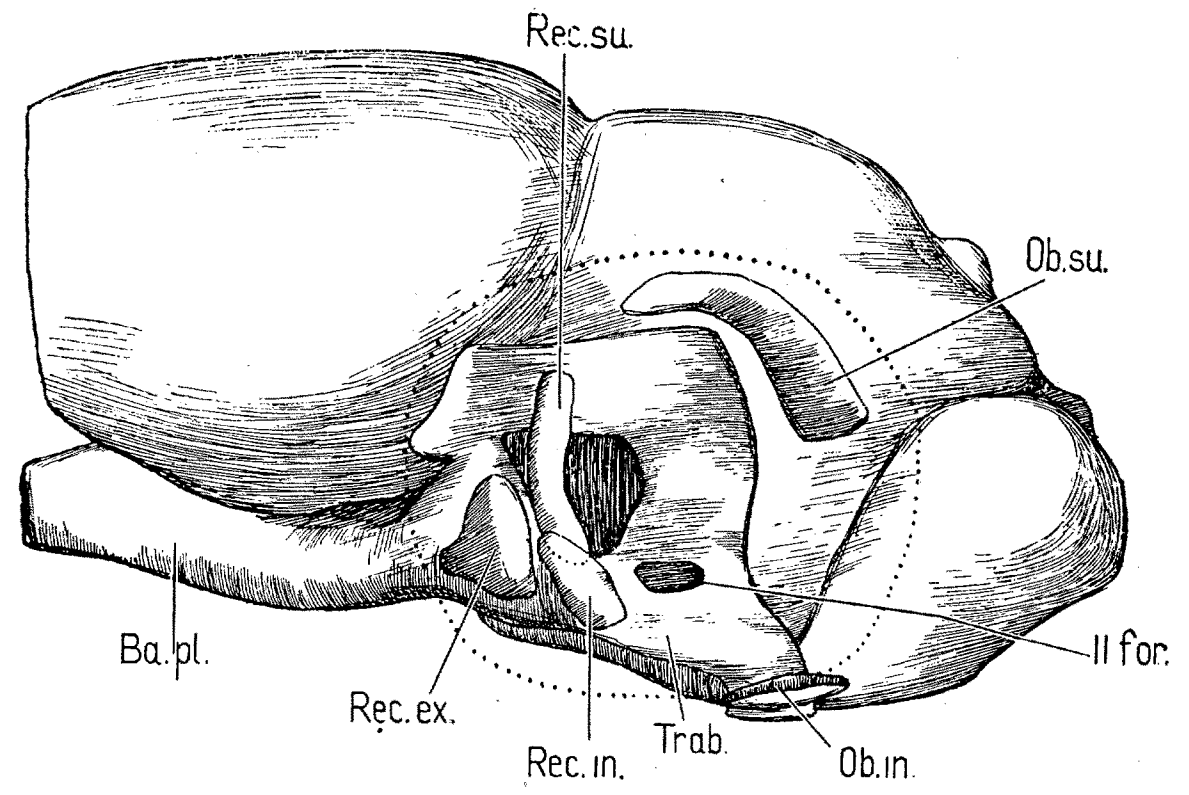

155

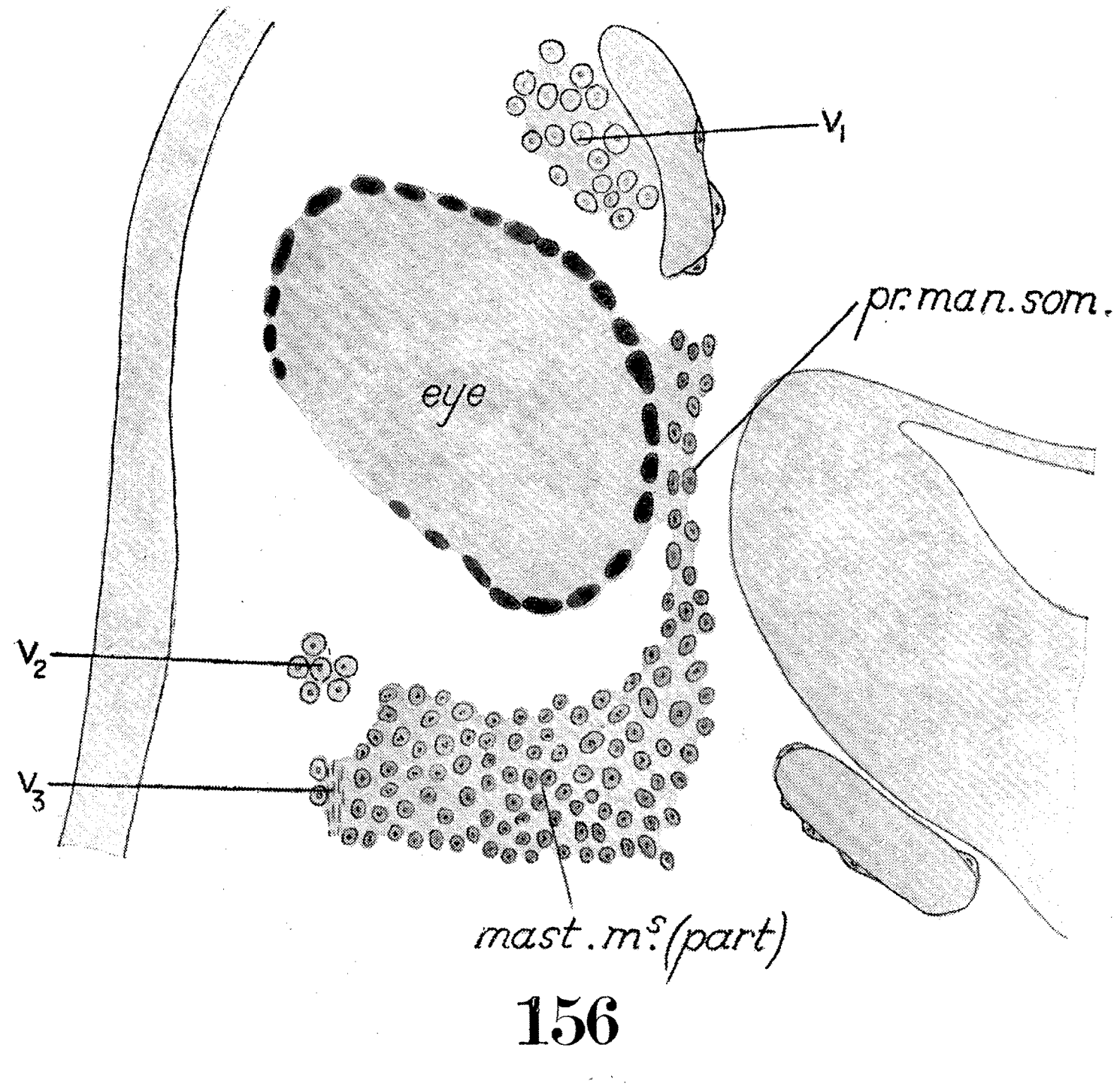

156

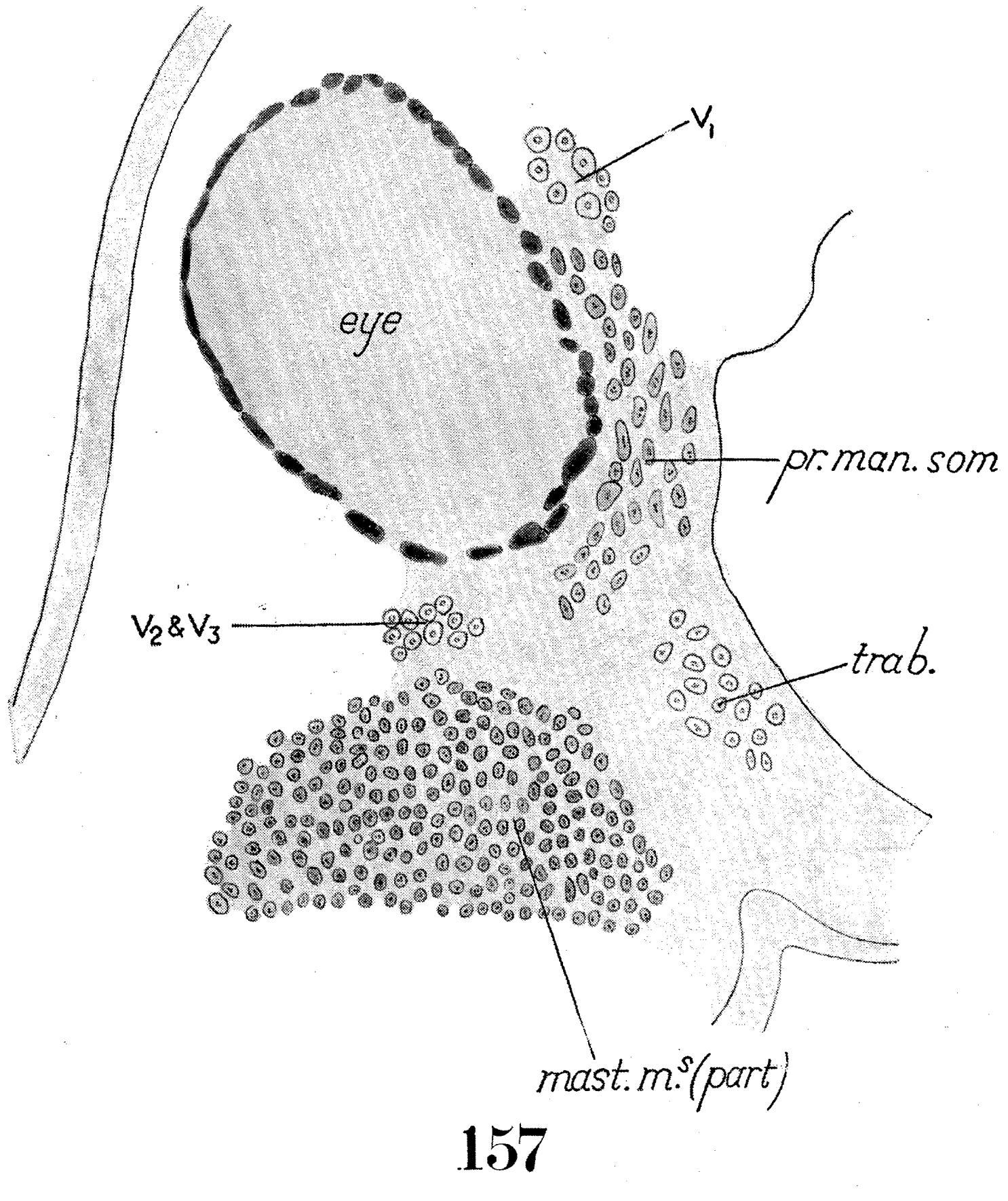

157

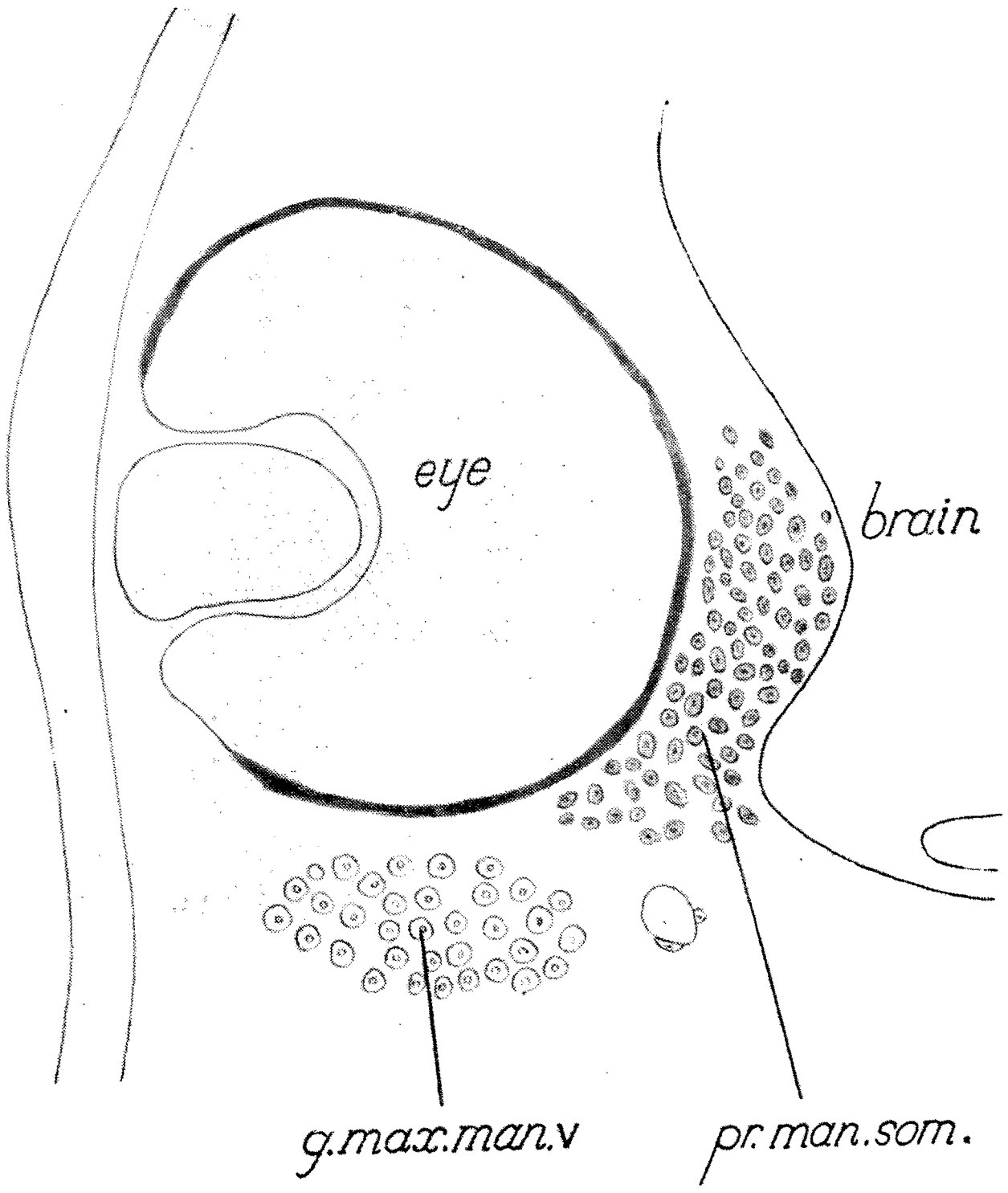

158

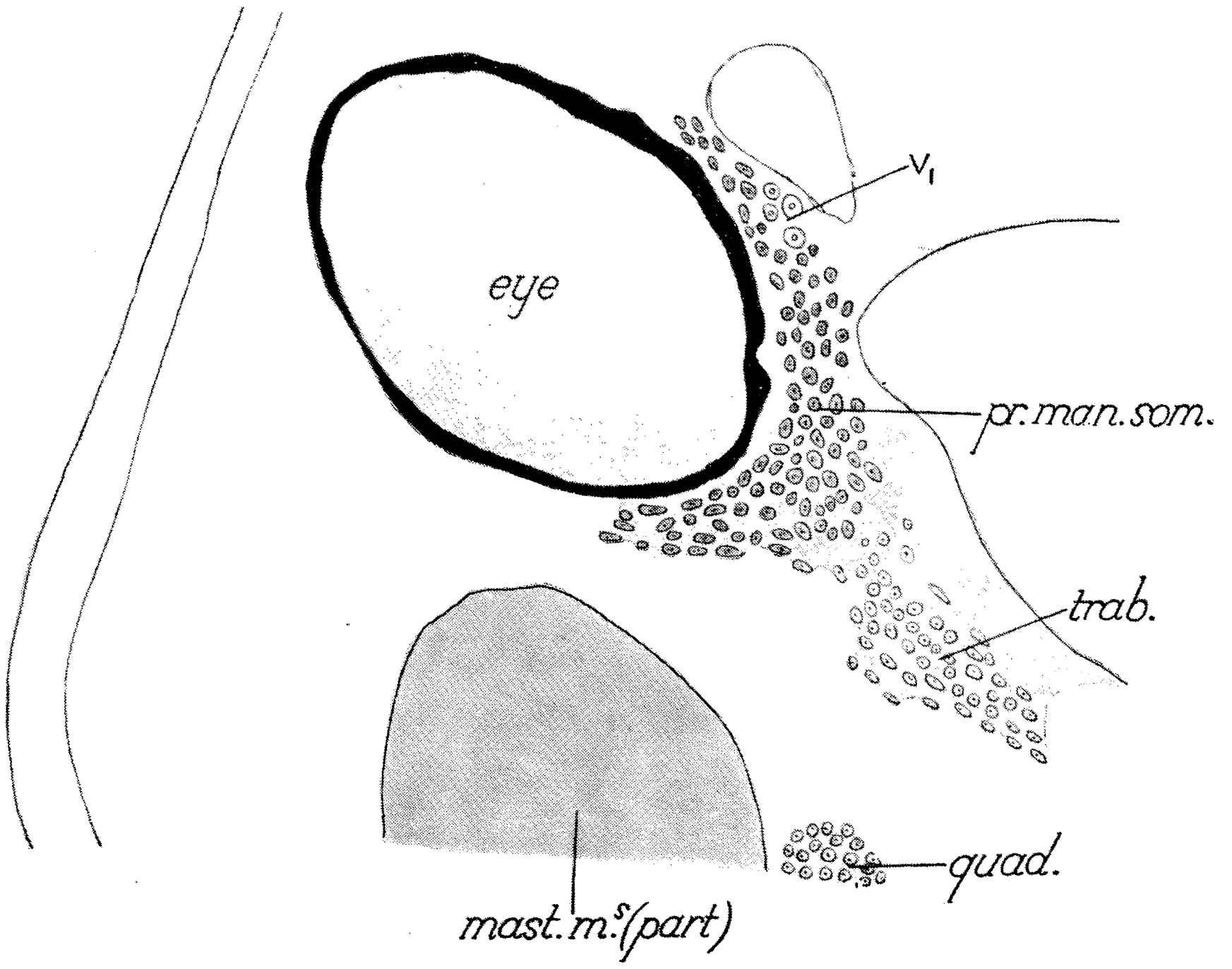

159

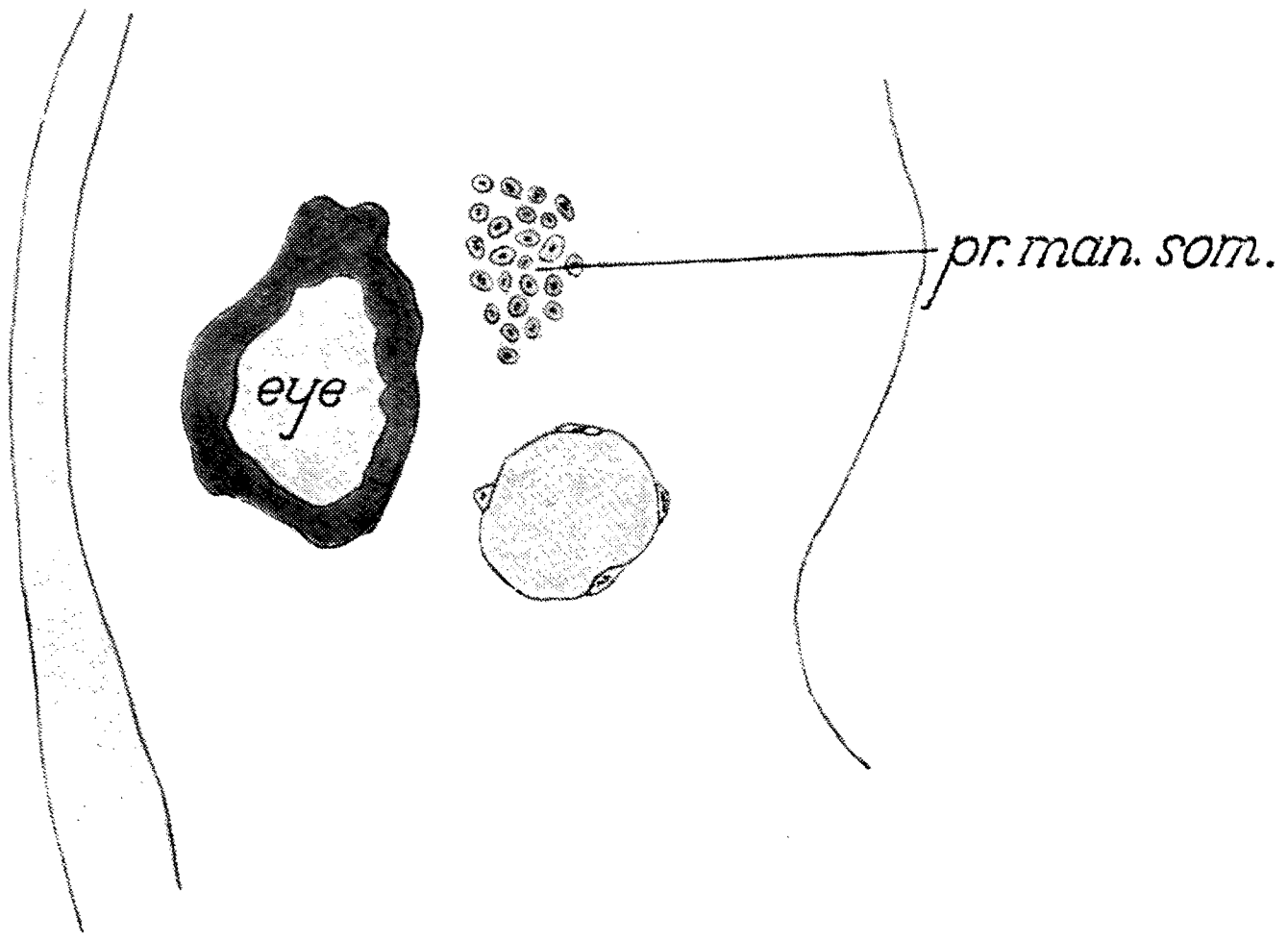

160

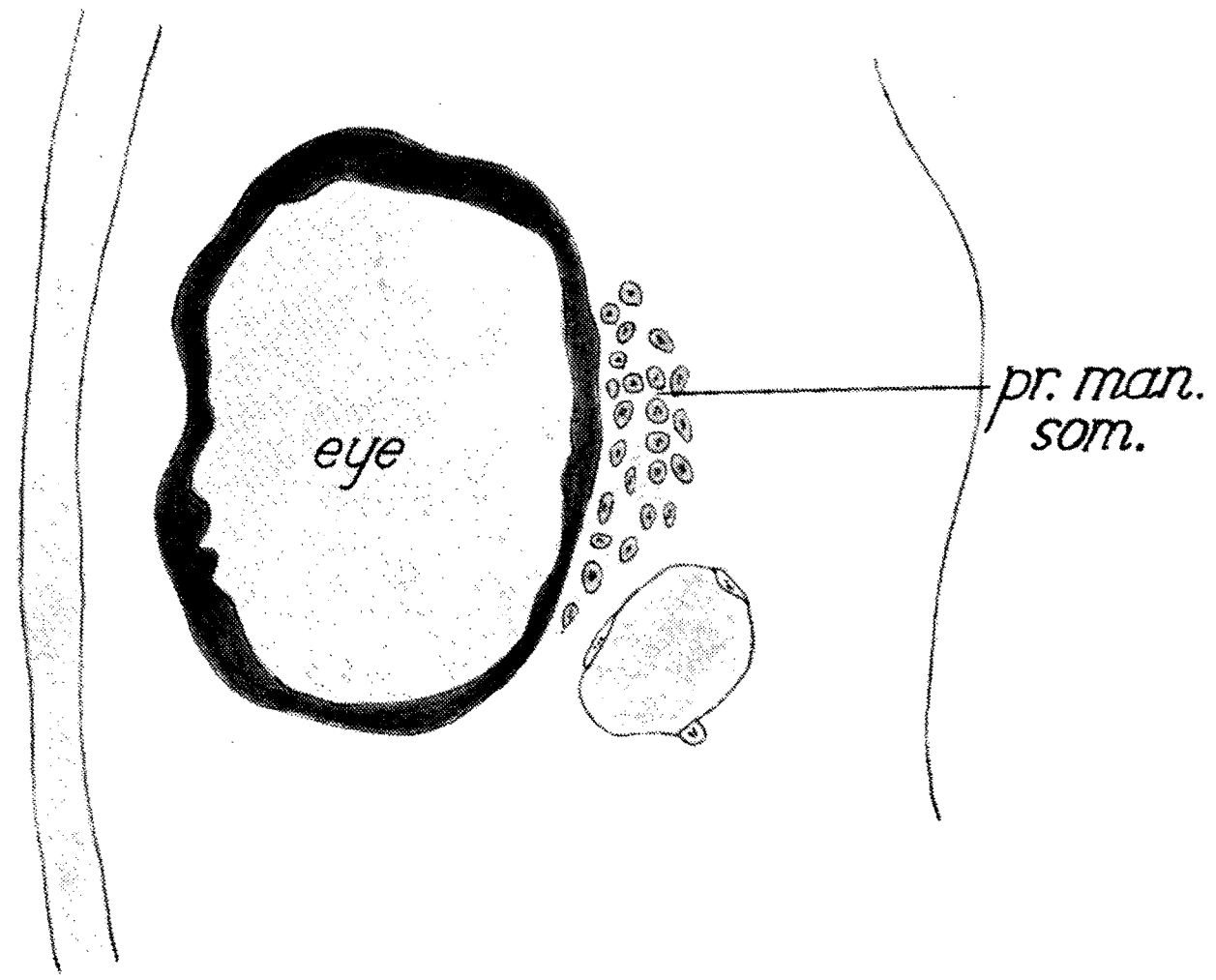

161

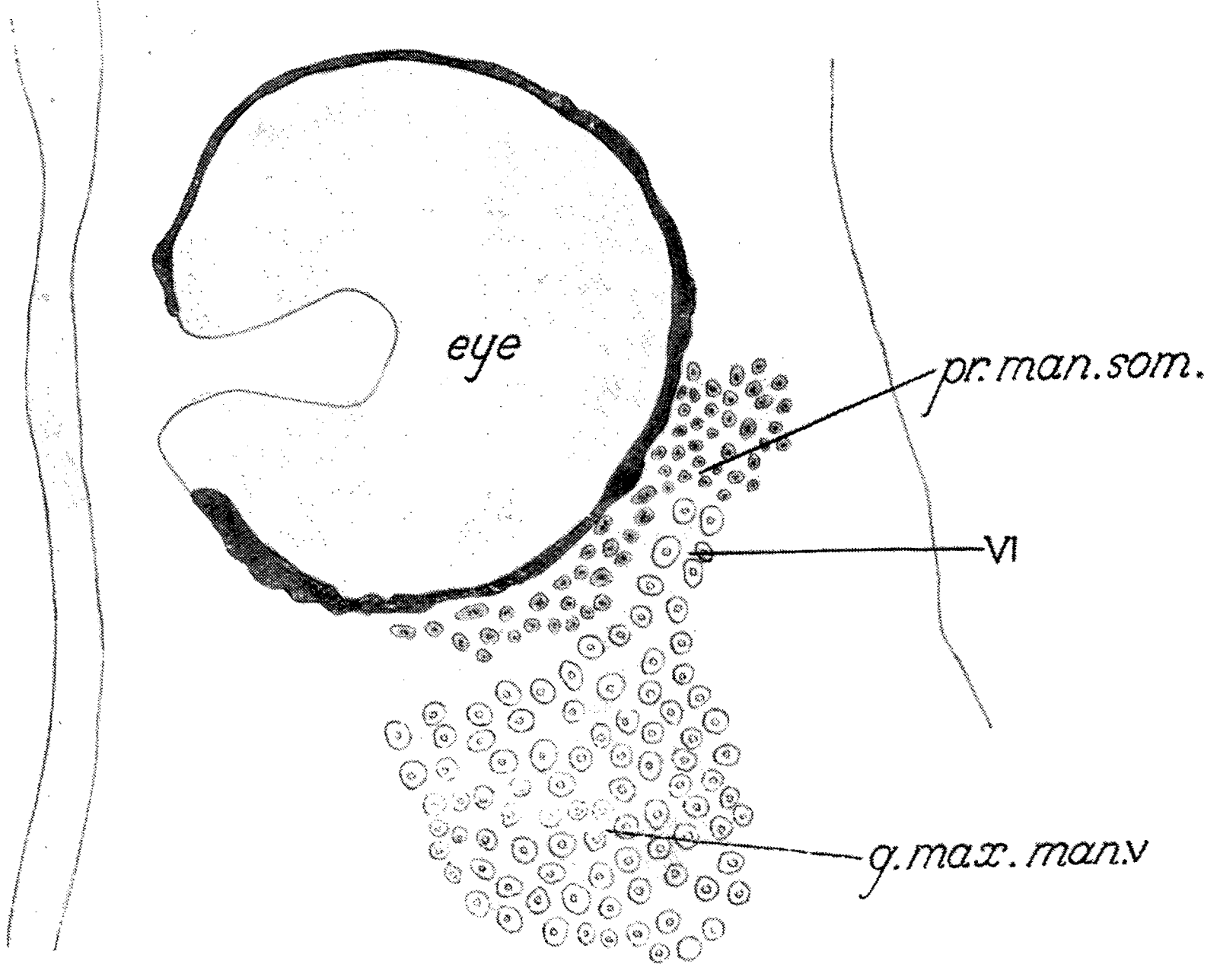

162

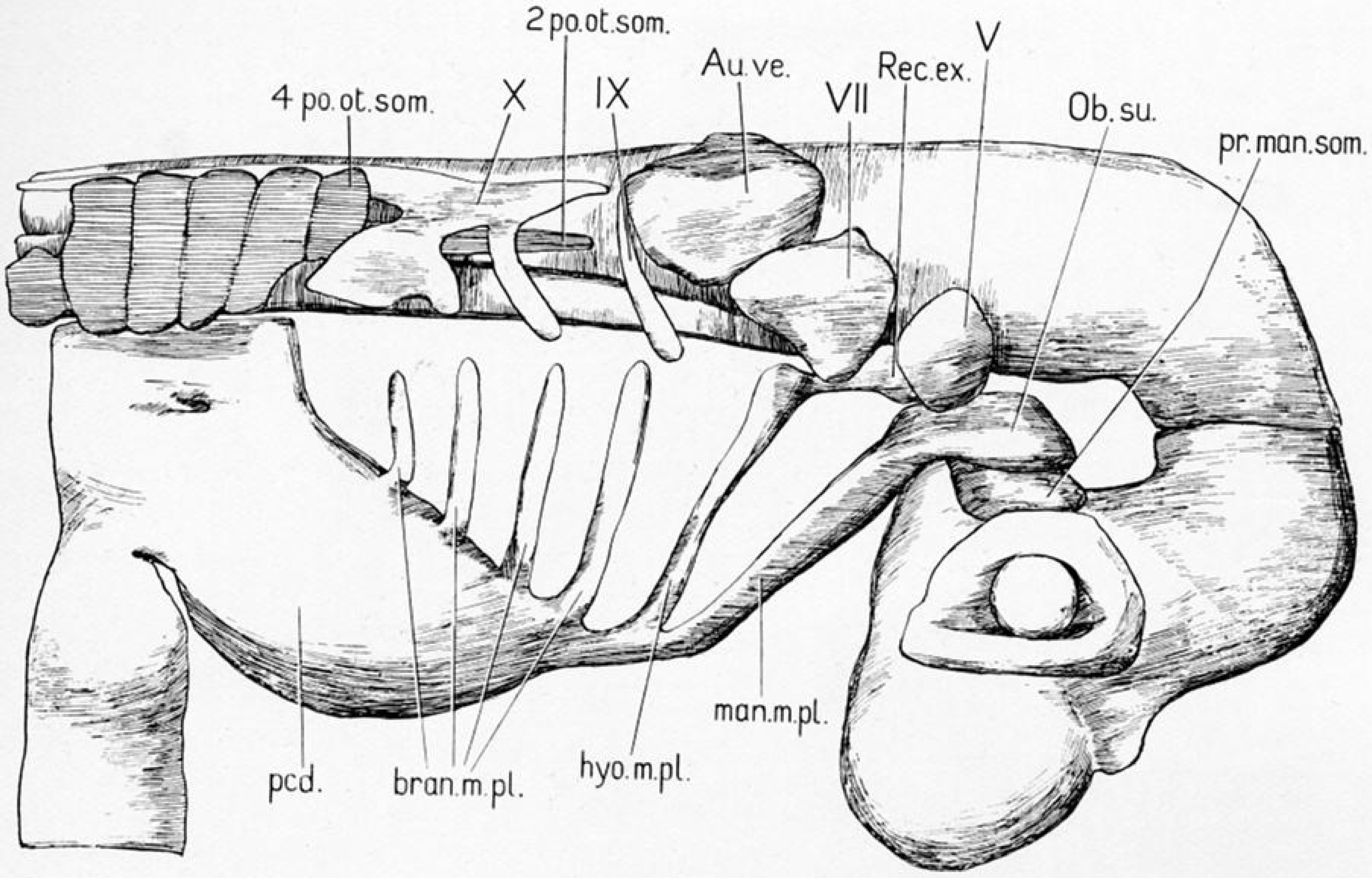
2 po.ot.som.
4 po.ot.som.
X
IX
Au.ve.
VII
Rec.ex.
V
Ob.su.
pr.man.som.
pcd.
bran.m.pl.
hyo.m.pl.
man.m.pl.

1

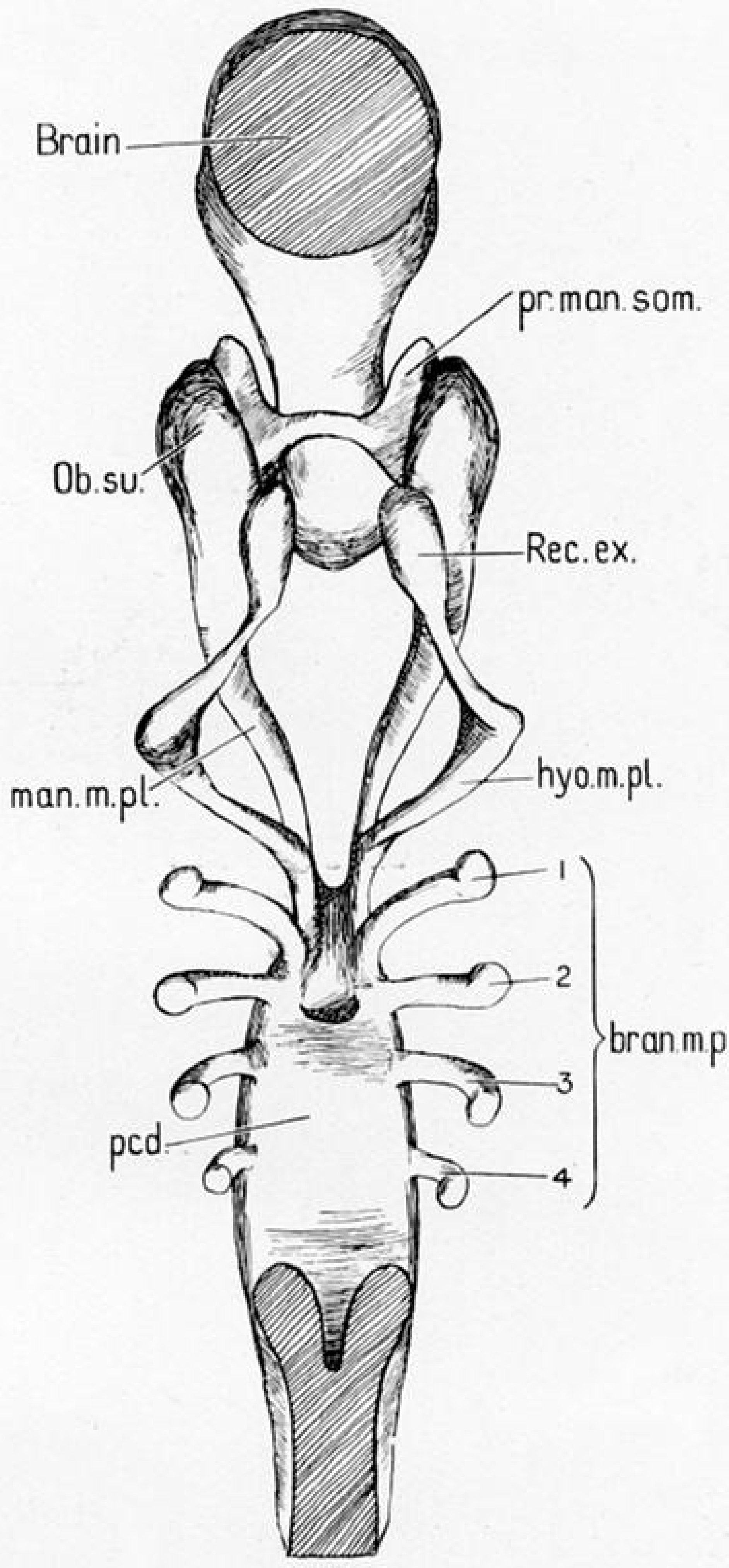
Brain
pr.man.som.
Ob.su.
Rec.ex.
man.m.pl.
hyo.m.pl.
1
2
3
4
bran.m.pl
pcd.

2

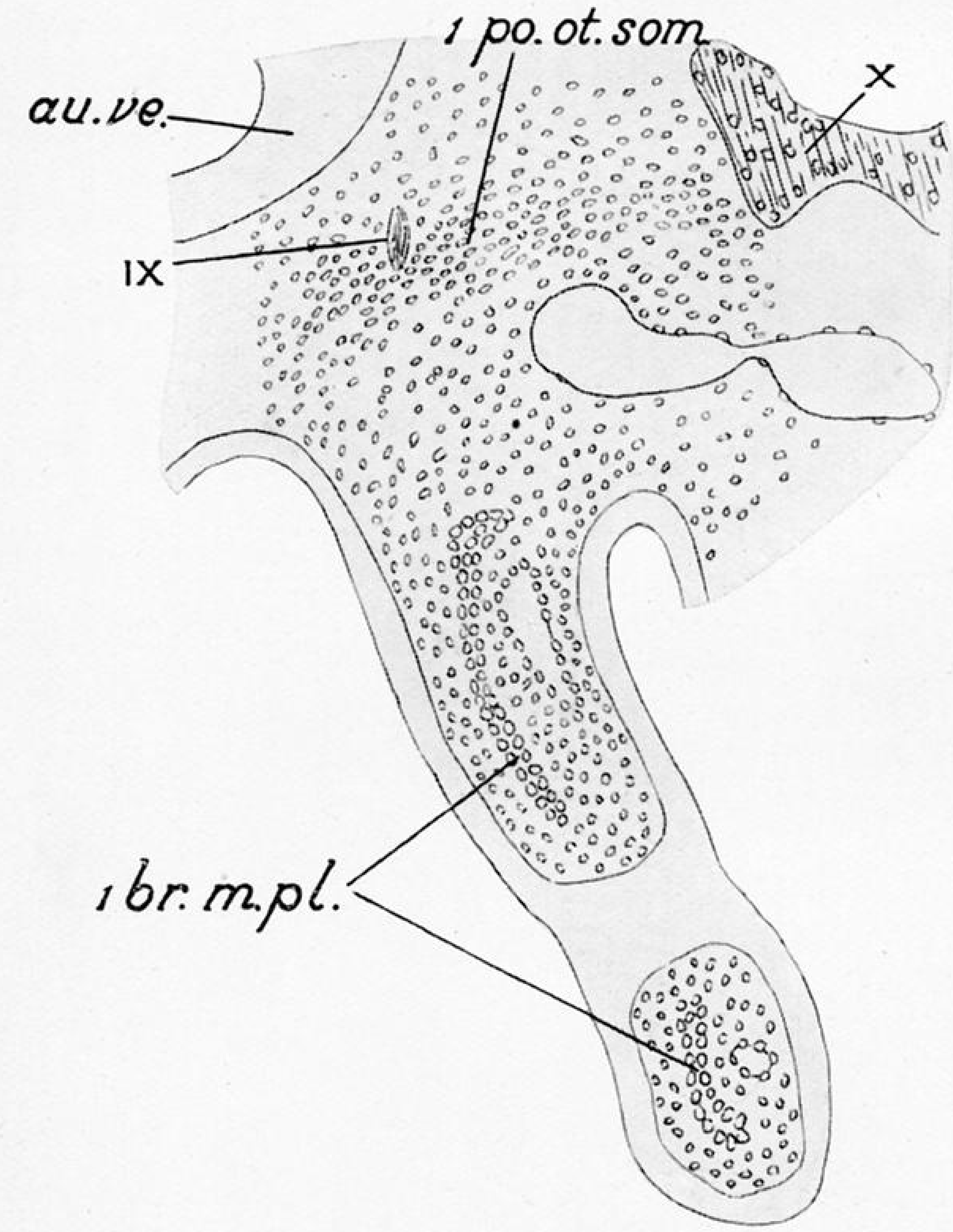
1 po.ot.som.
au.ve.
X
IX
1 br.m.pl.

3

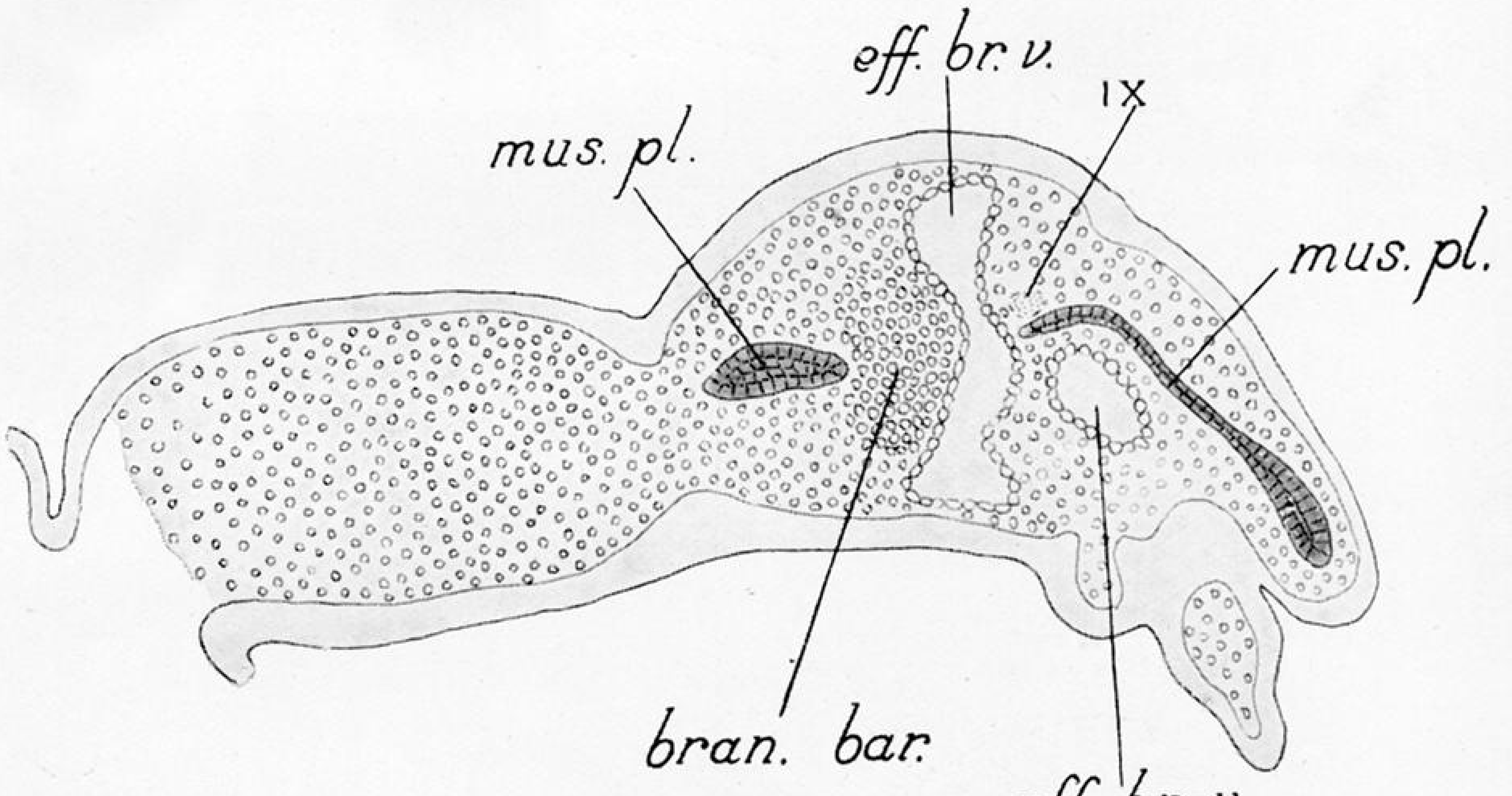
eff. br. v.
IX
mus. pl.
mus. pl.
bran. bar.
aff. br. v.

6

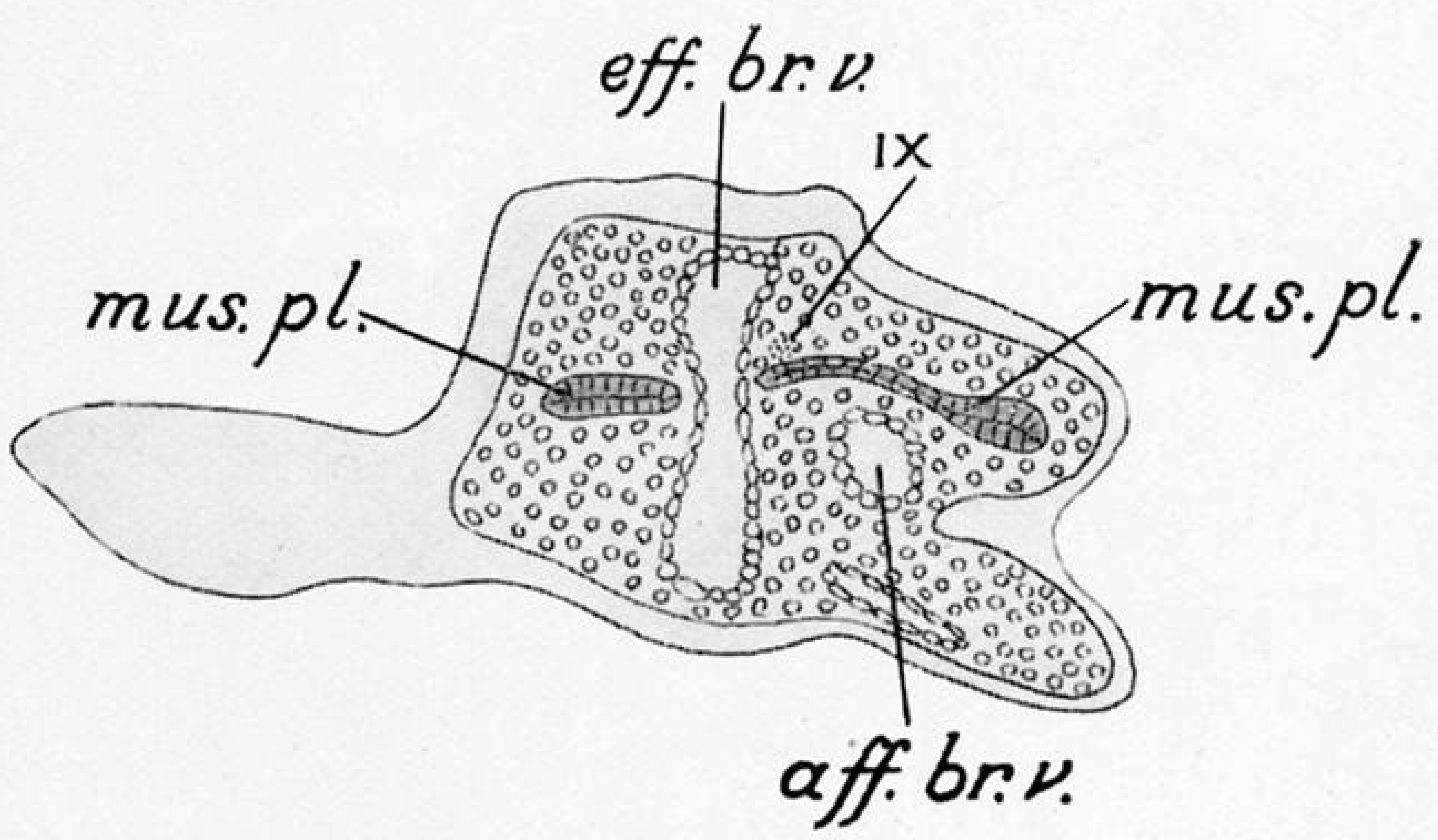
eff. br. v.
IX
mus. pl.
mus. pl.
aff. br. v.

4

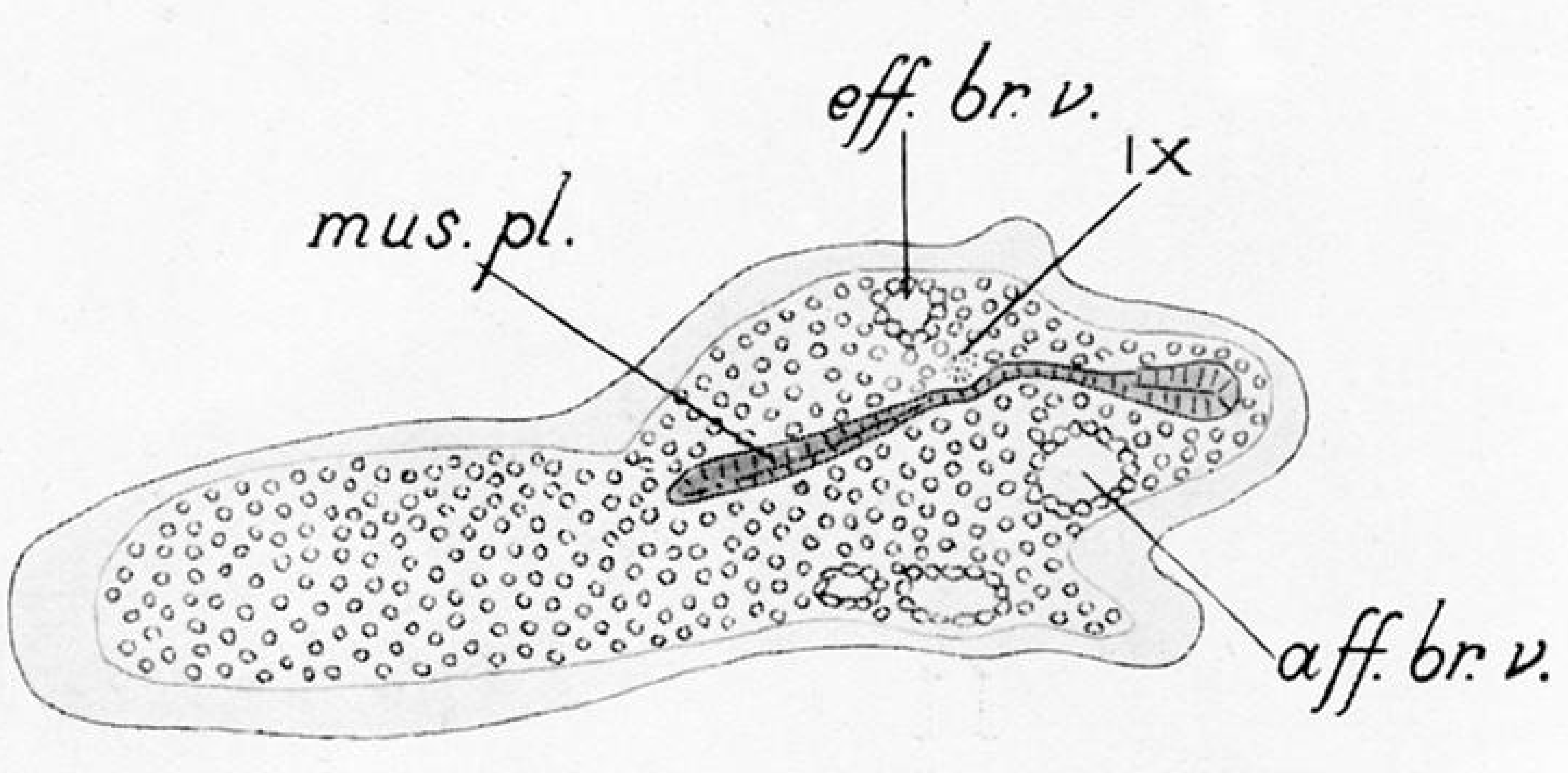
eff. br. v.
IX
mus. pl.
aff. br. v.

5

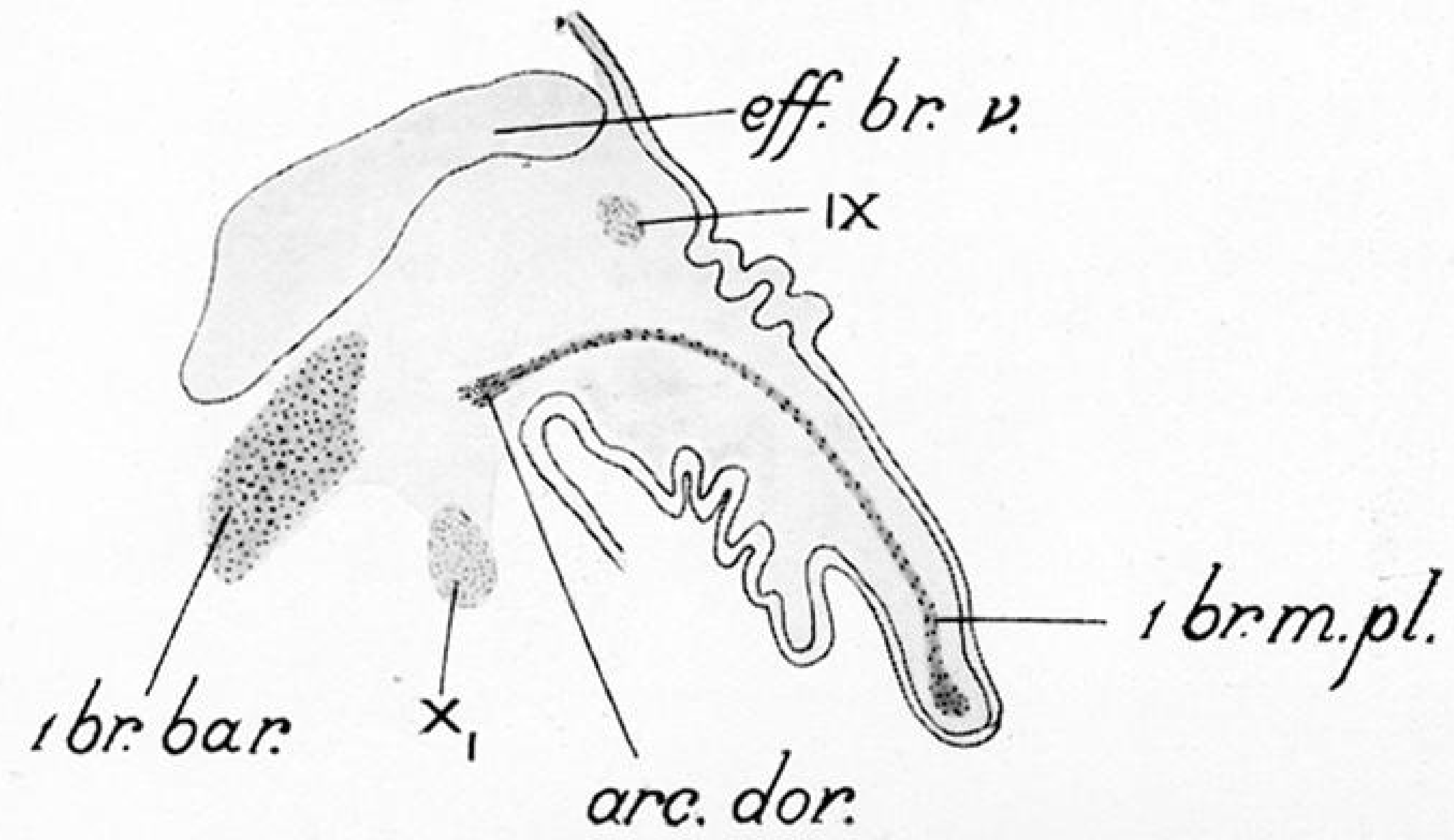
eff. br. v.
IX
1 br. m. pl.
1 br. bar.
X_1
arc. dor.

7

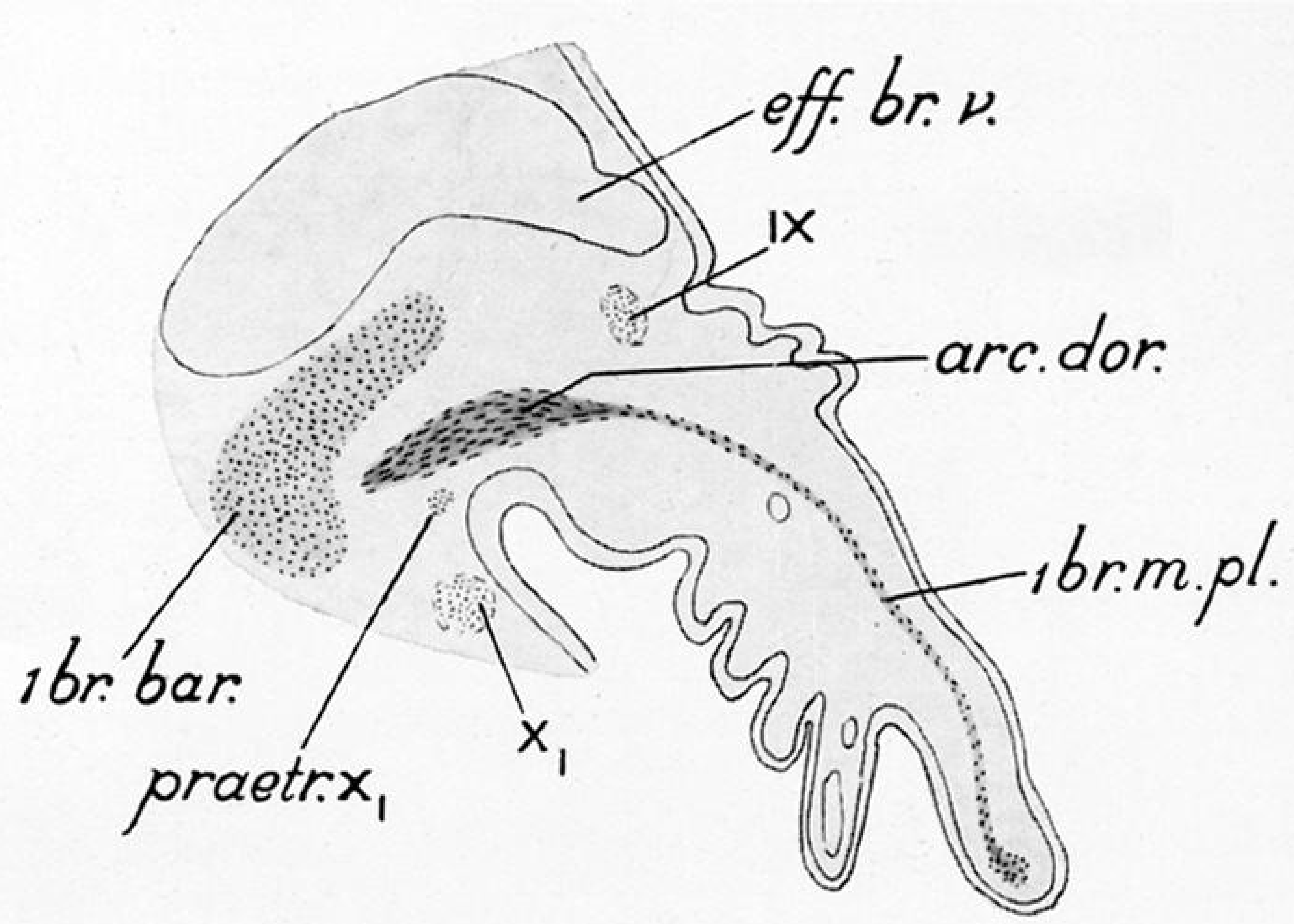
eff. br. v.
IX
arc. dor.
1 br. m. pl.
1 br. bar.
X_1
praetr. X_1

8

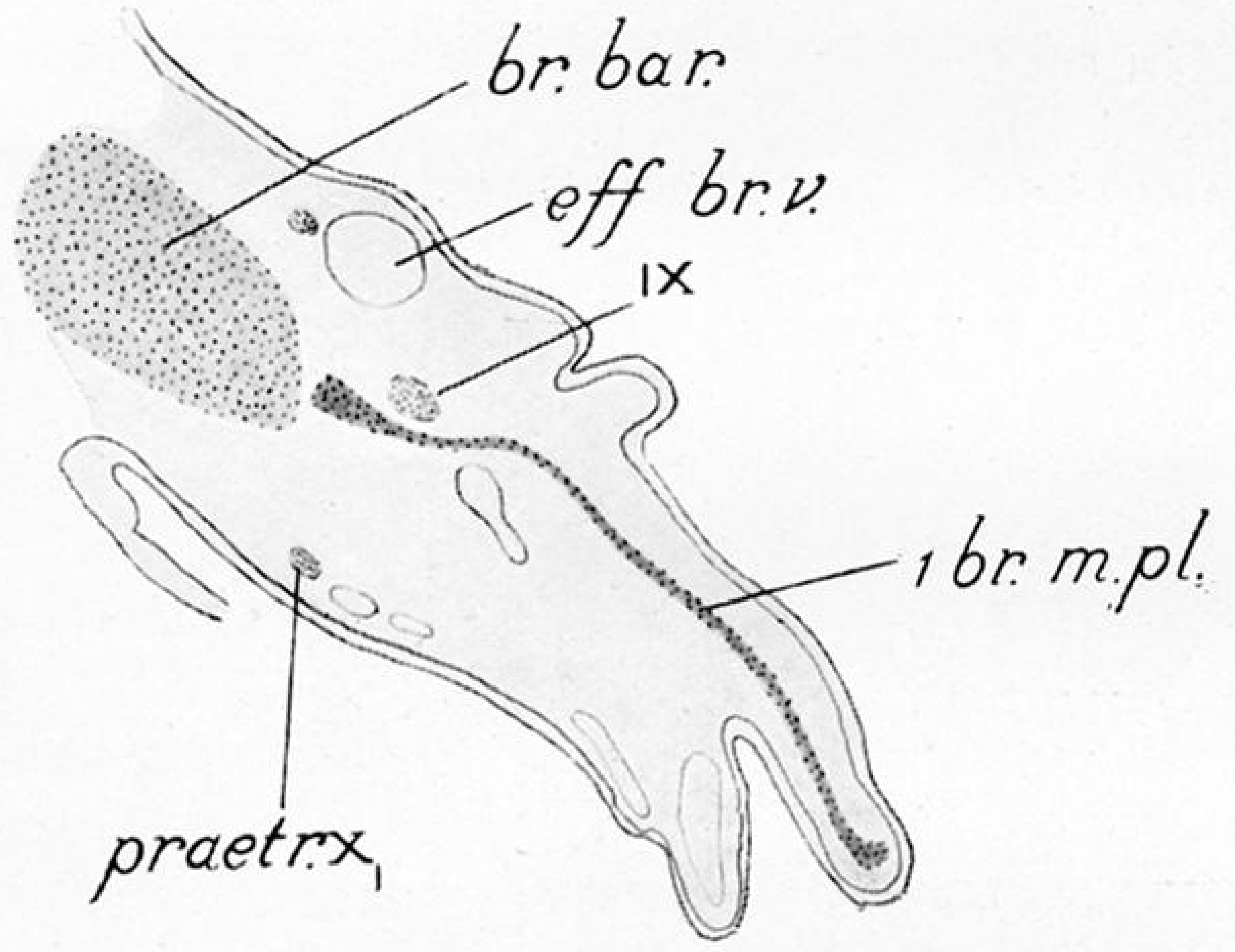
br. bar.
eff. br. v.
IX
1 br. m. pl.
praetr. X_1

9

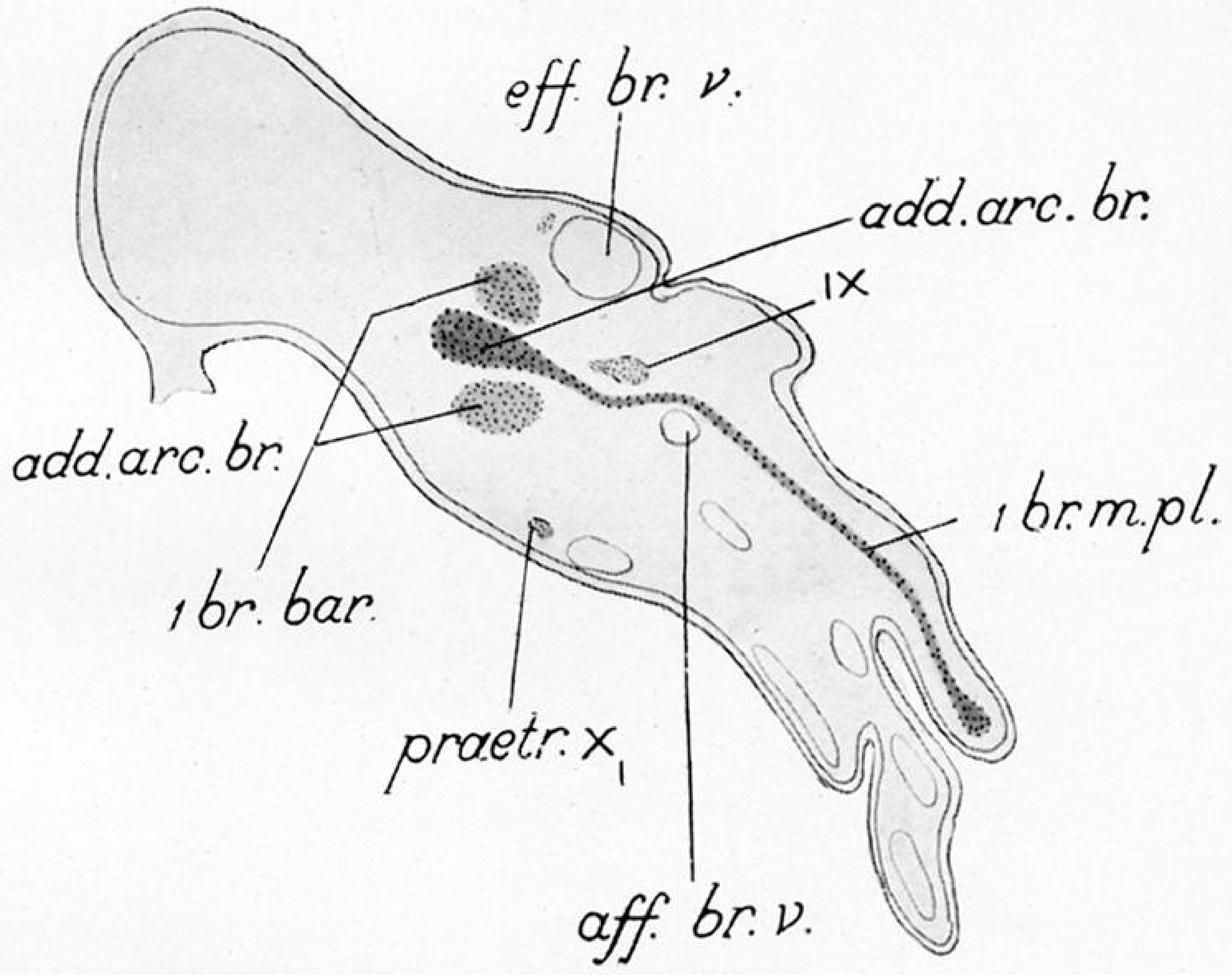
eff. br. v.
add. arc. br.
IX
add. arc. br.
1 br. m. pl.
1 br. bar.
praetr. X_1
aff. br. v.

10

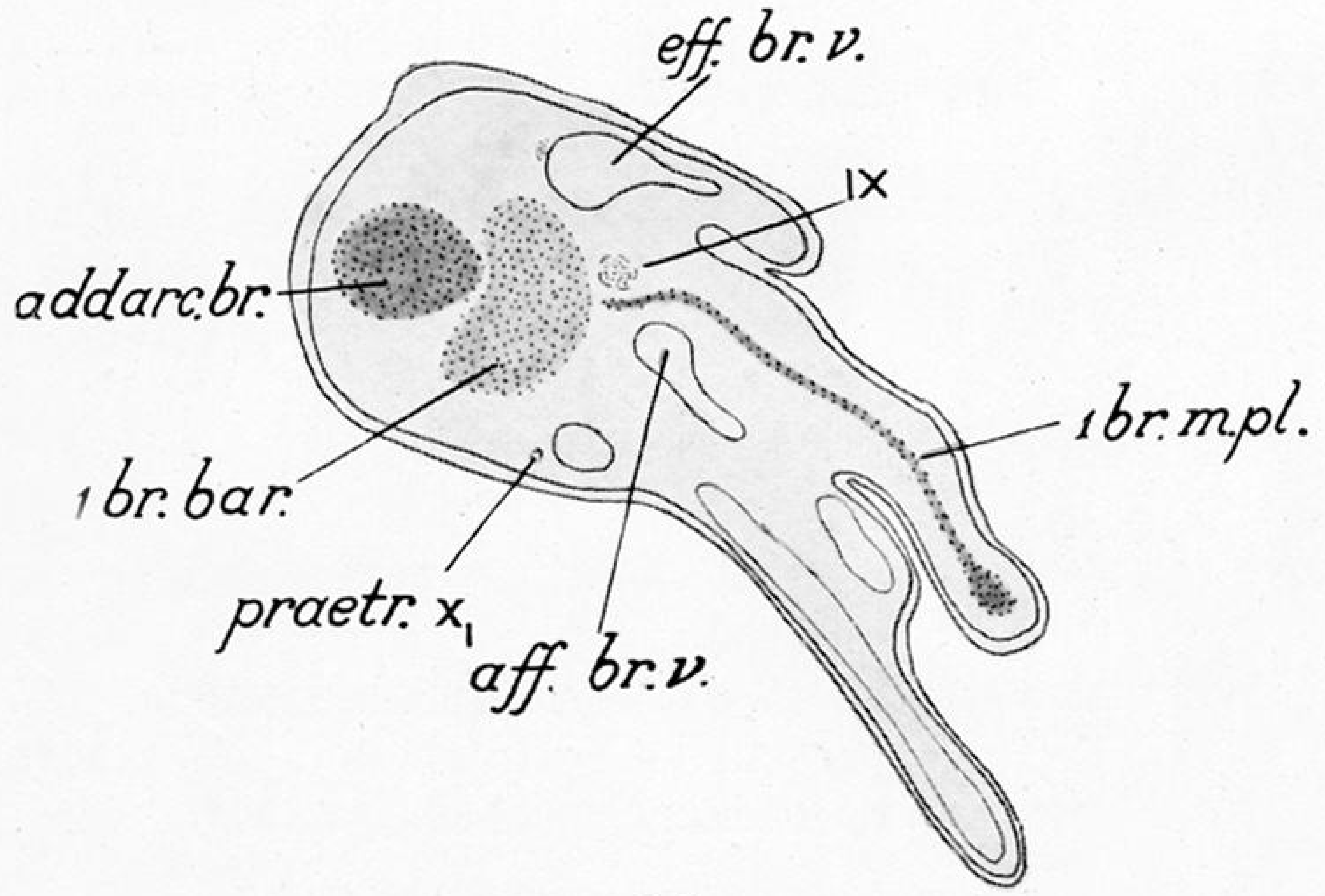
eff. br. v.
IX
add. arc. br.
1 br. m. pl.
1 br. bar.
praetr. X_1
aff. br. v.

11

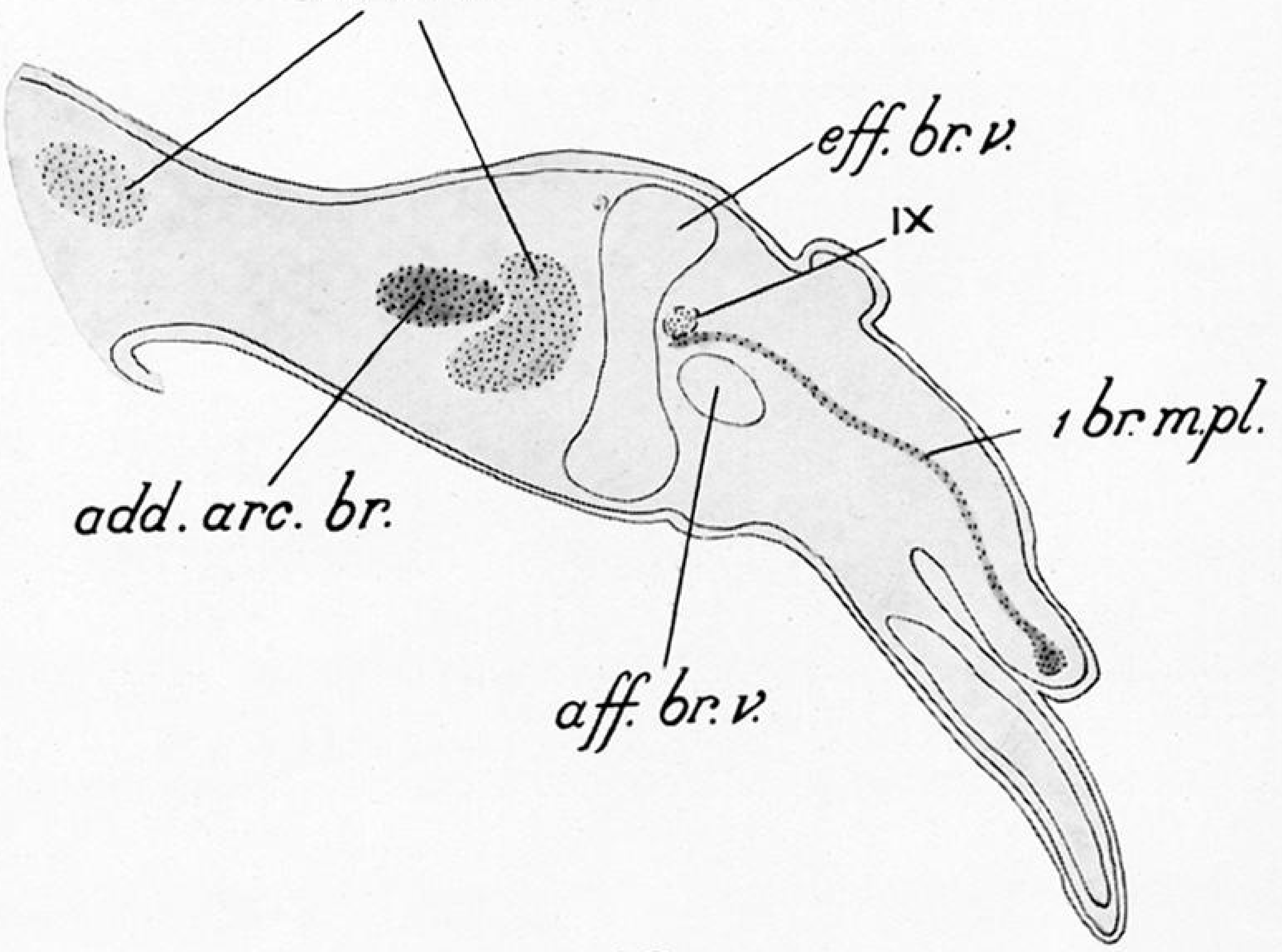
1 br. bar.
eff. br. v.
IX
1 br. m. pl.
add. arc. br.
aff. br. v.

12

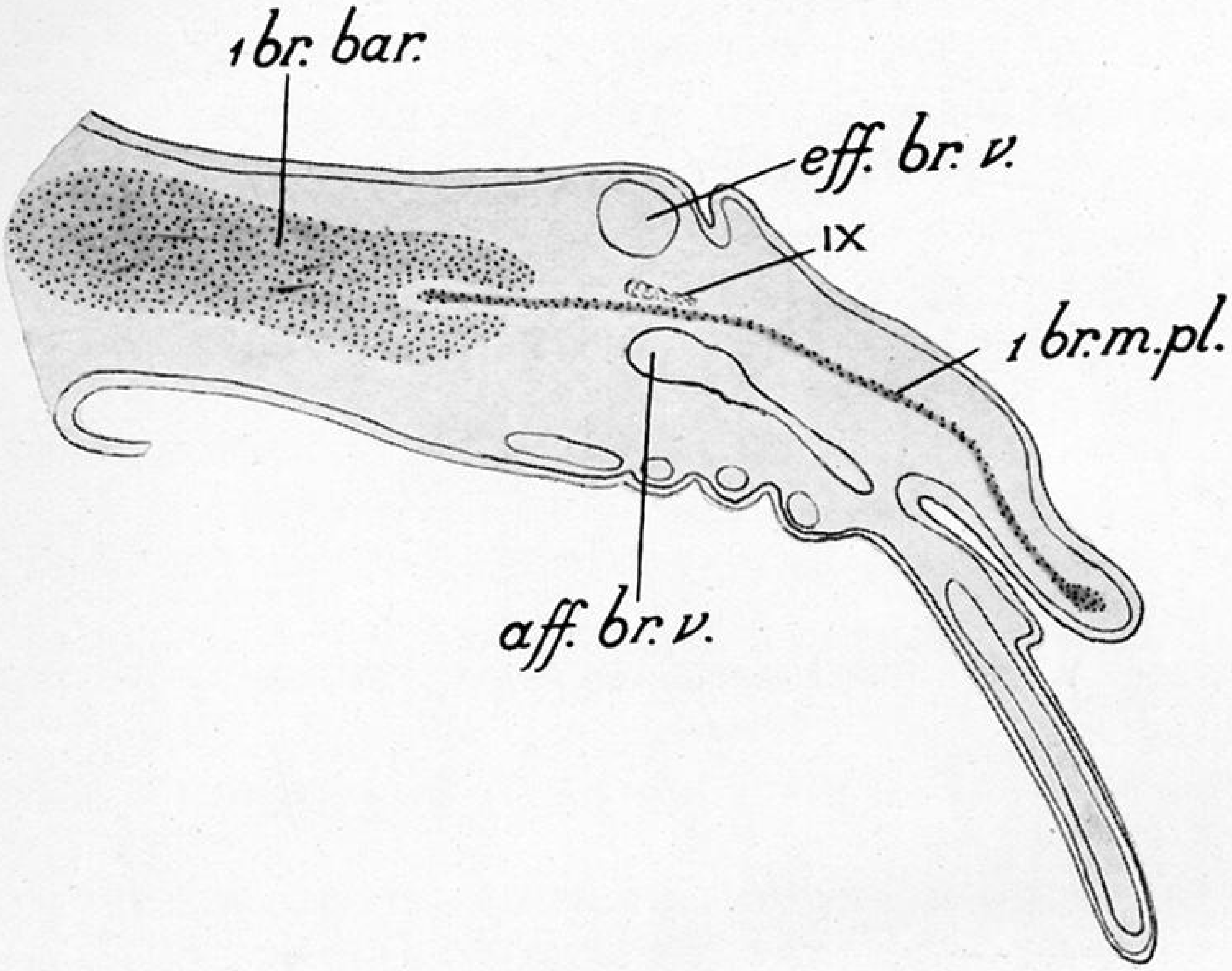

13

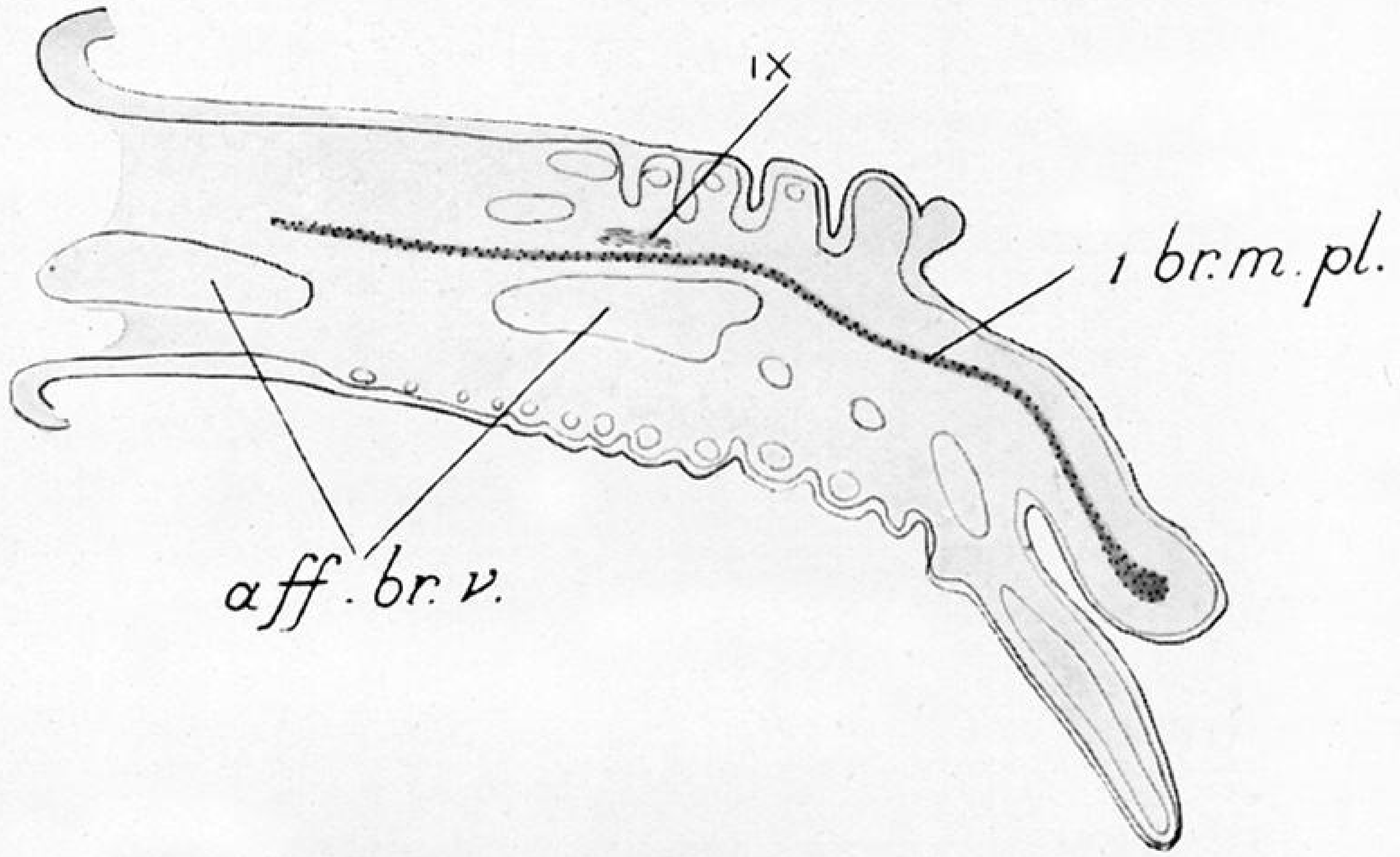

14

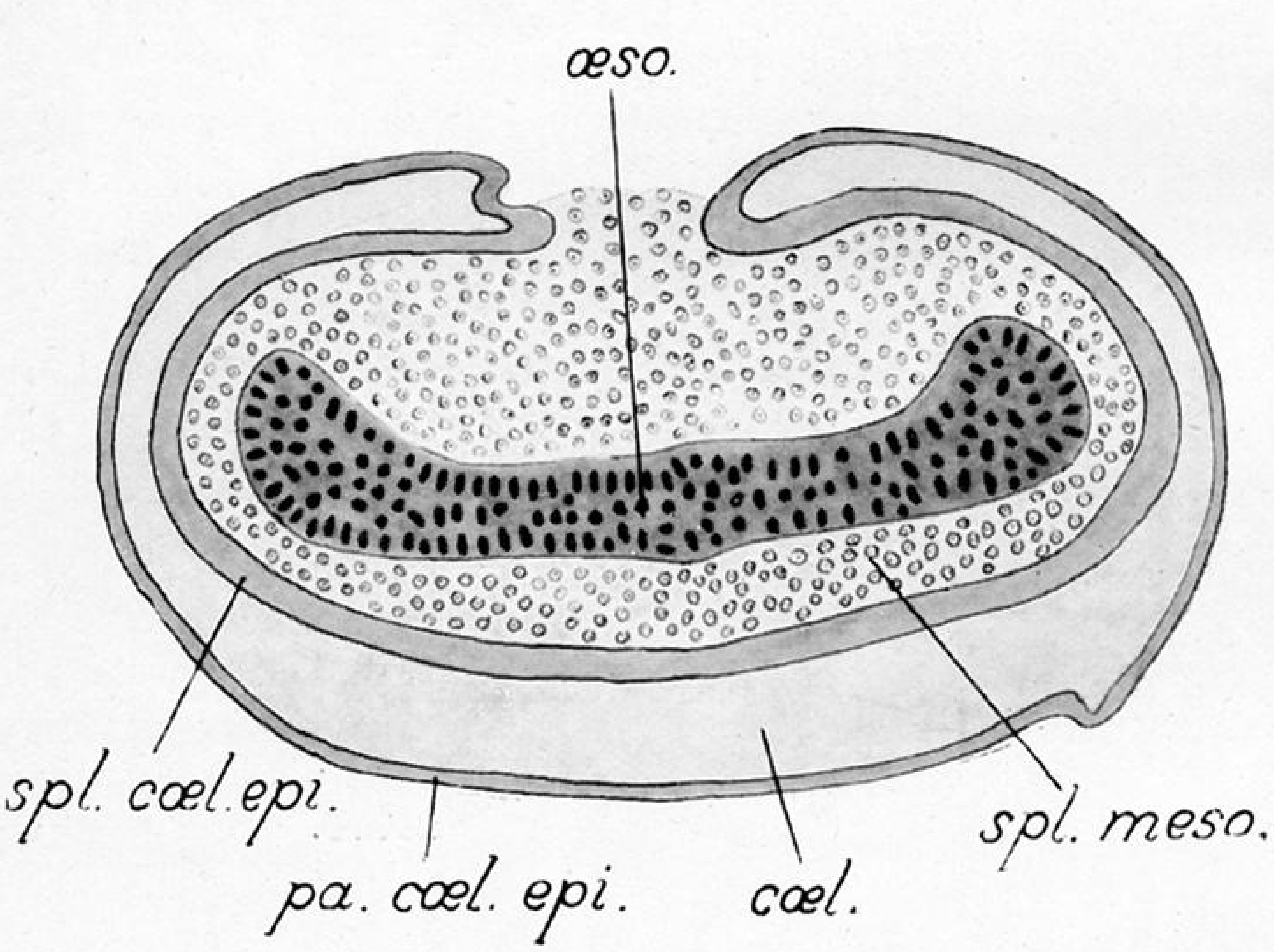

15

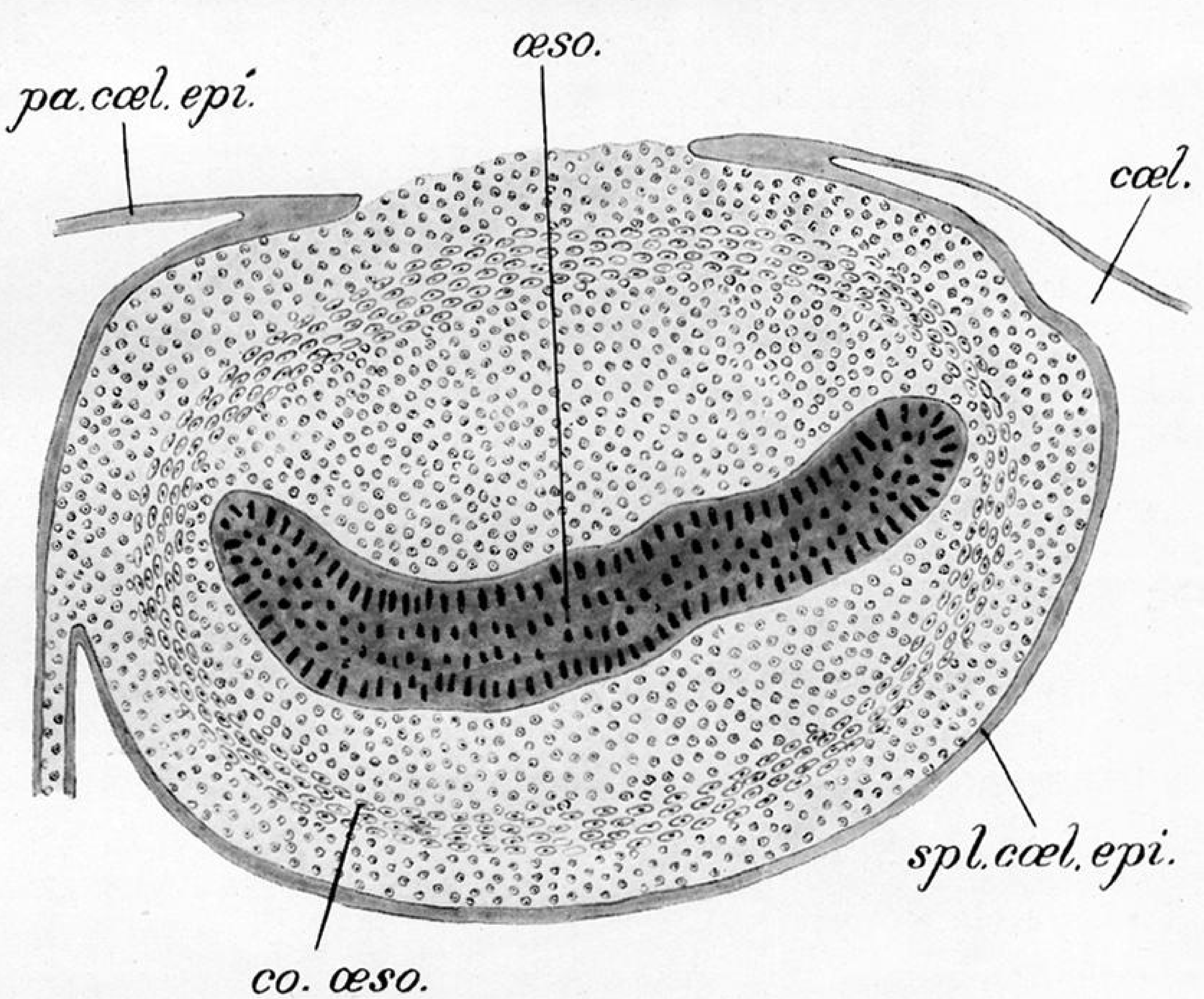

16

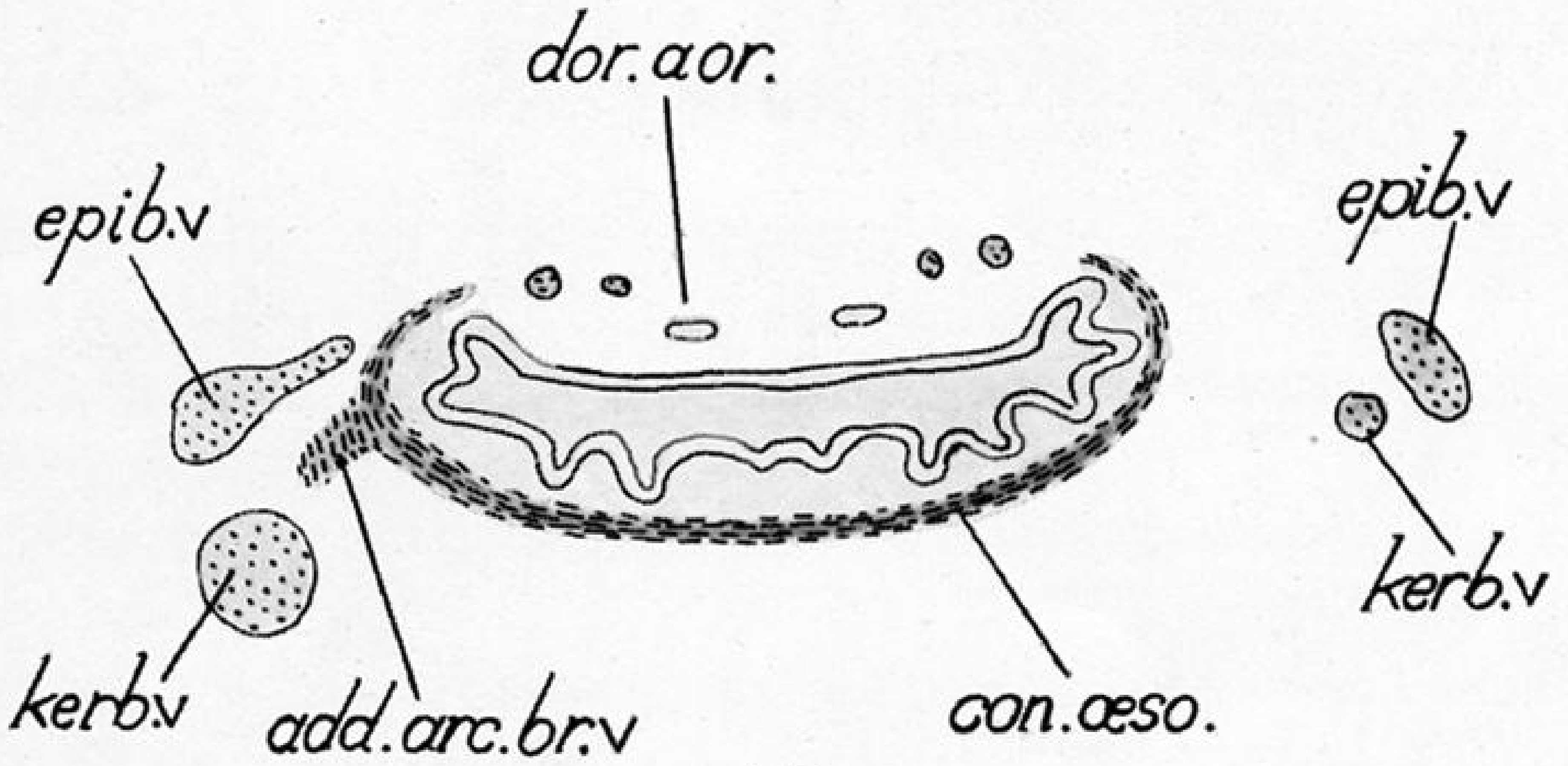

17

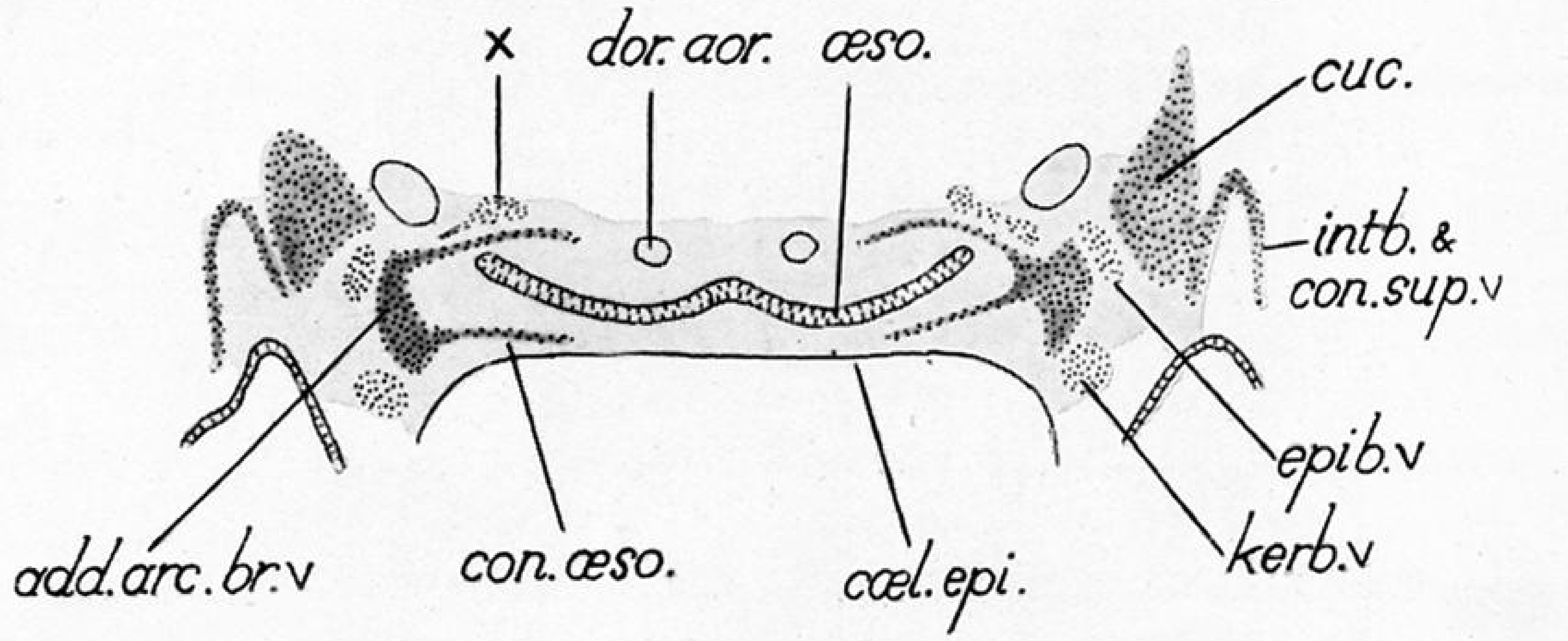

18

19

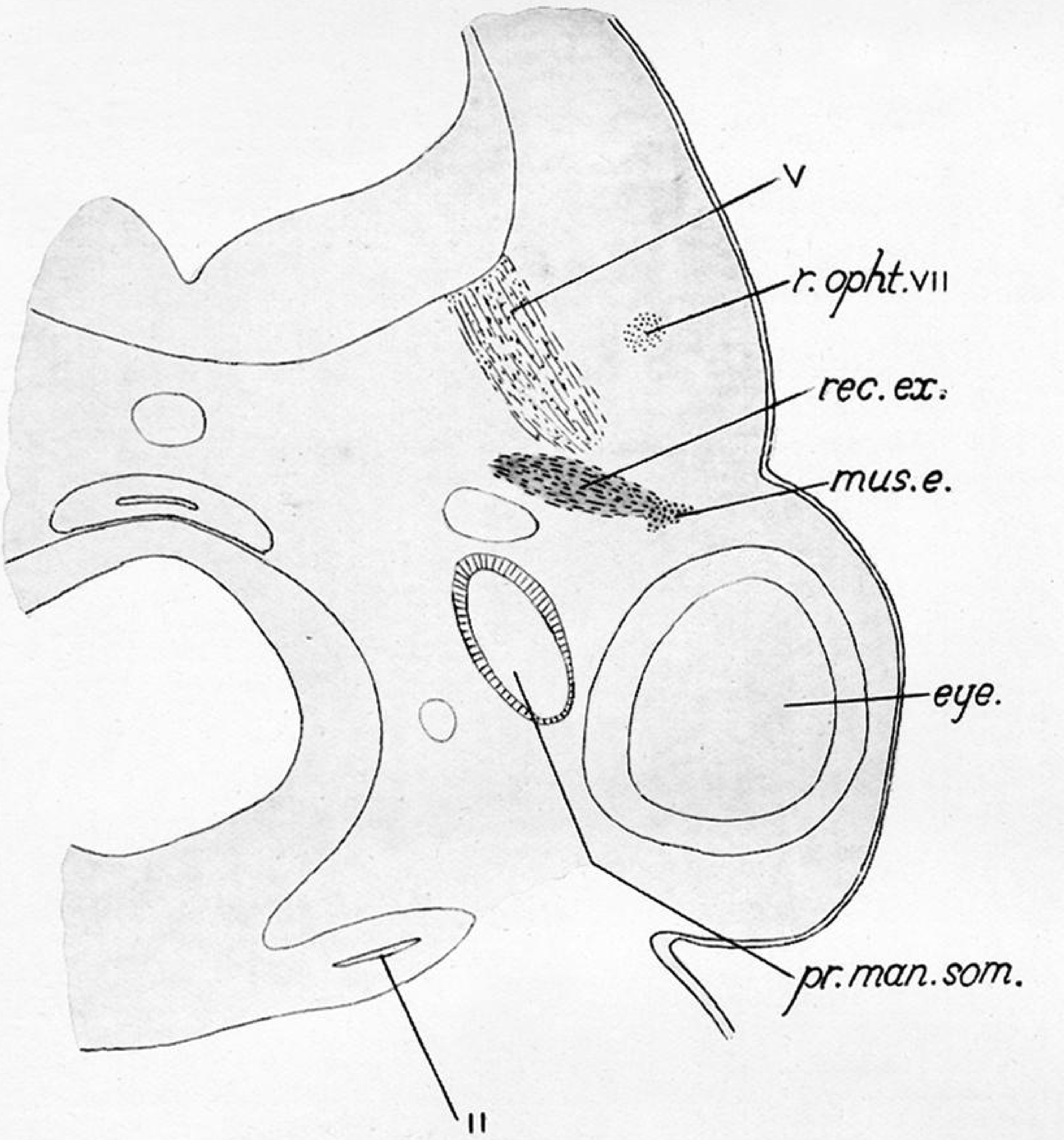

20

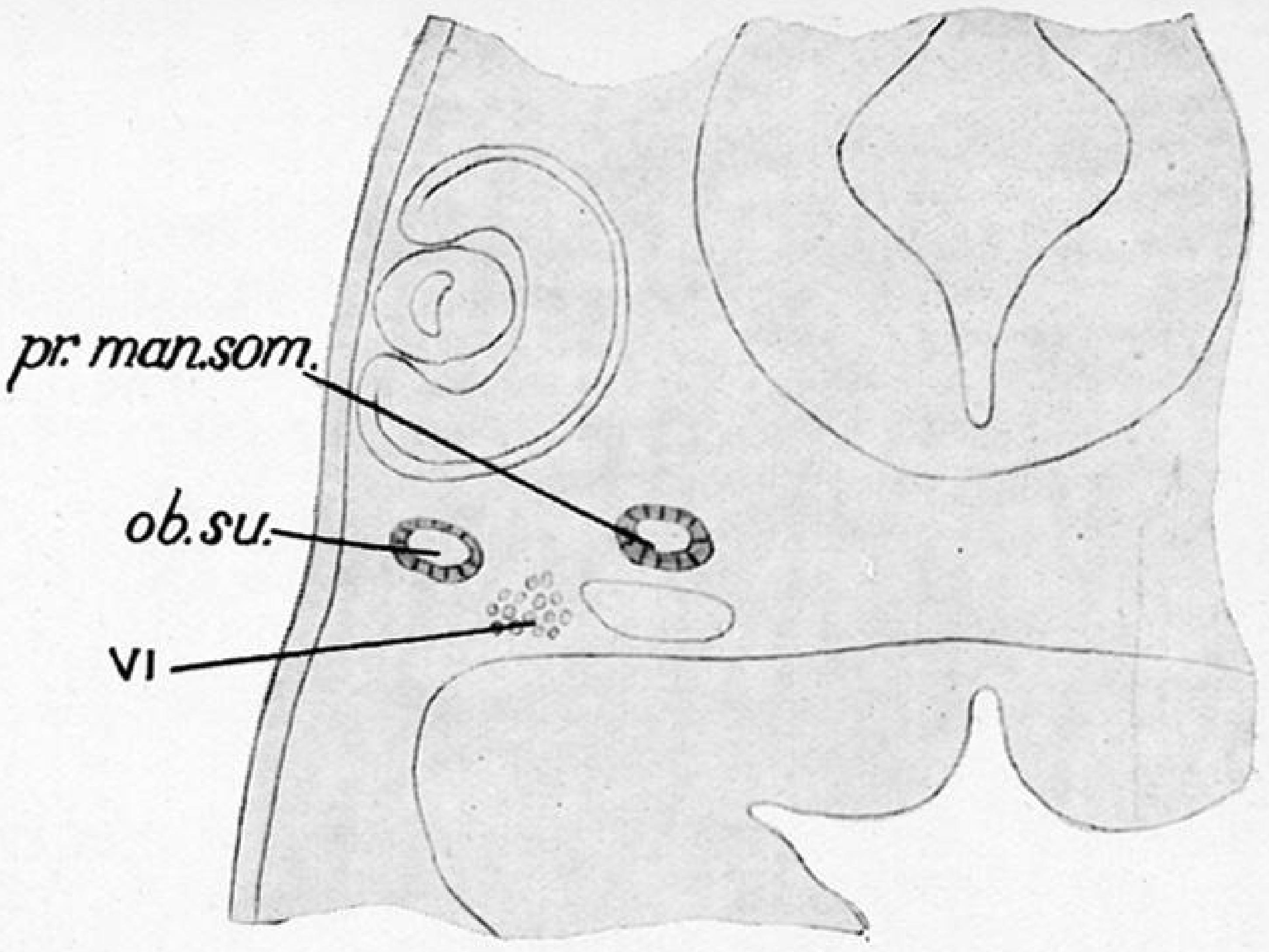

21

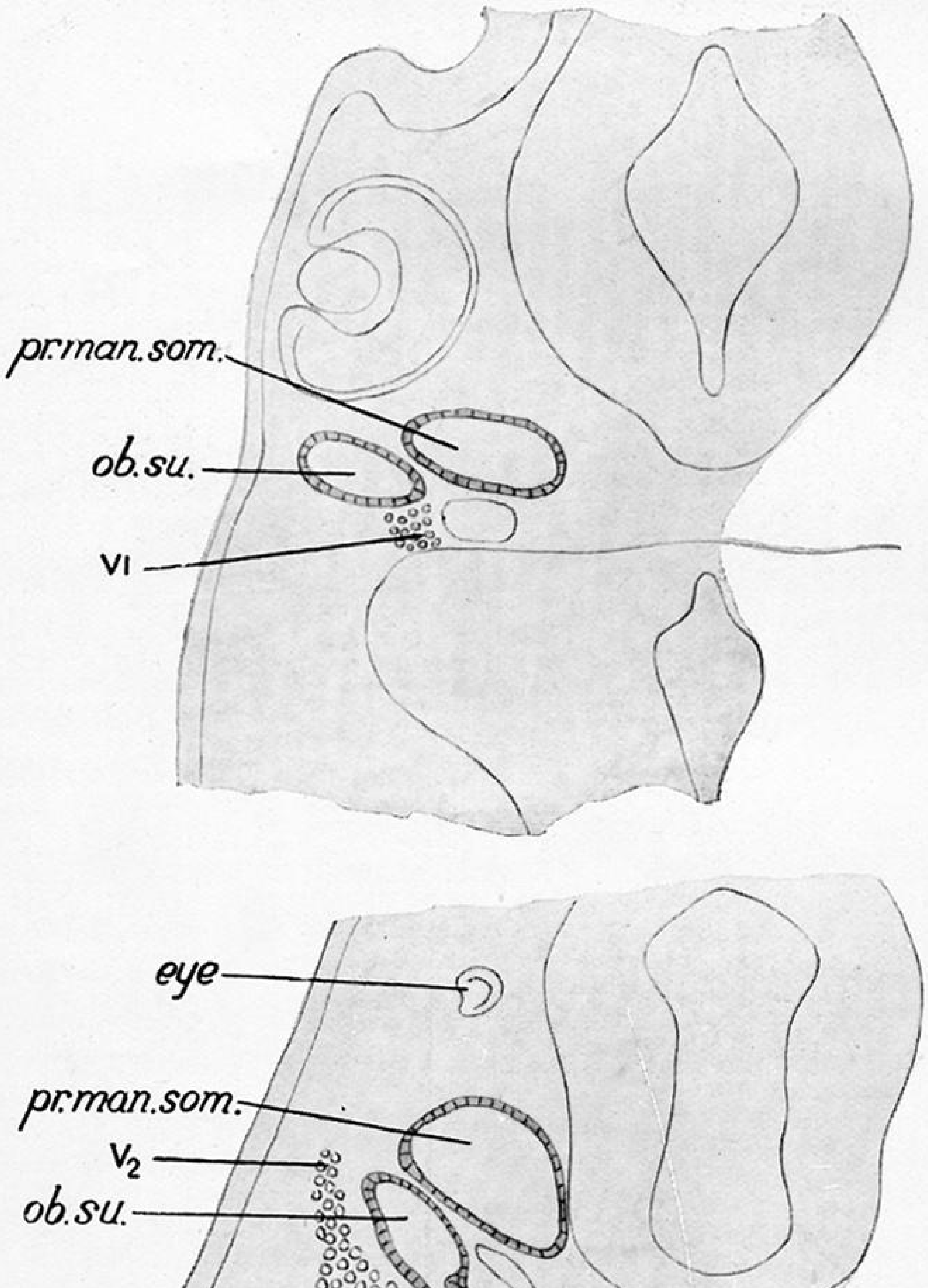

22

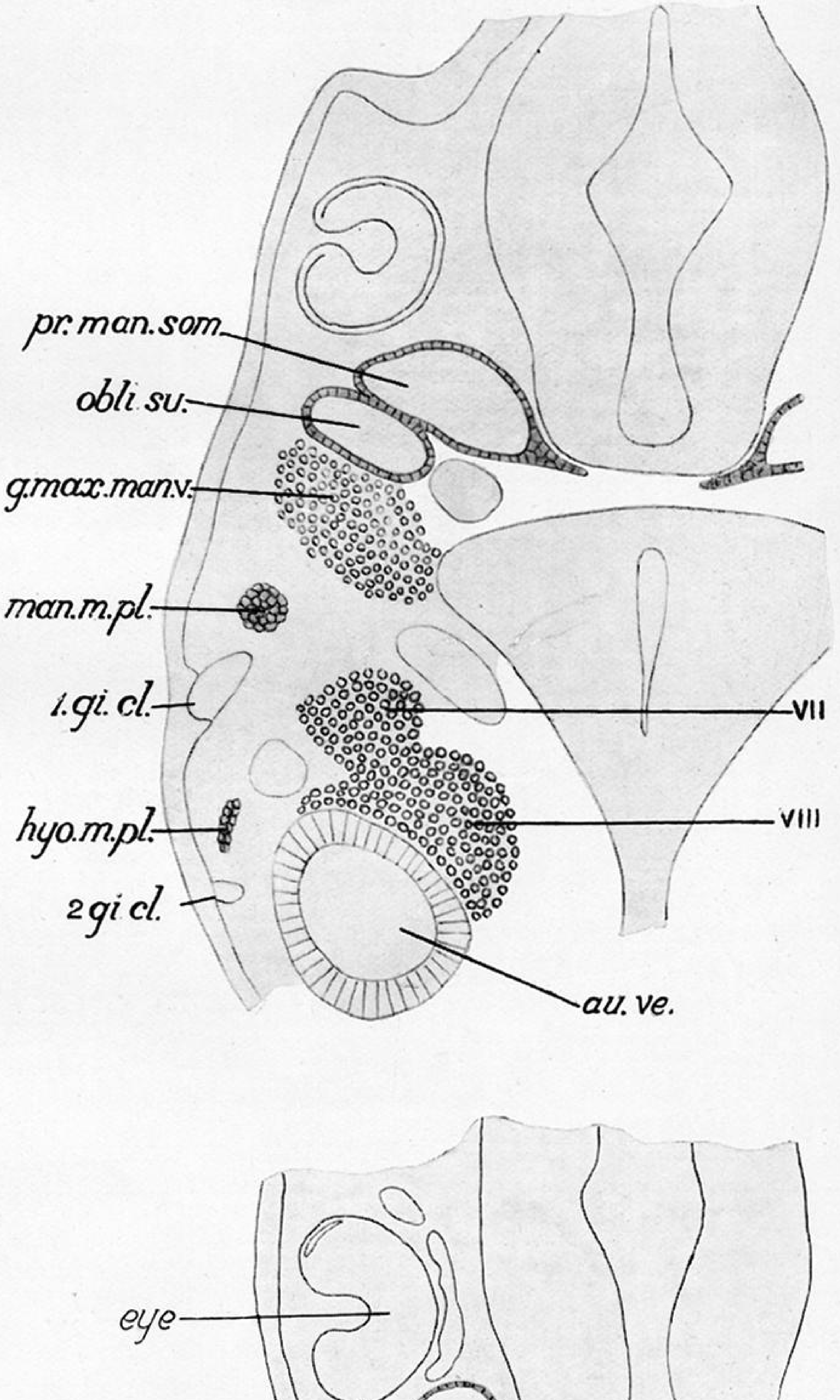

23

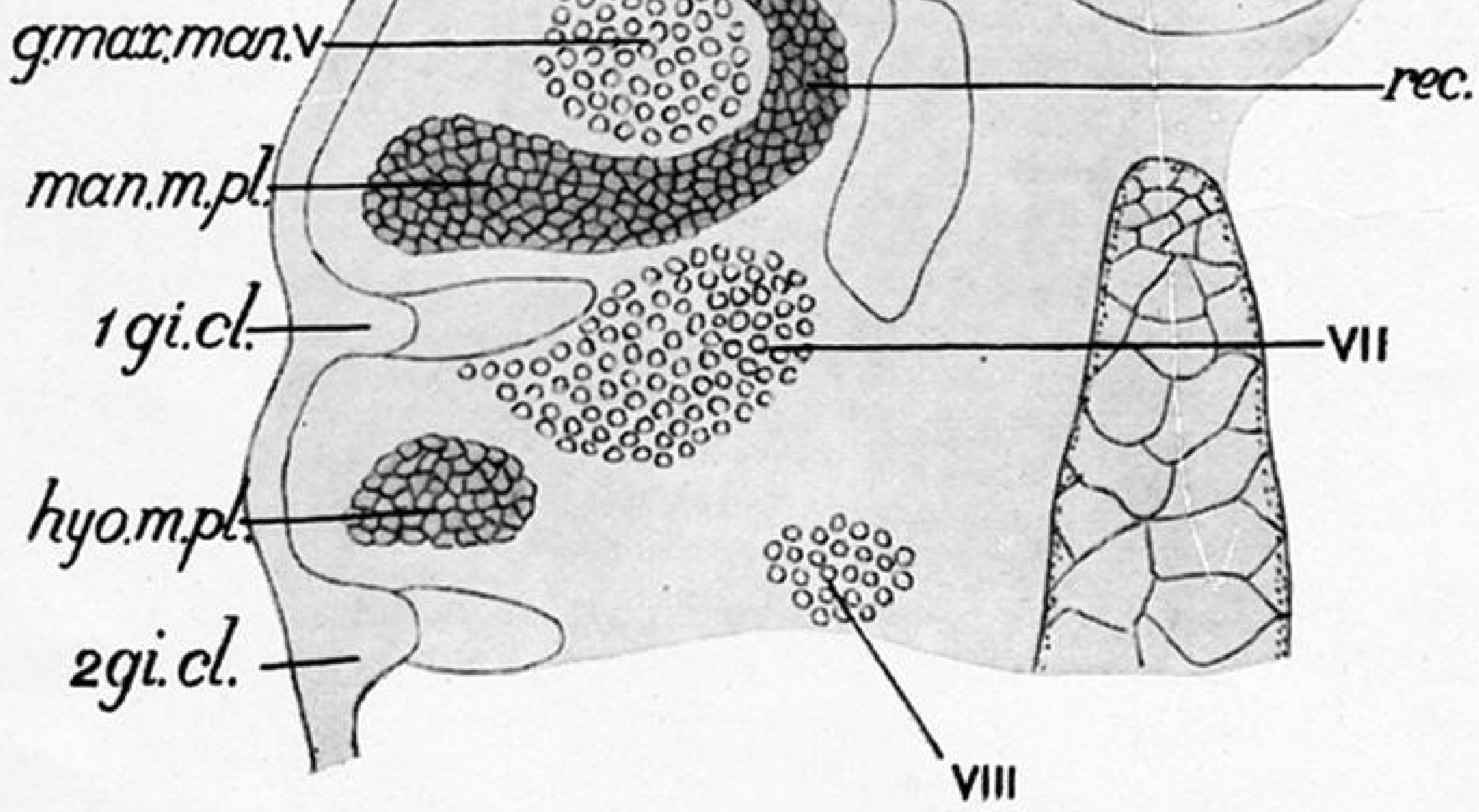

24

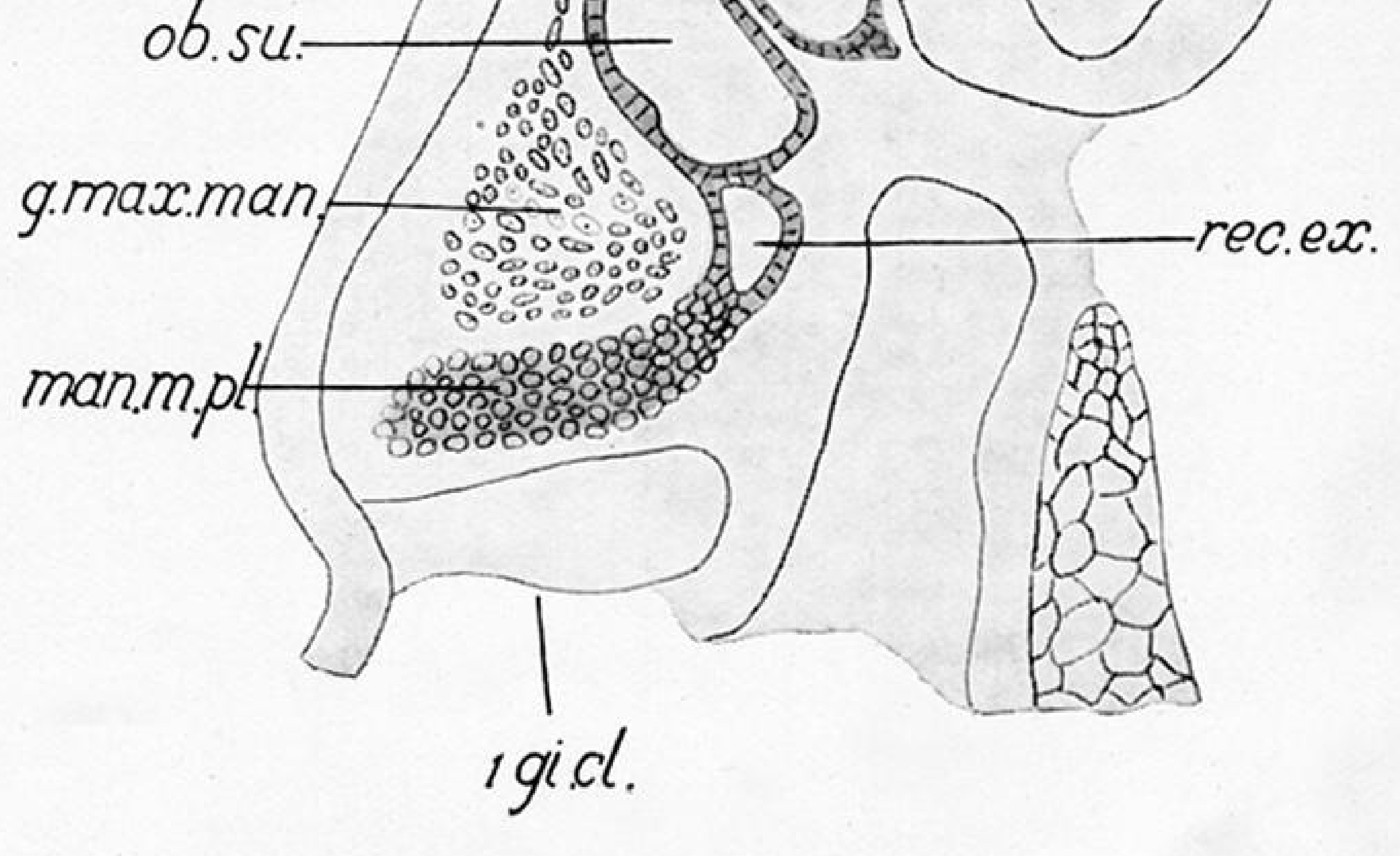

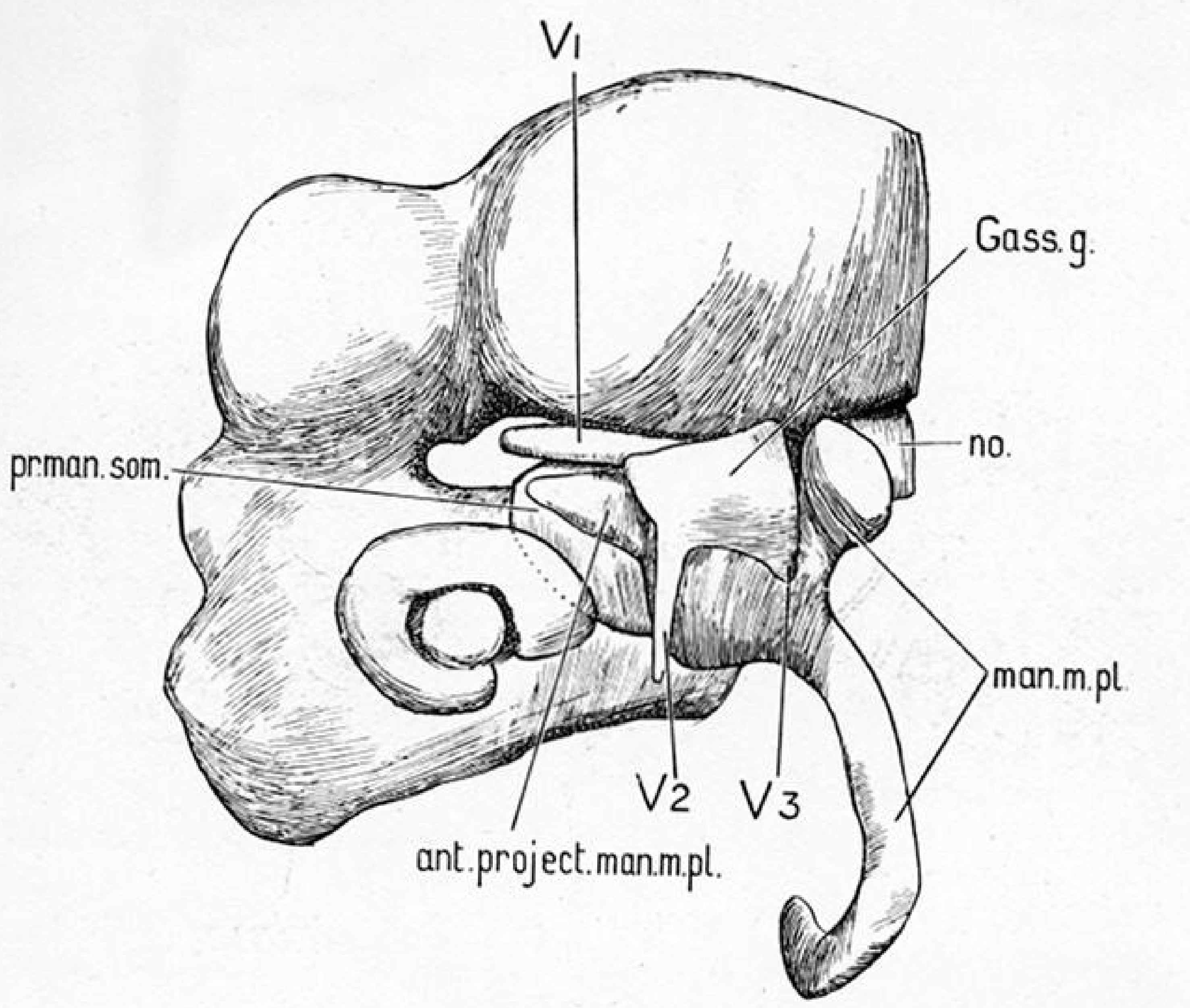

25

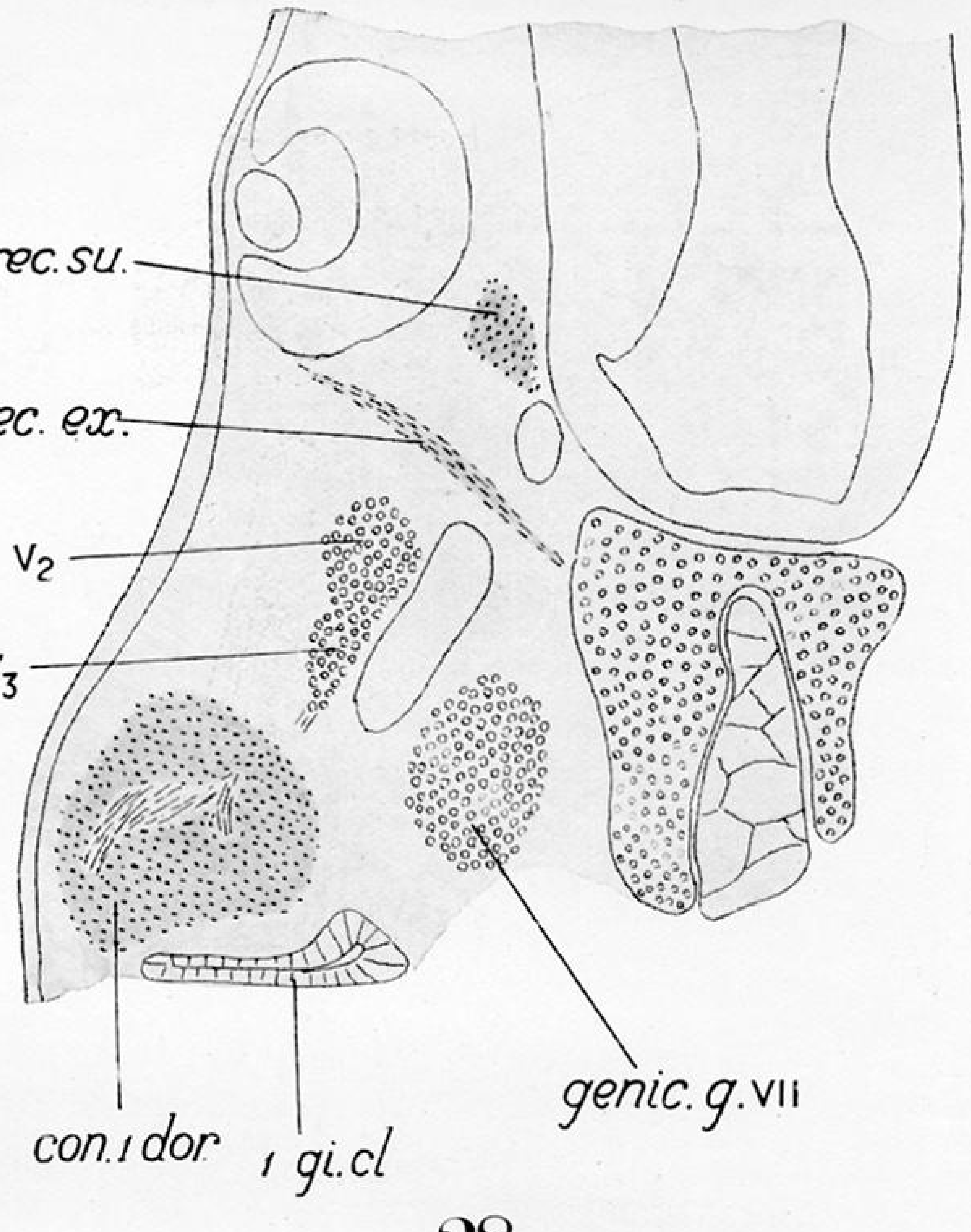

28

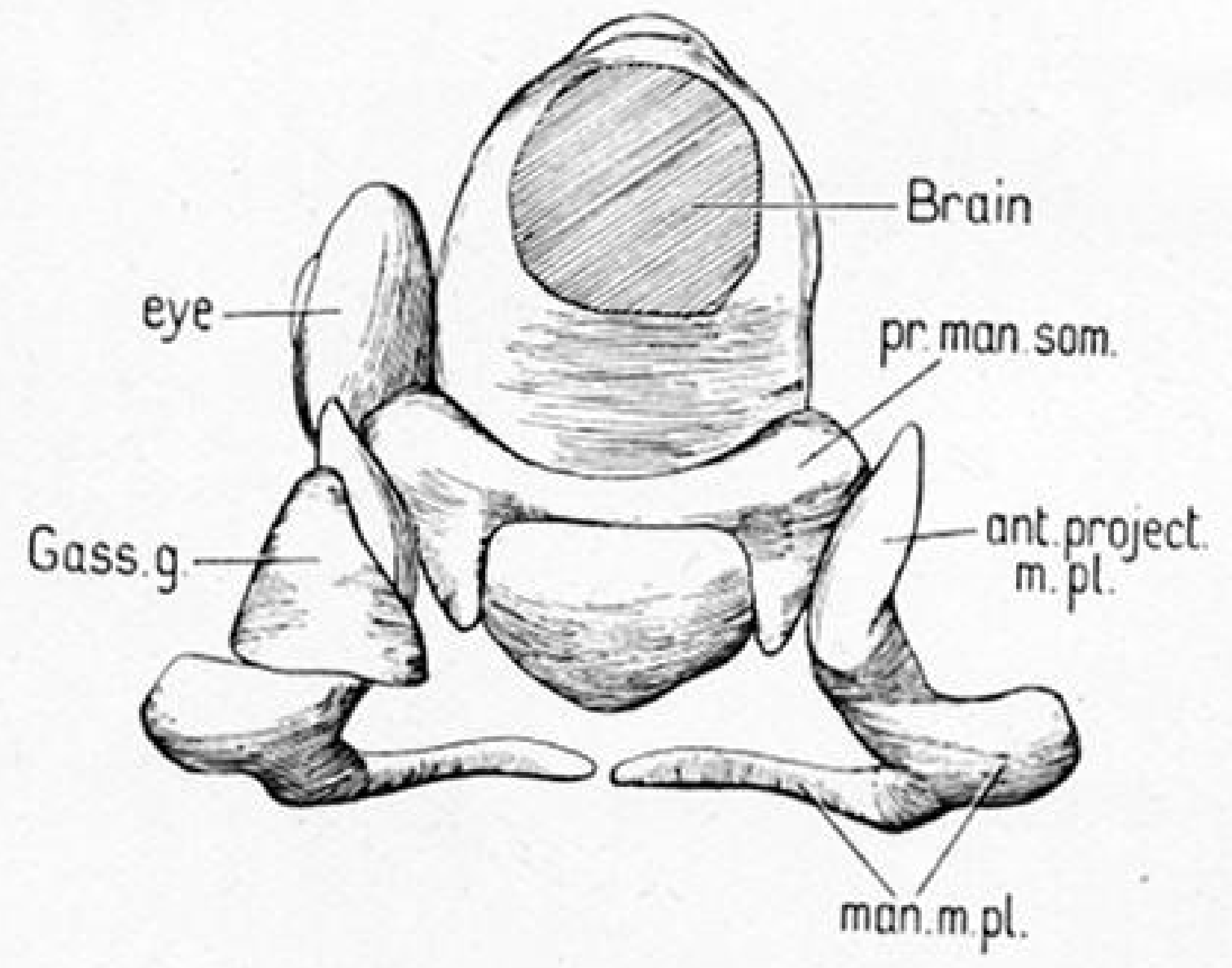

26

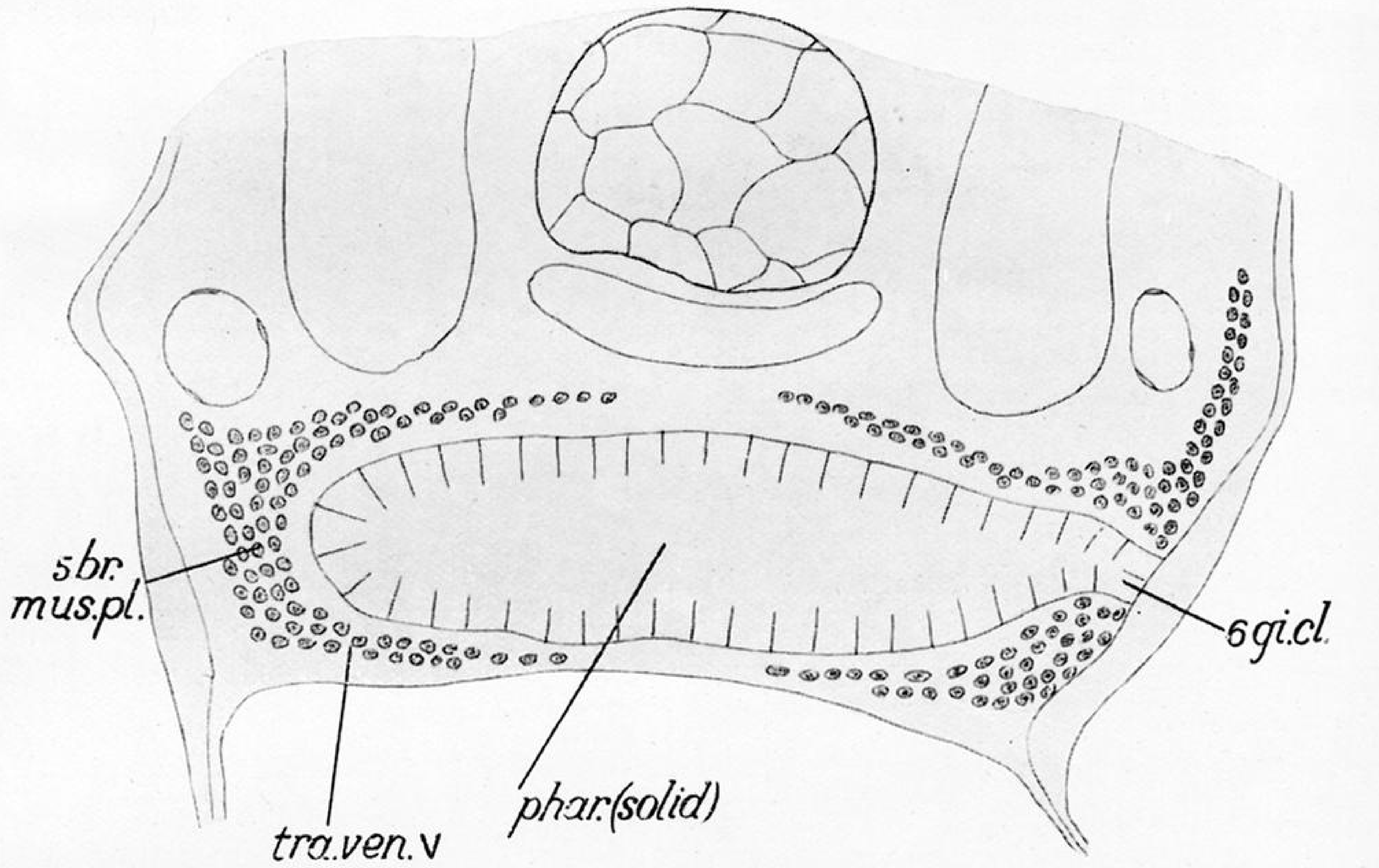

29

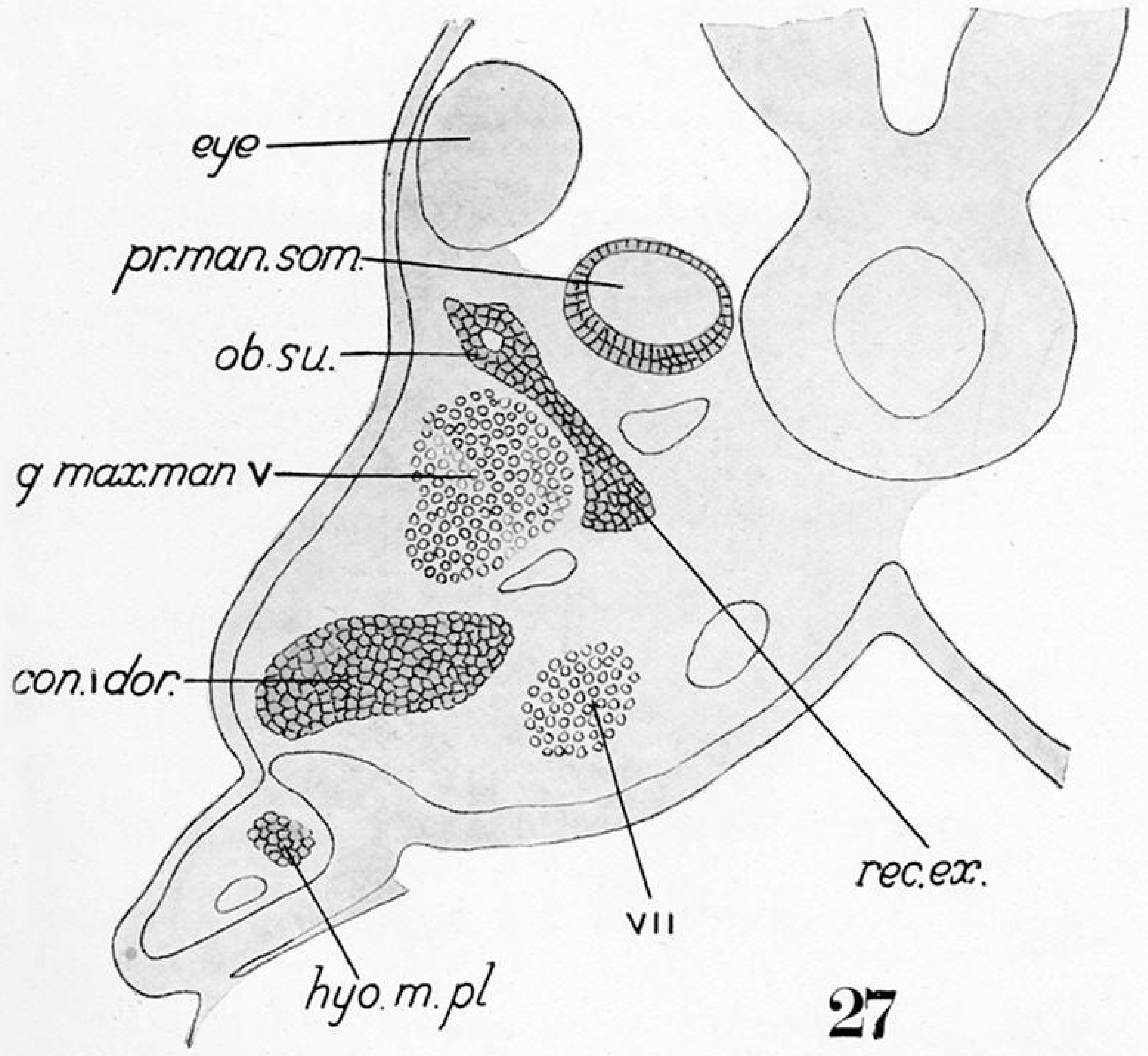

27

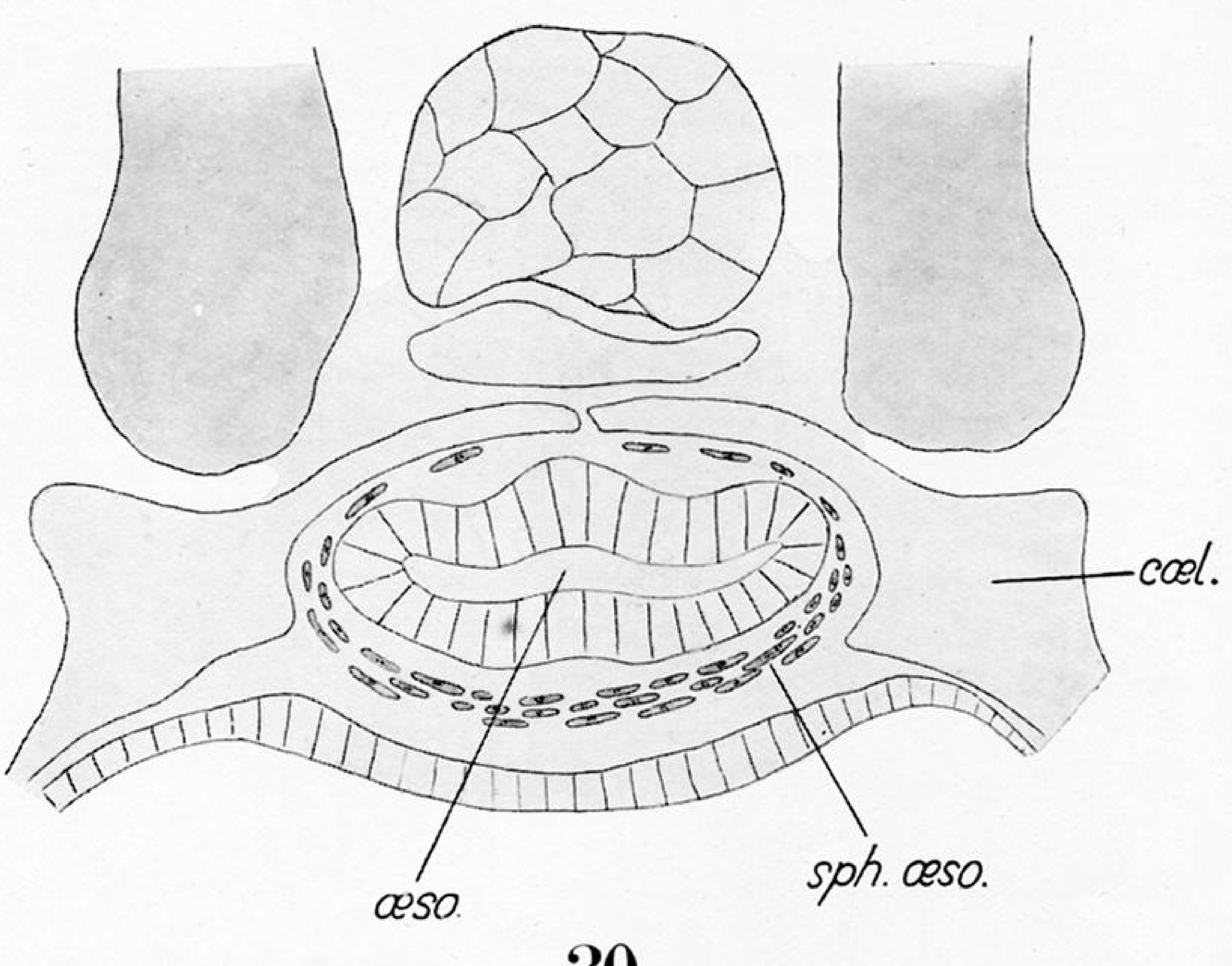

30

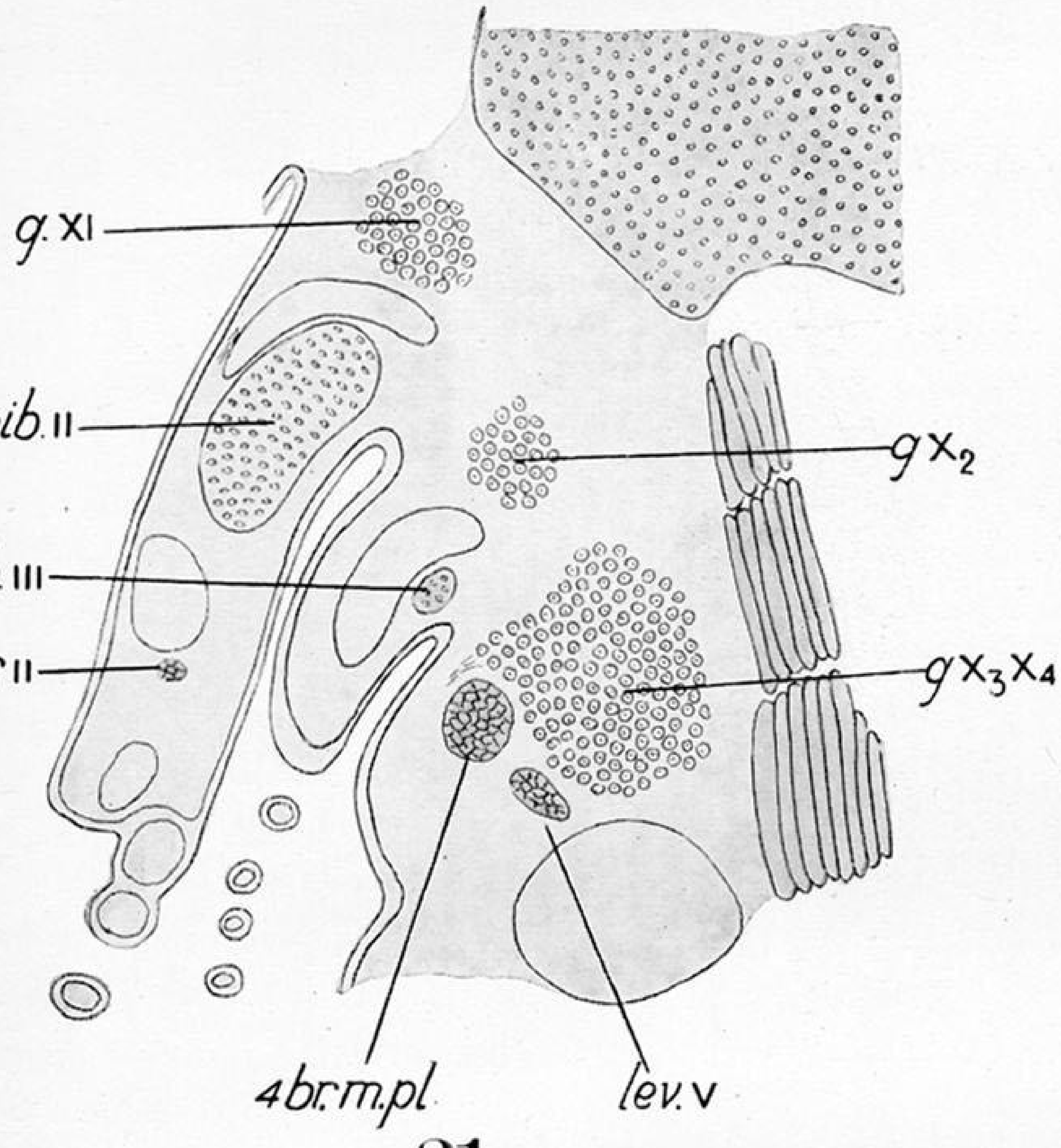

31

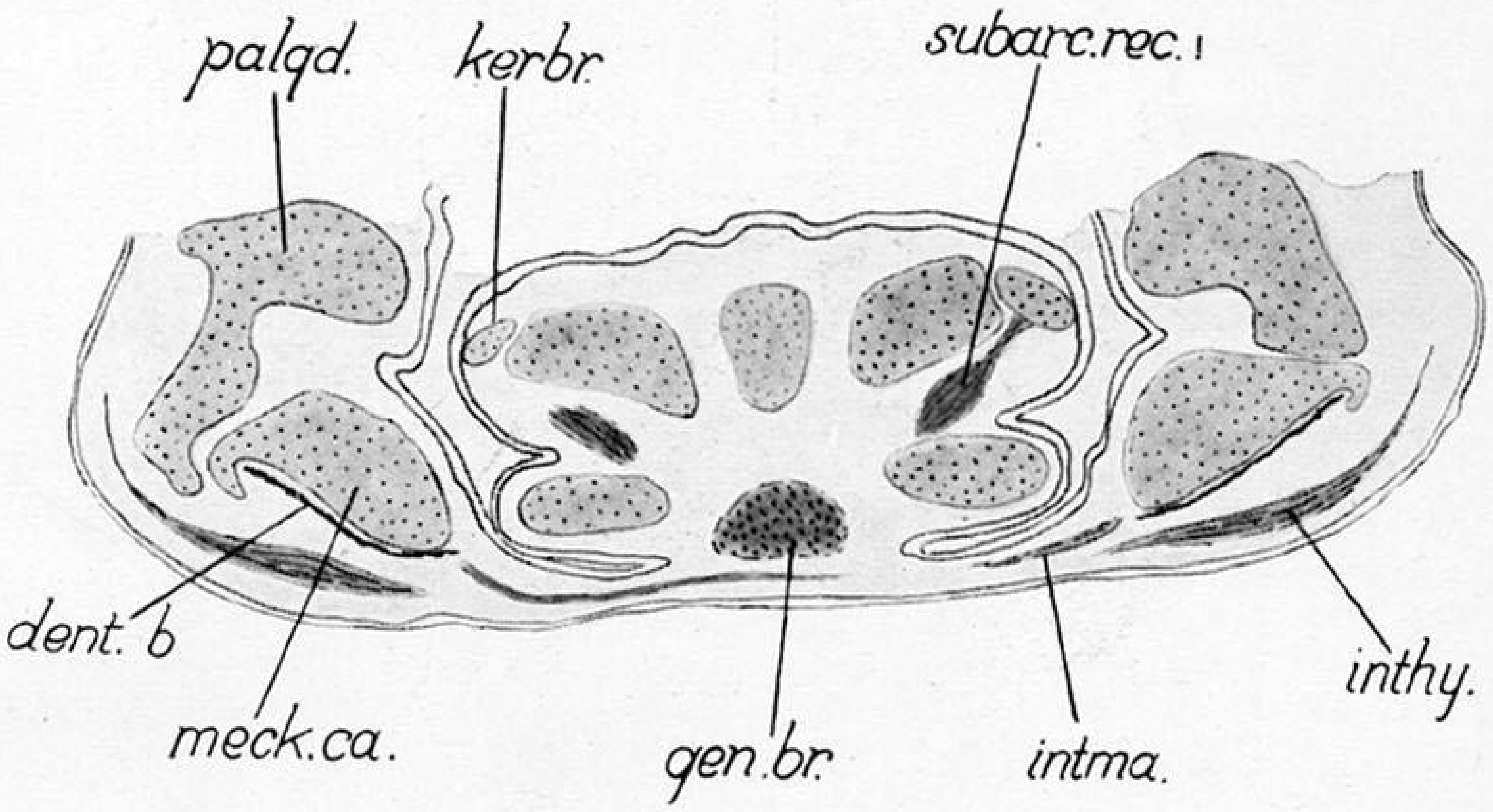

34

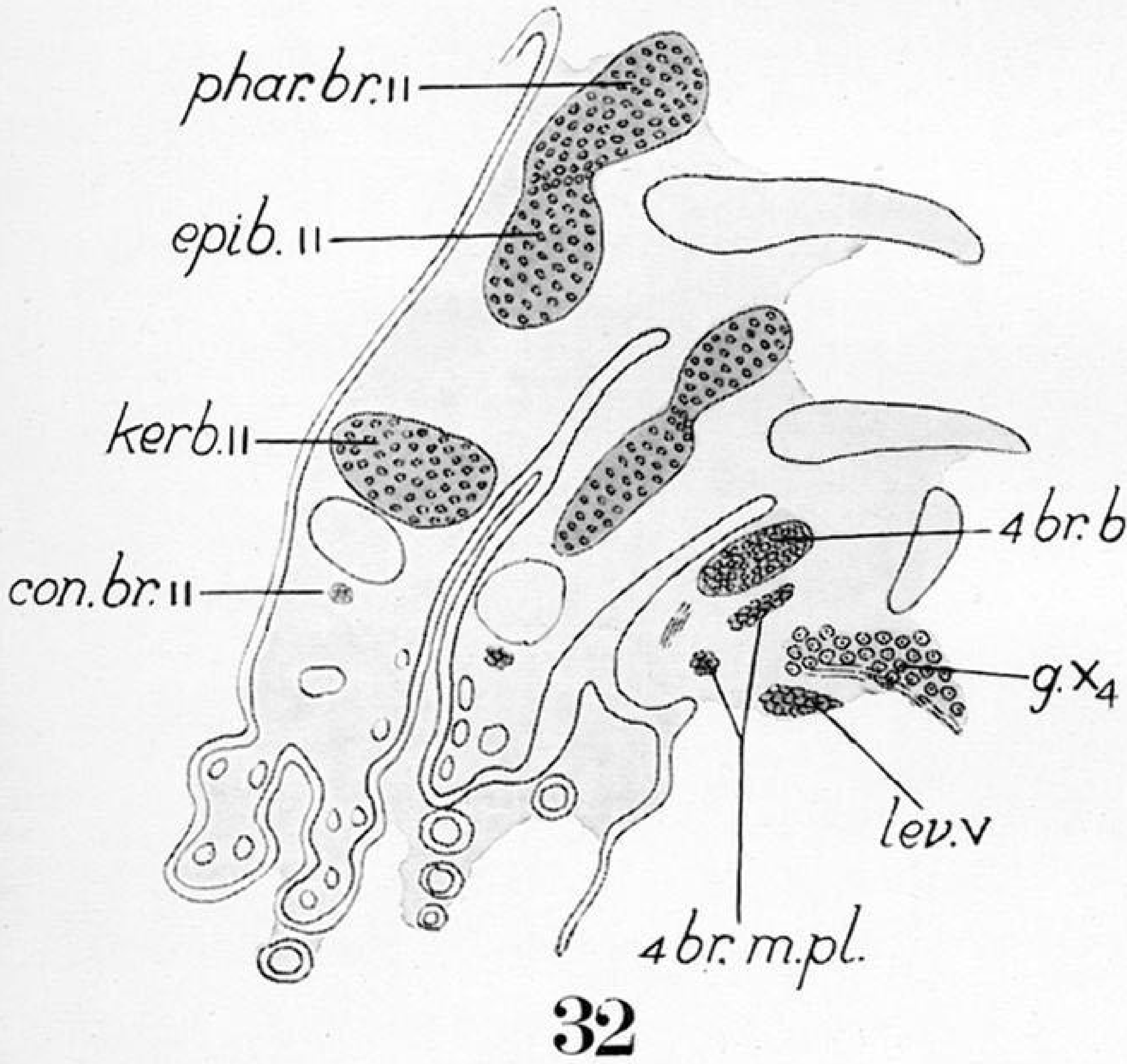

32

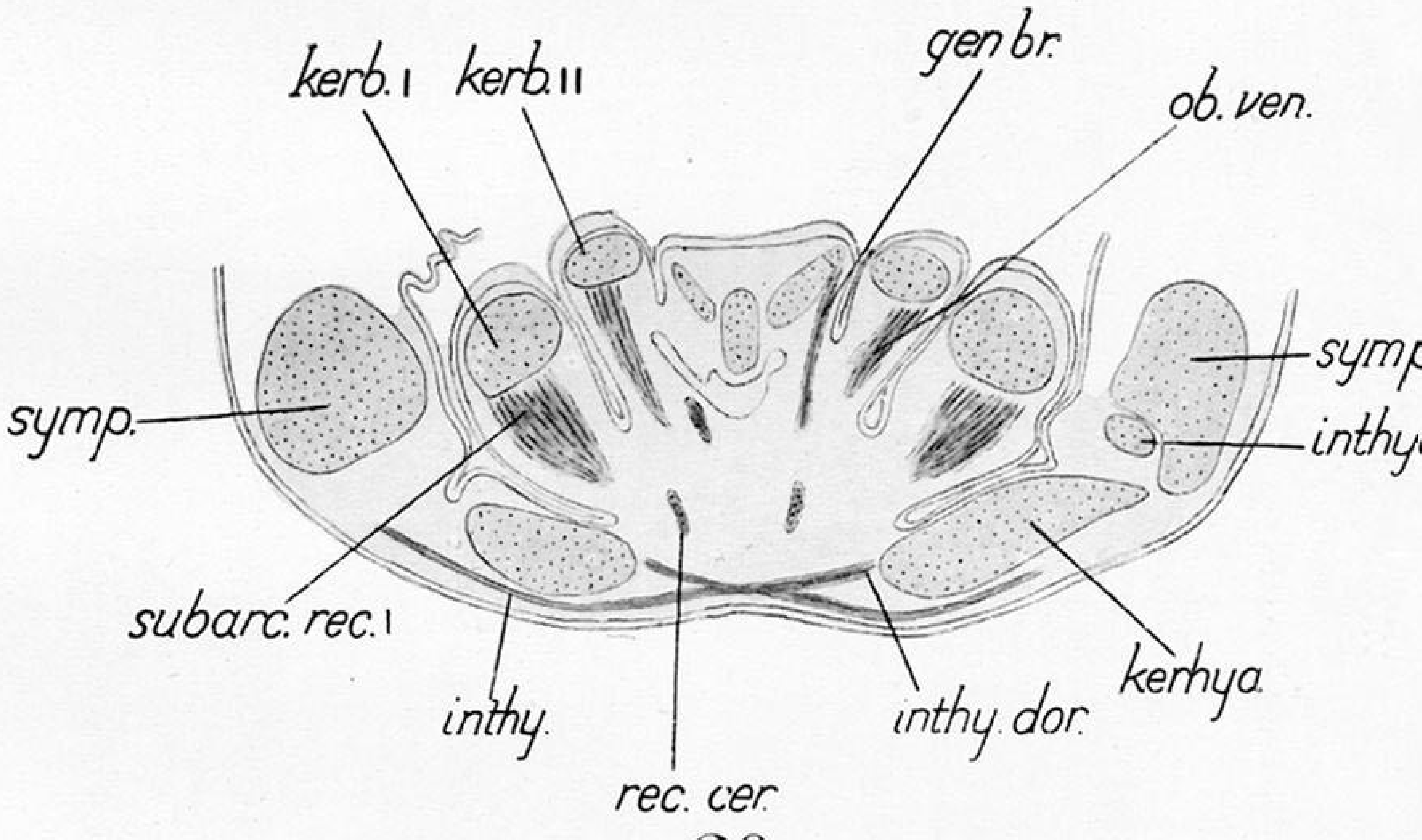

36

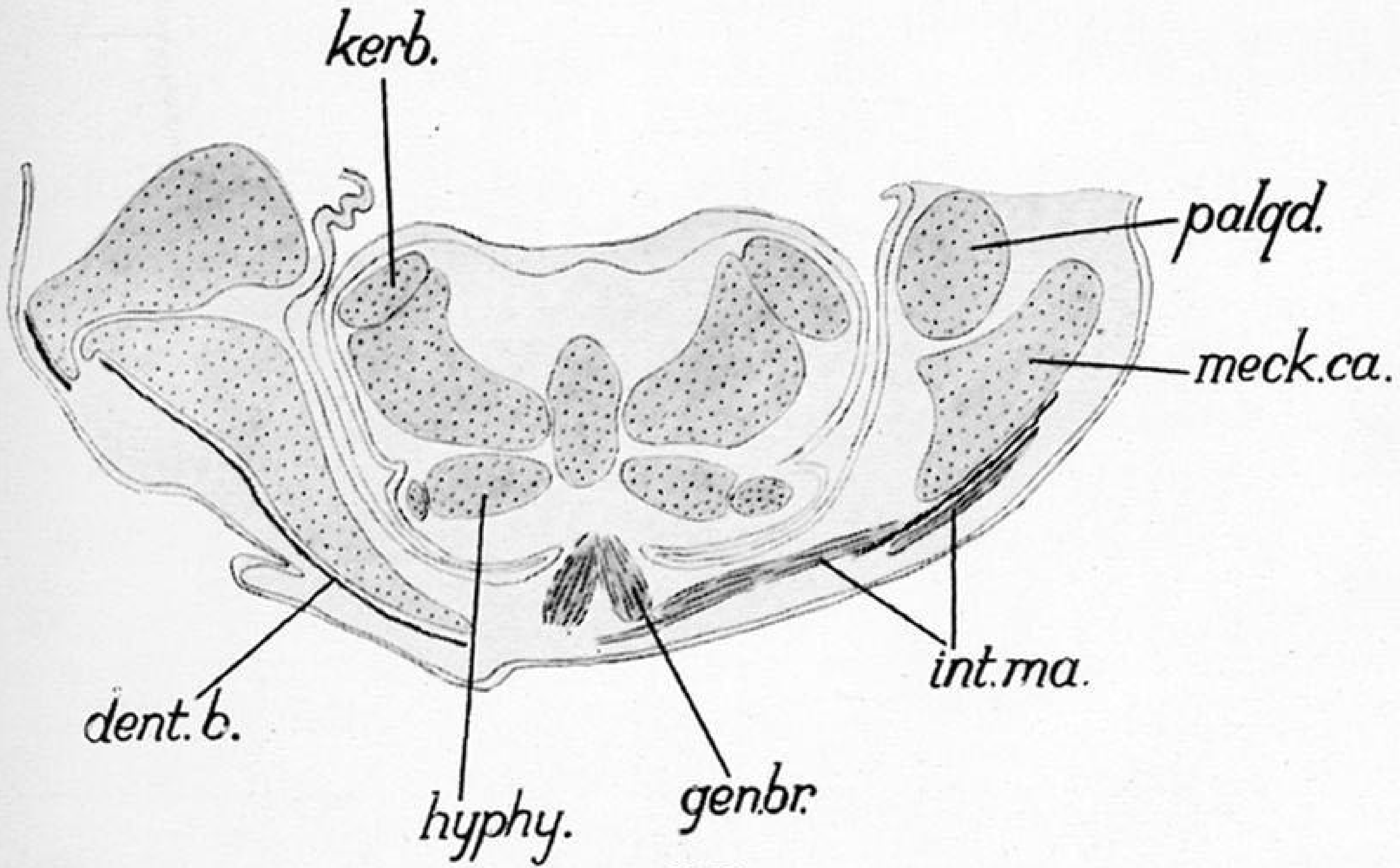

33

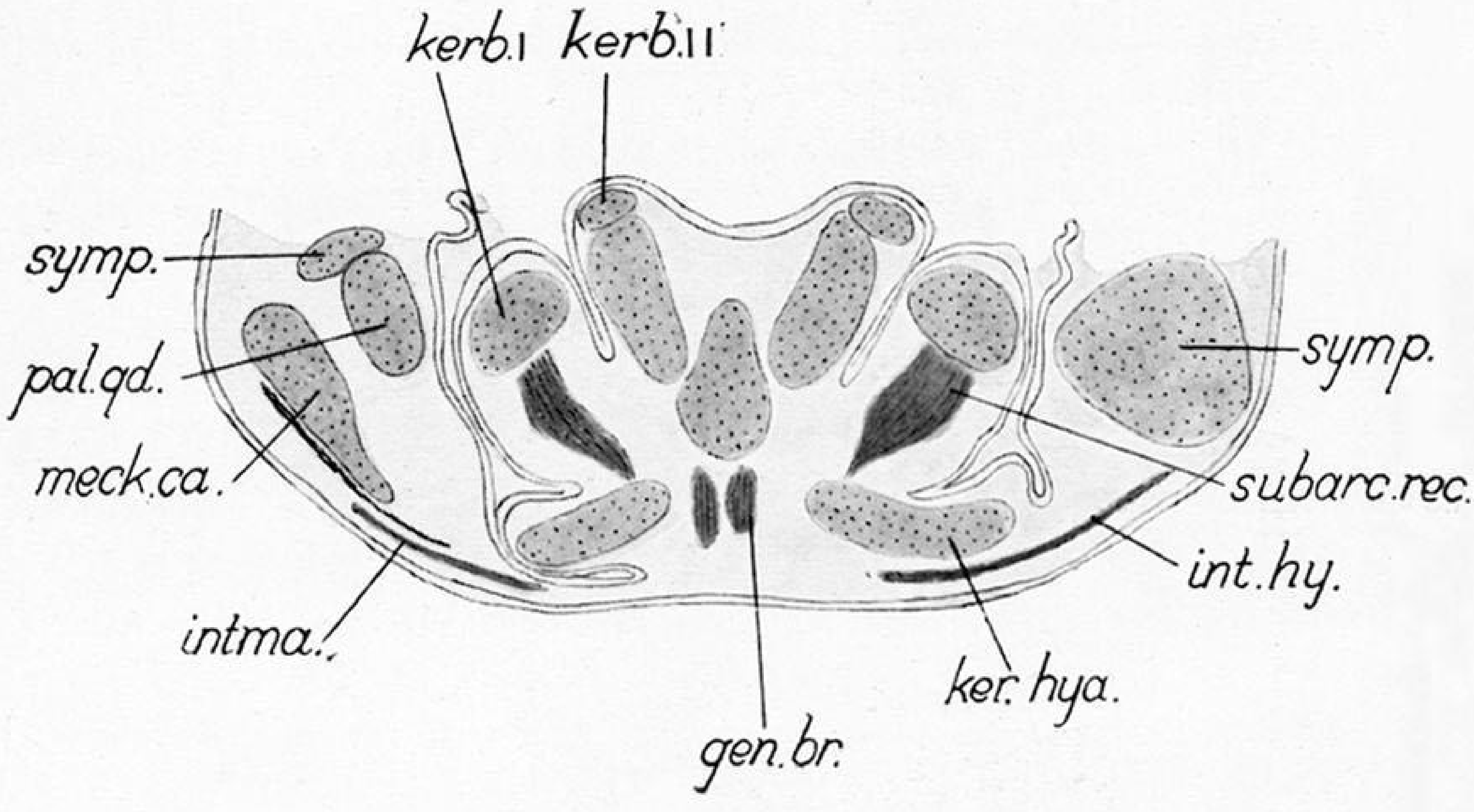

35

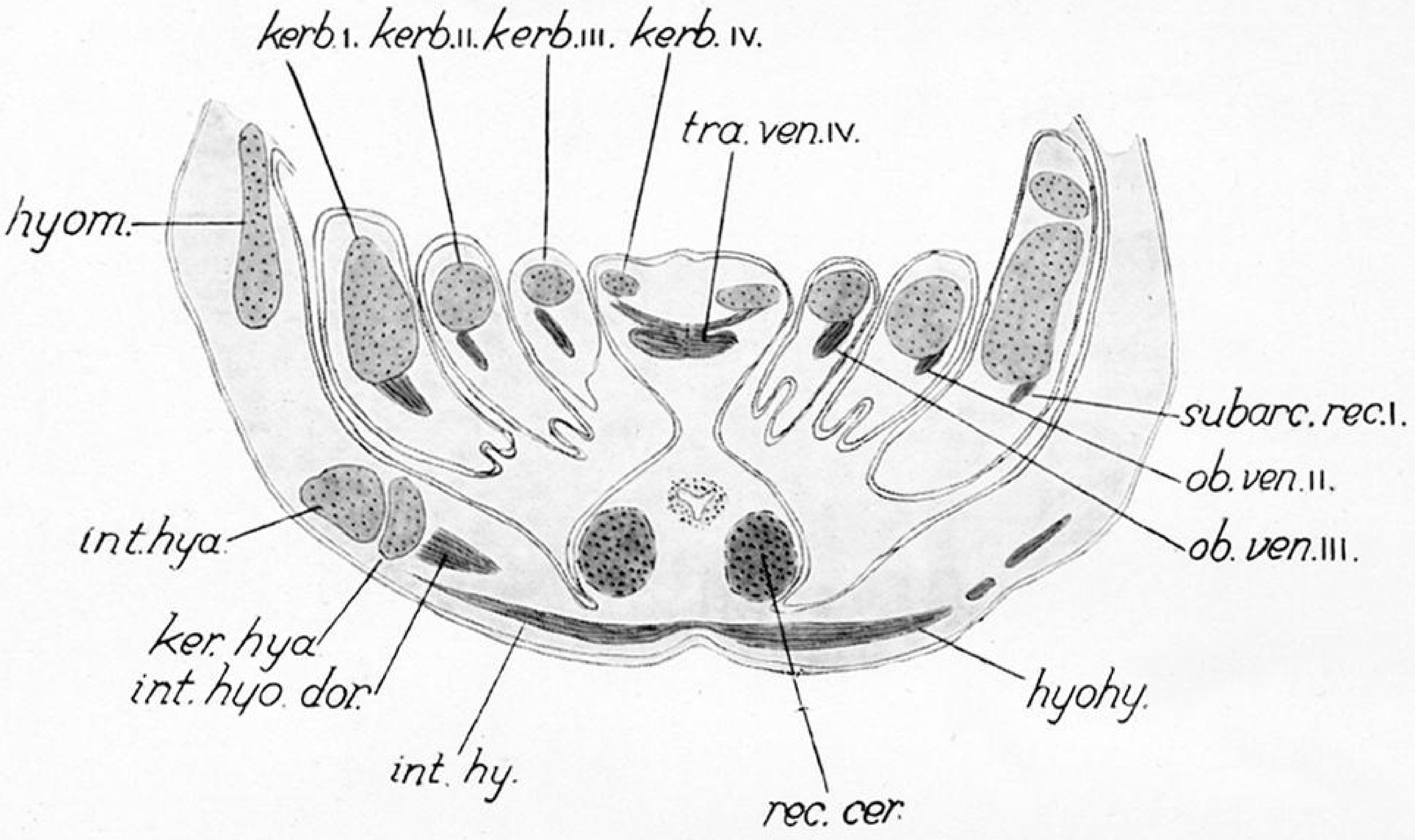
kerb.I.
kerb.II.
kerb.III.
kerb.IV.
tra.ven.IV.
hyom.
subarc.rec.I.
ob.ven.II.
ob.ven.III.
int.hya.
ker.hya.
int.hyo.dor.
hyohy.
int.hy.
rec.cer.

37

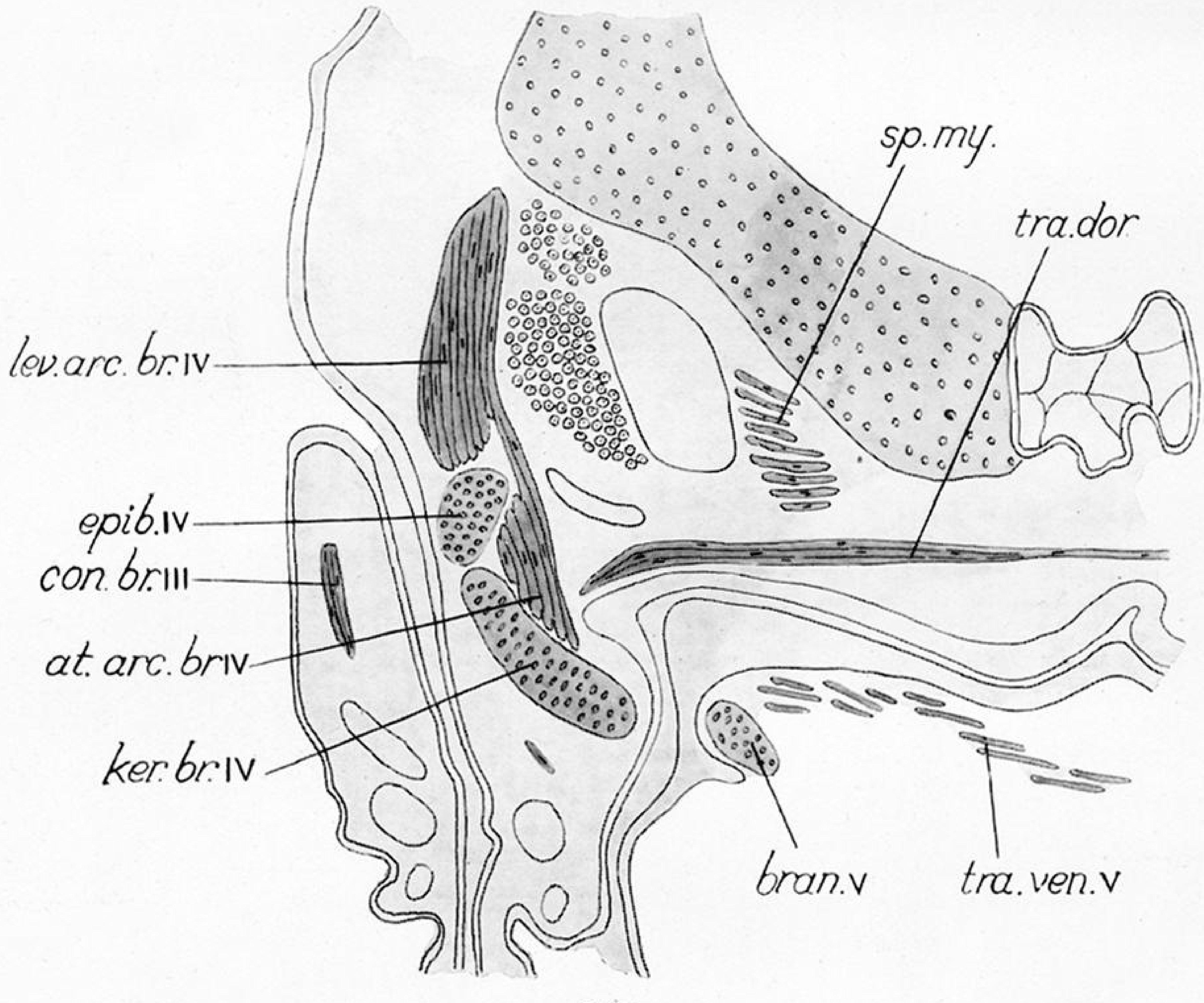
sp.my.
tra.dor.
lev.arc.br.IV
epib.IV
con.br.III
at.arc.br.IV
ker.br.IV
bran.V
tra.ven.V

38

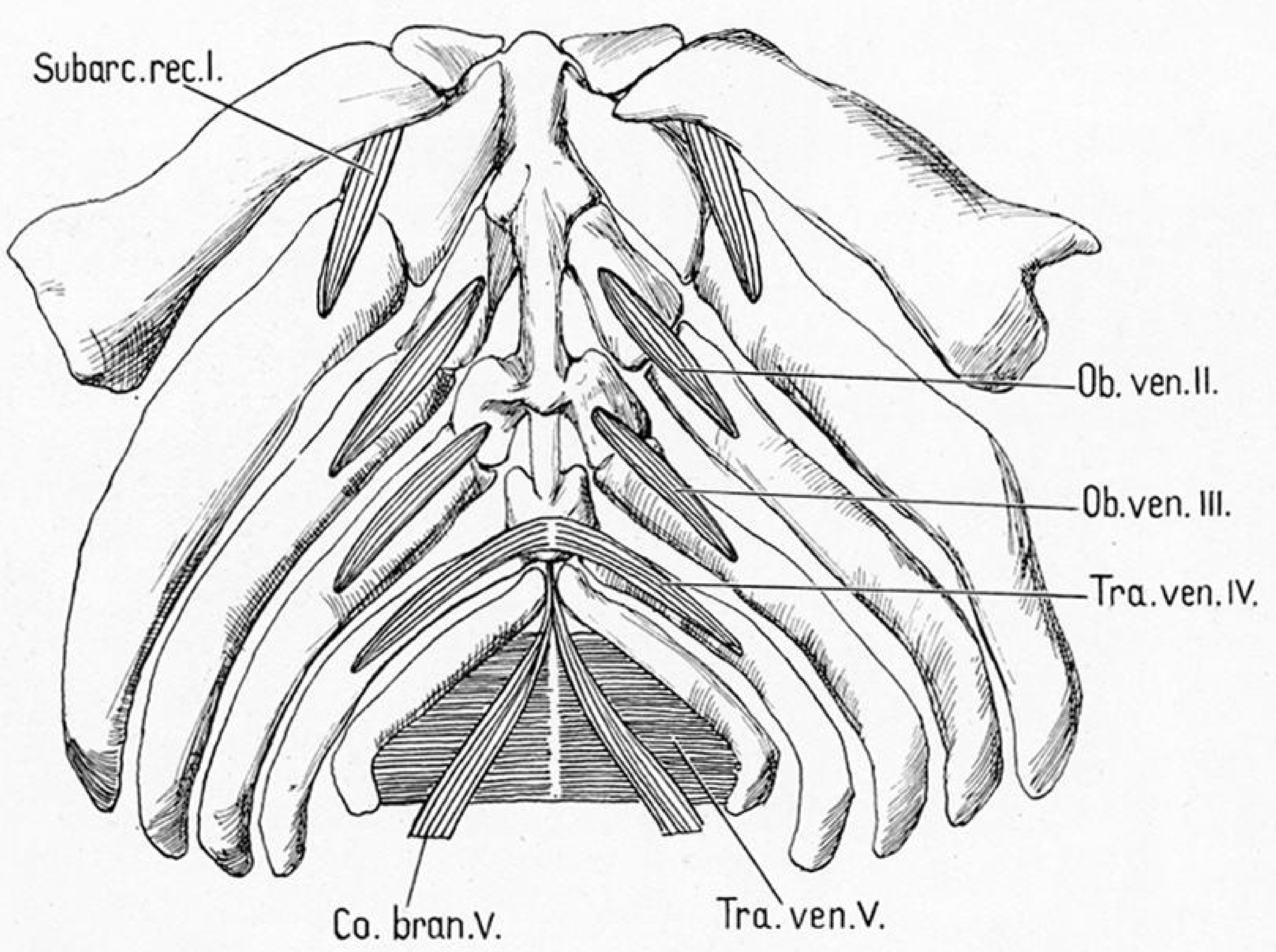
Subarc.rec.I.
Ob.ven.II.
Ob.ven.III.
Tra.ven.IV.
Co.bran.V.
Tra.ven.V.

39

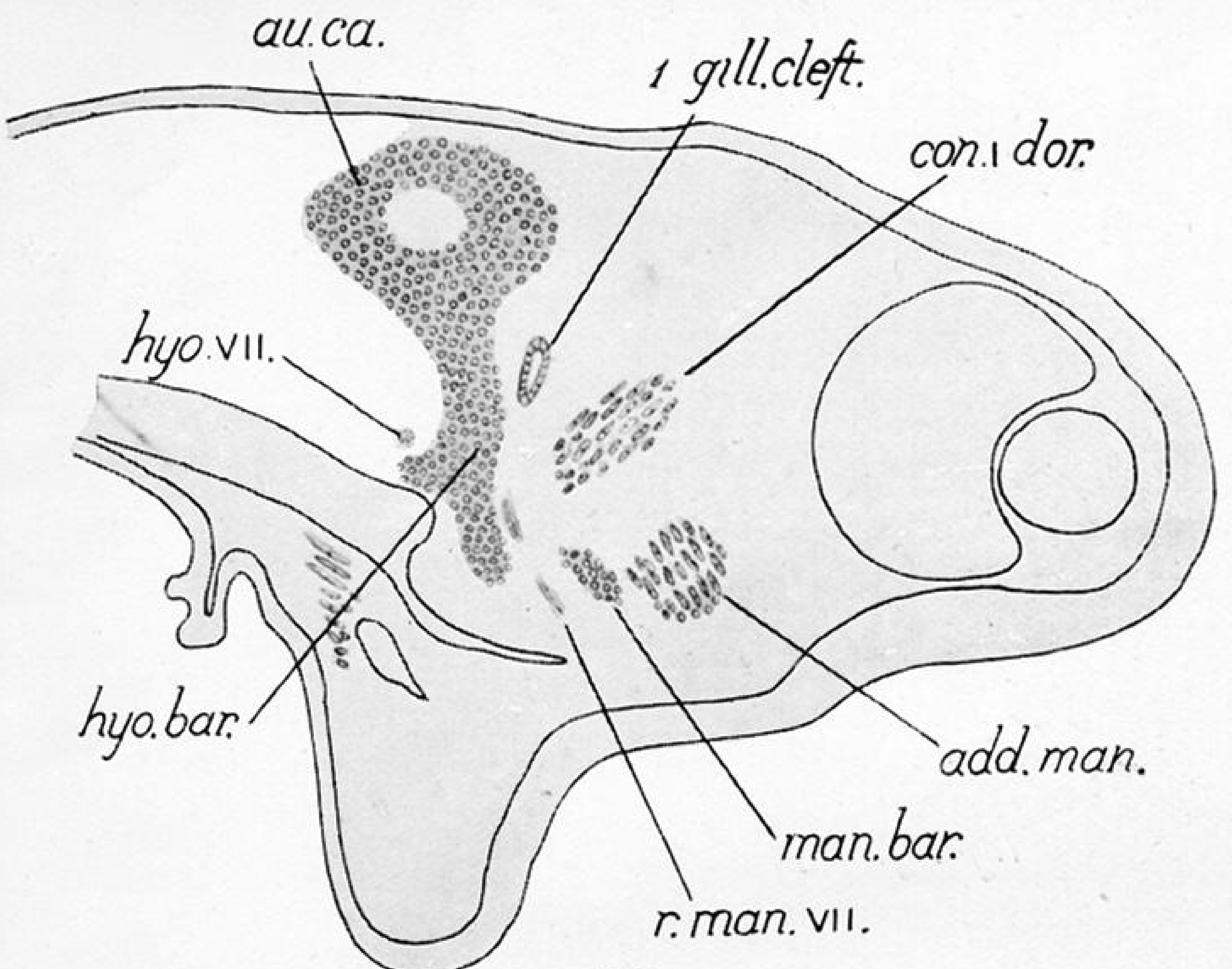

40

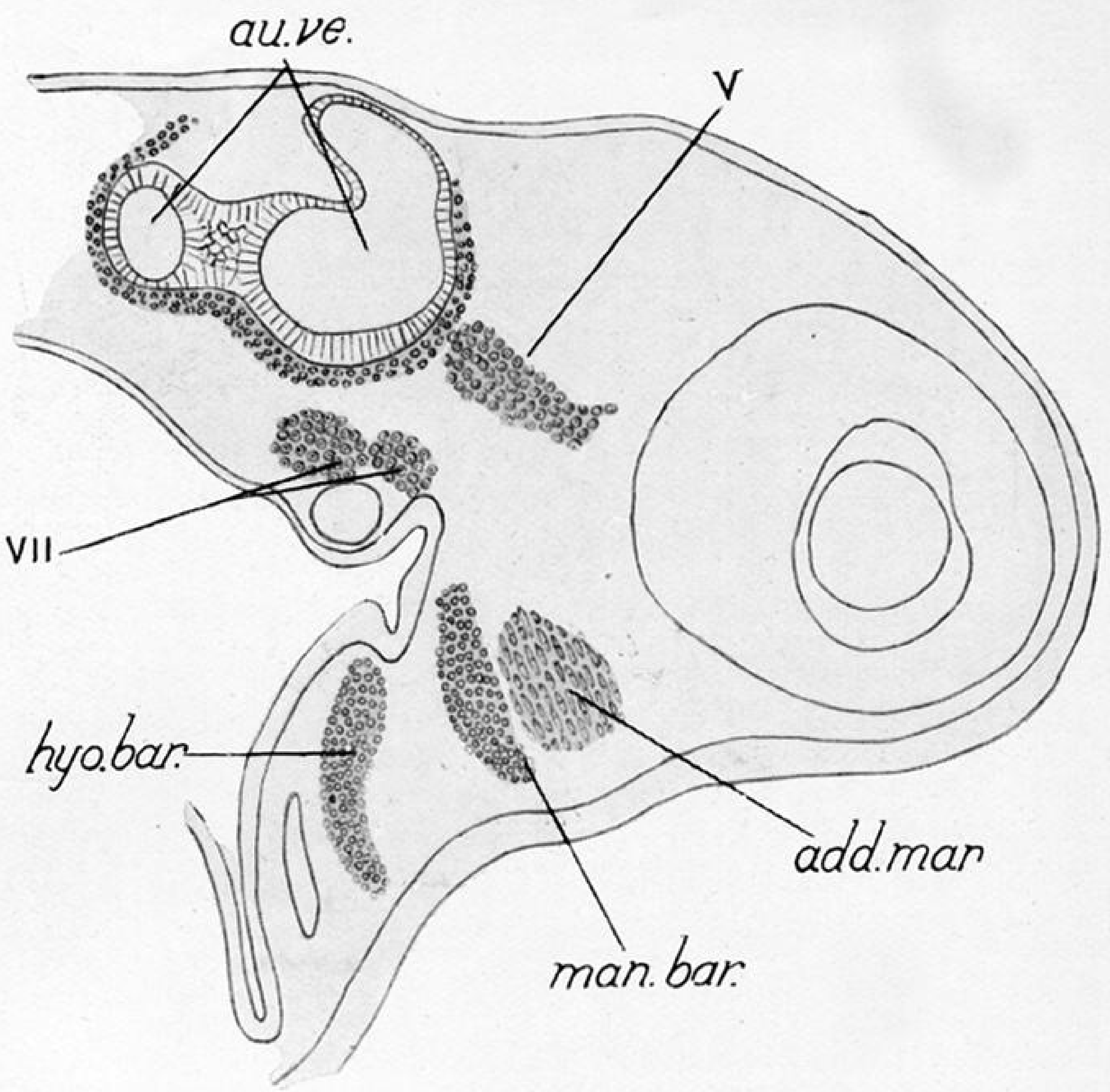

41

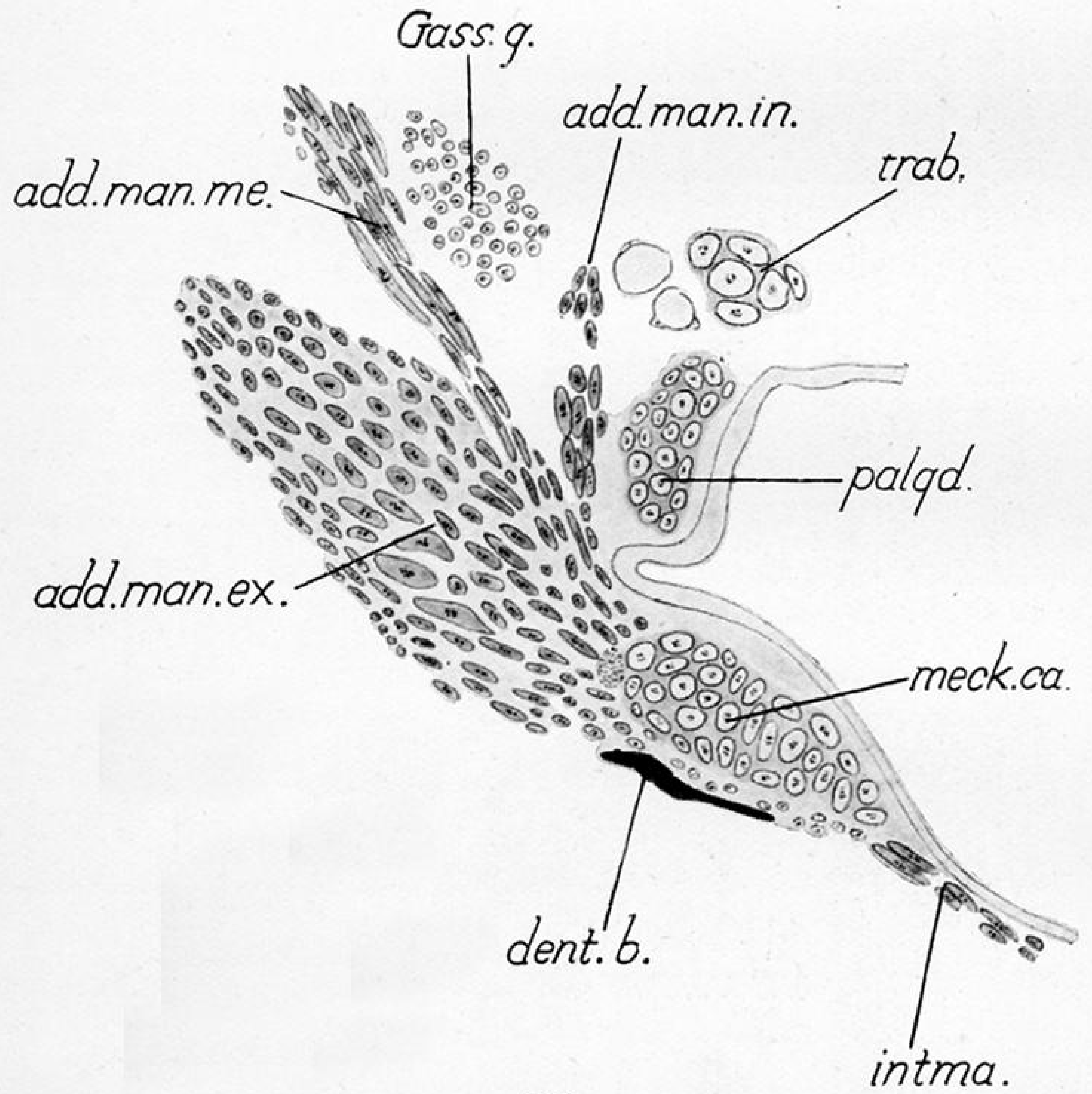

42

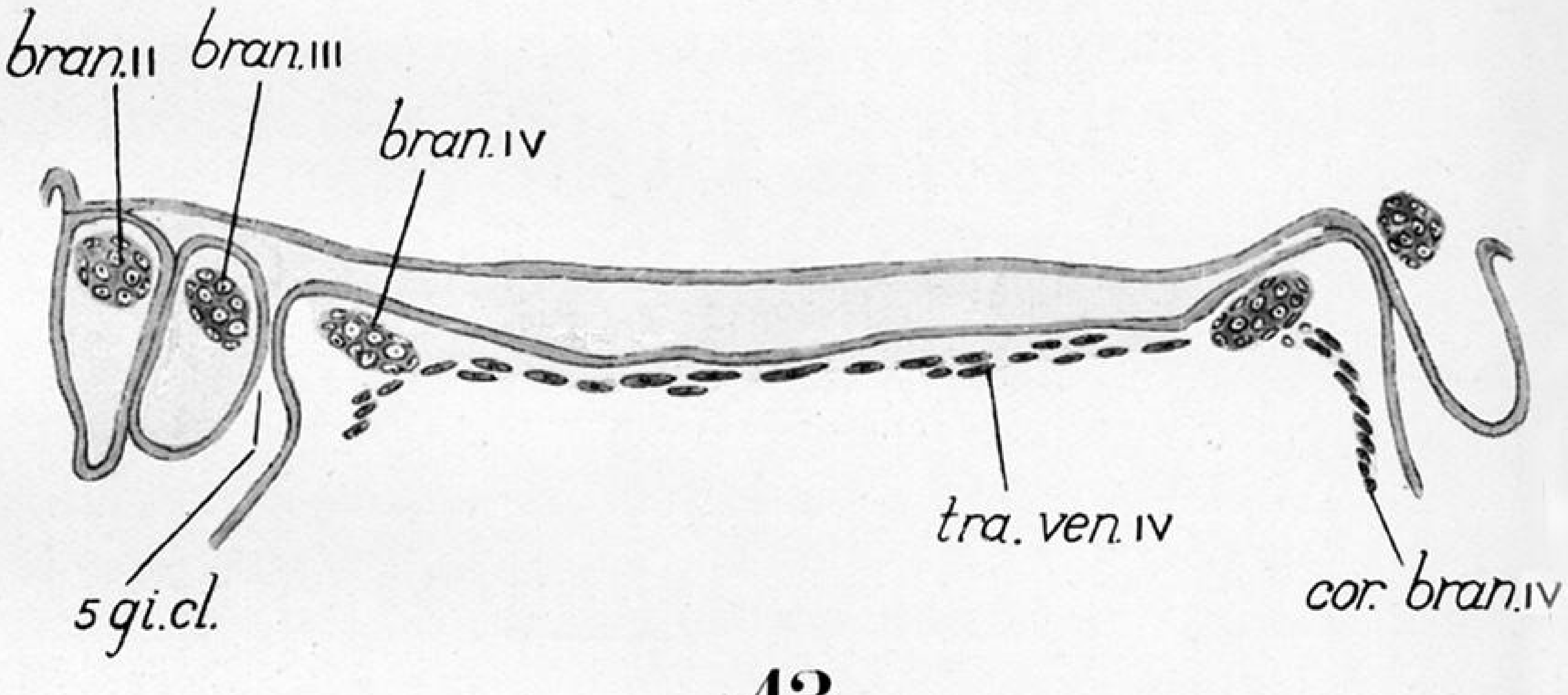

43

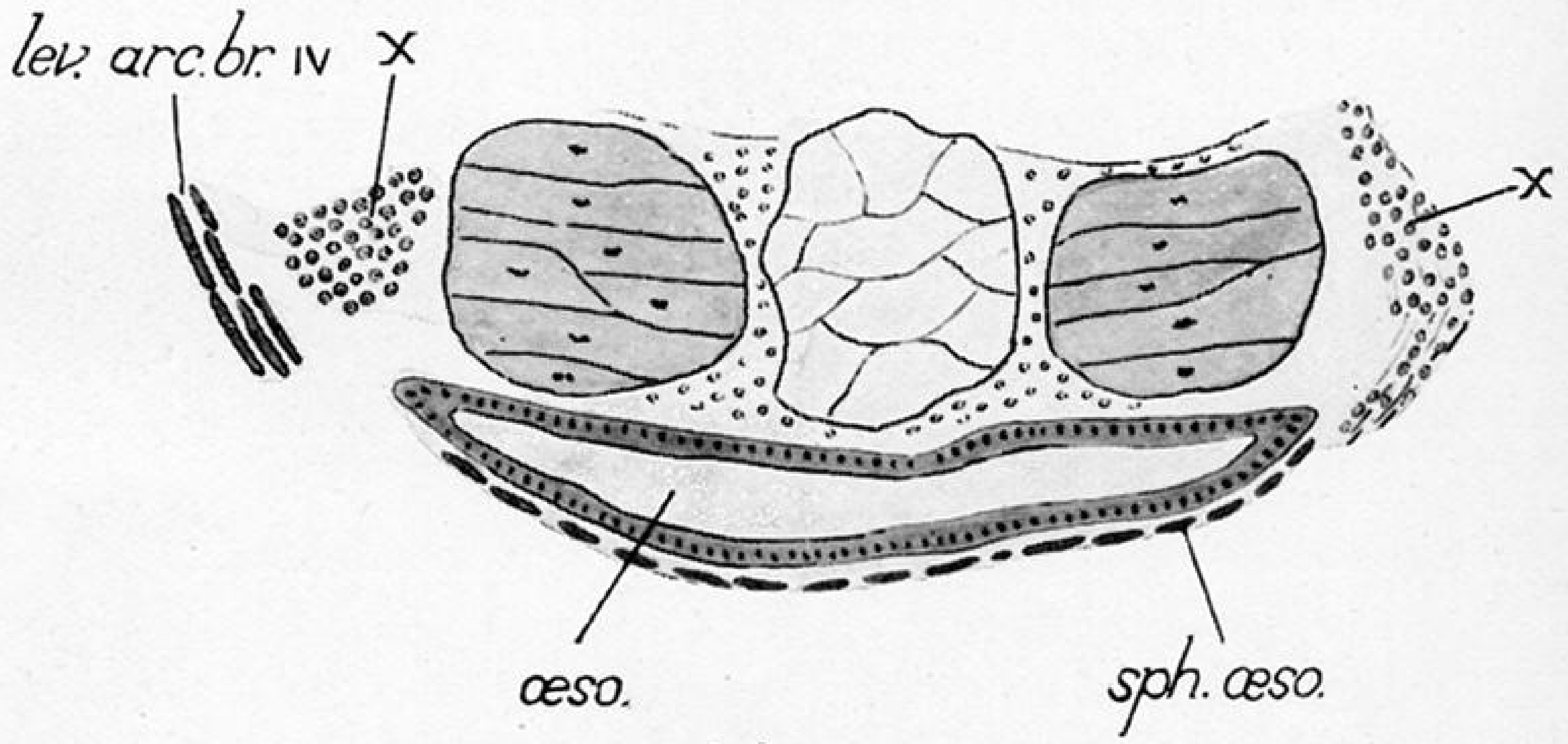

44

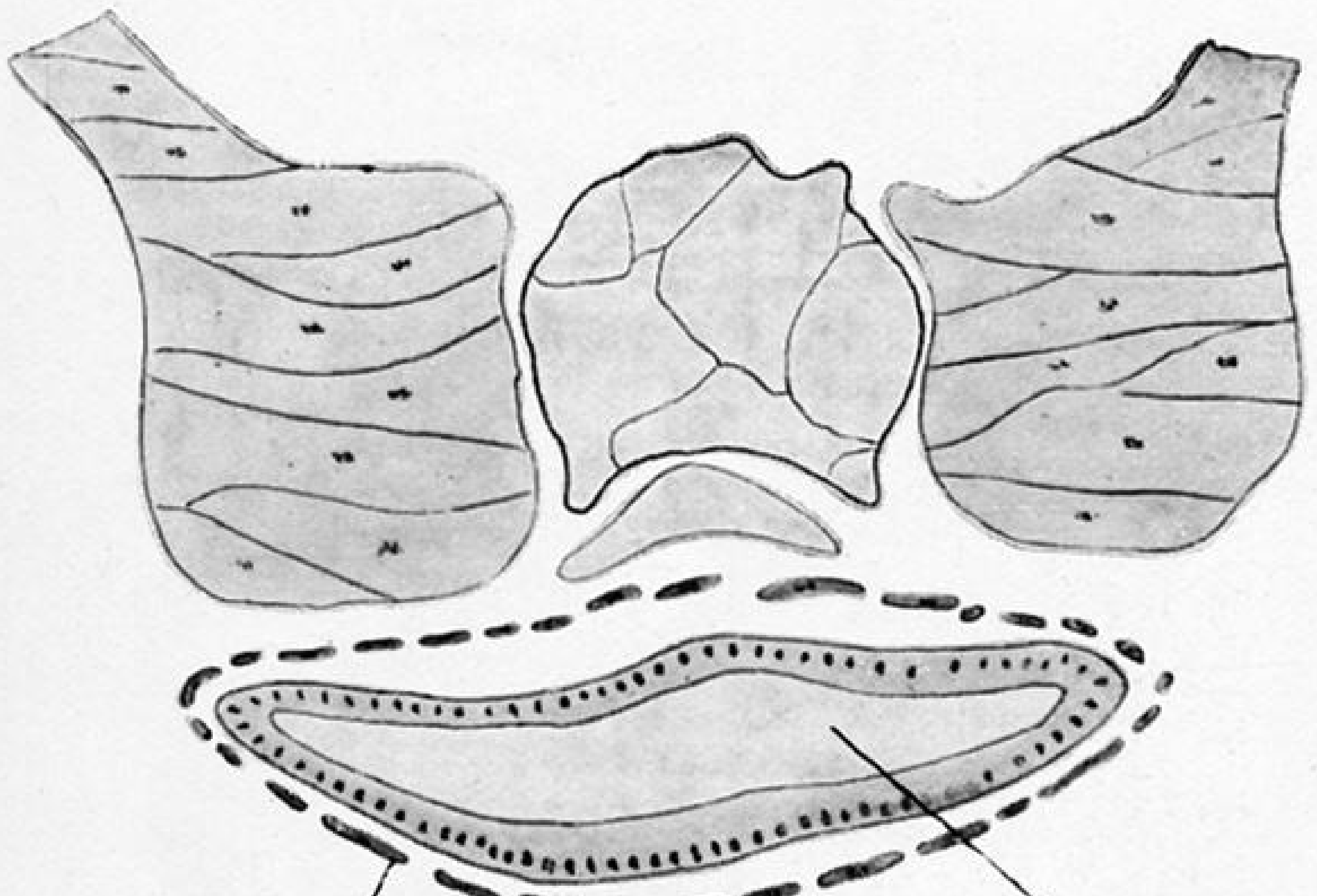

45

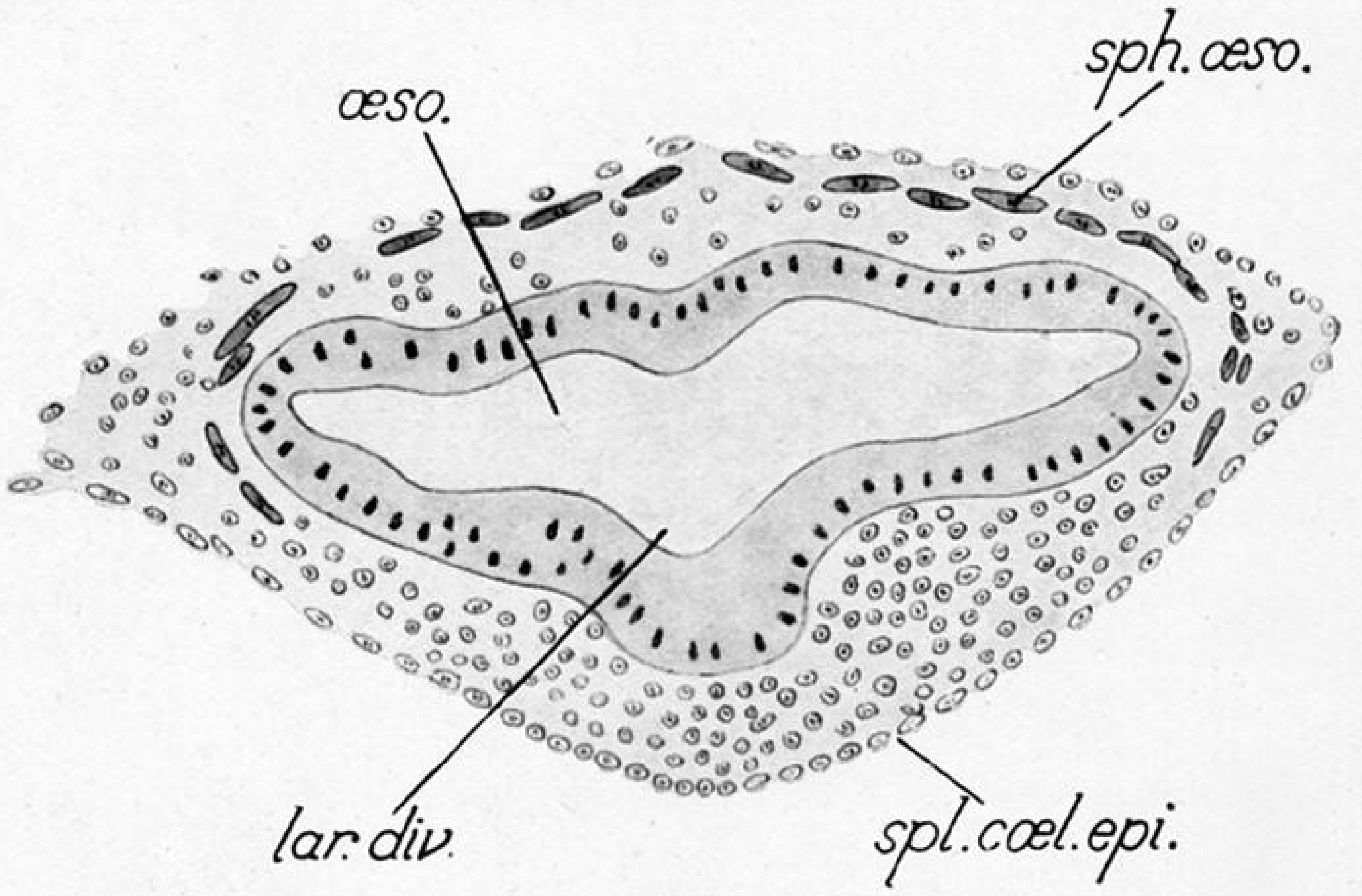

46

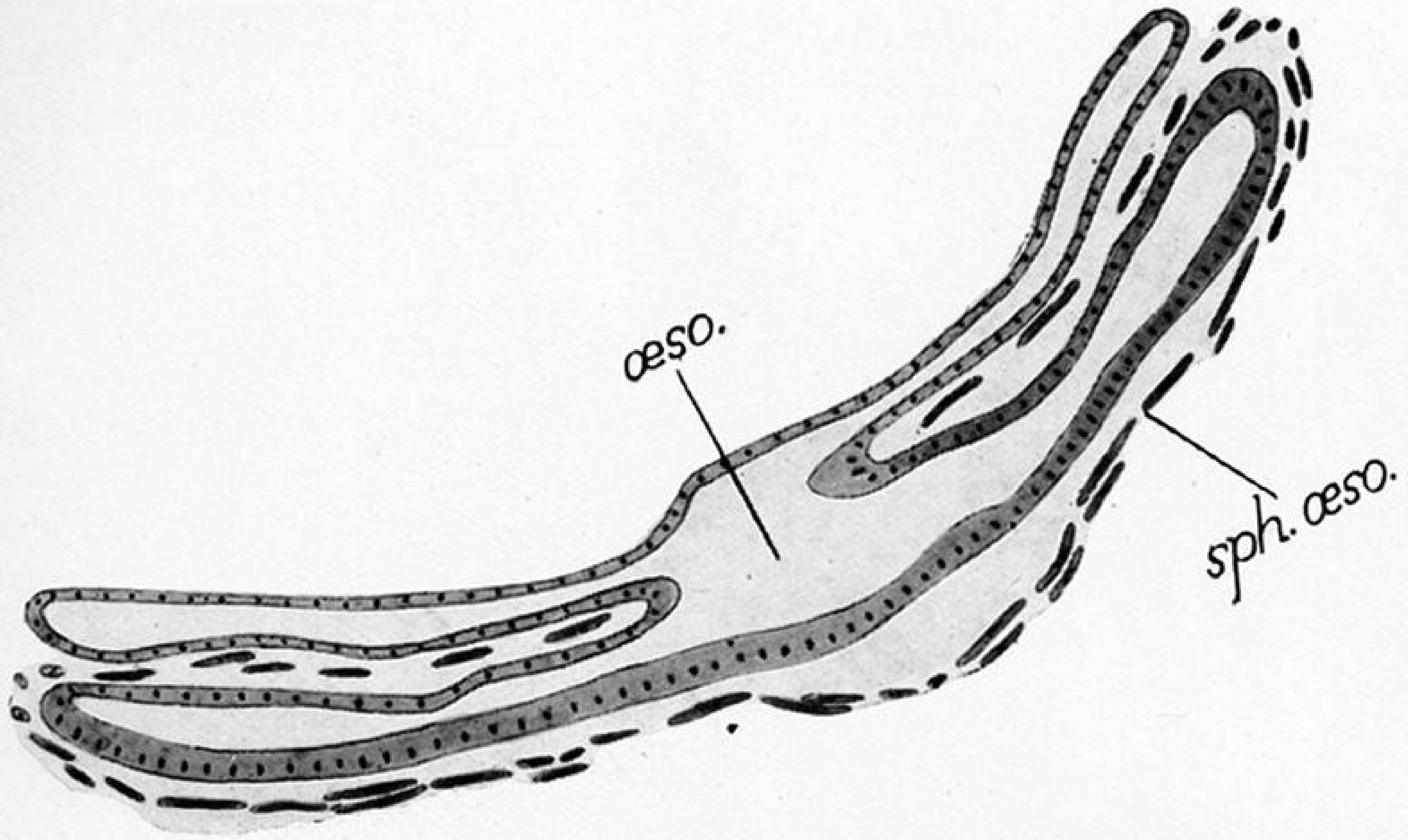

47

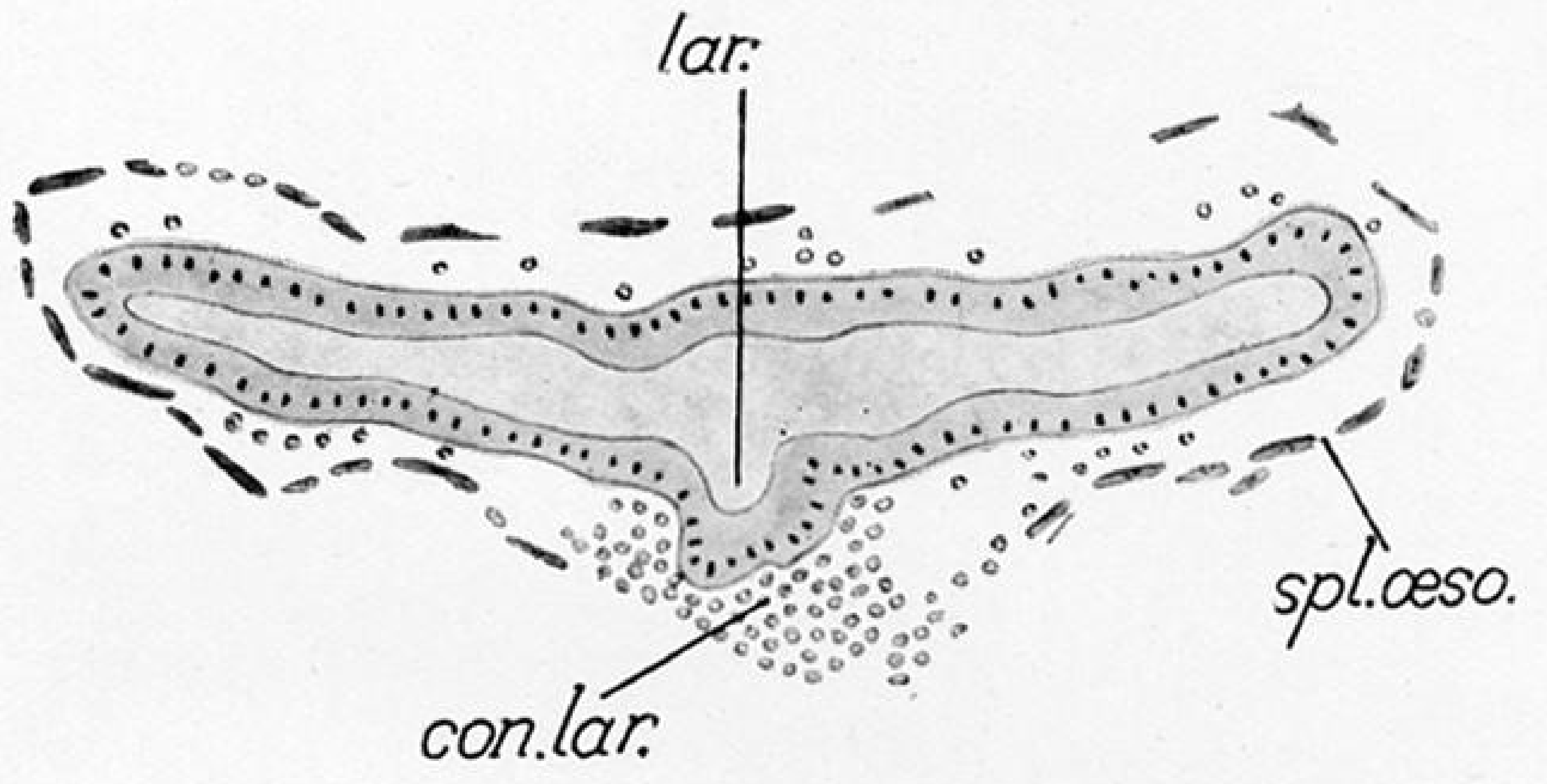

48

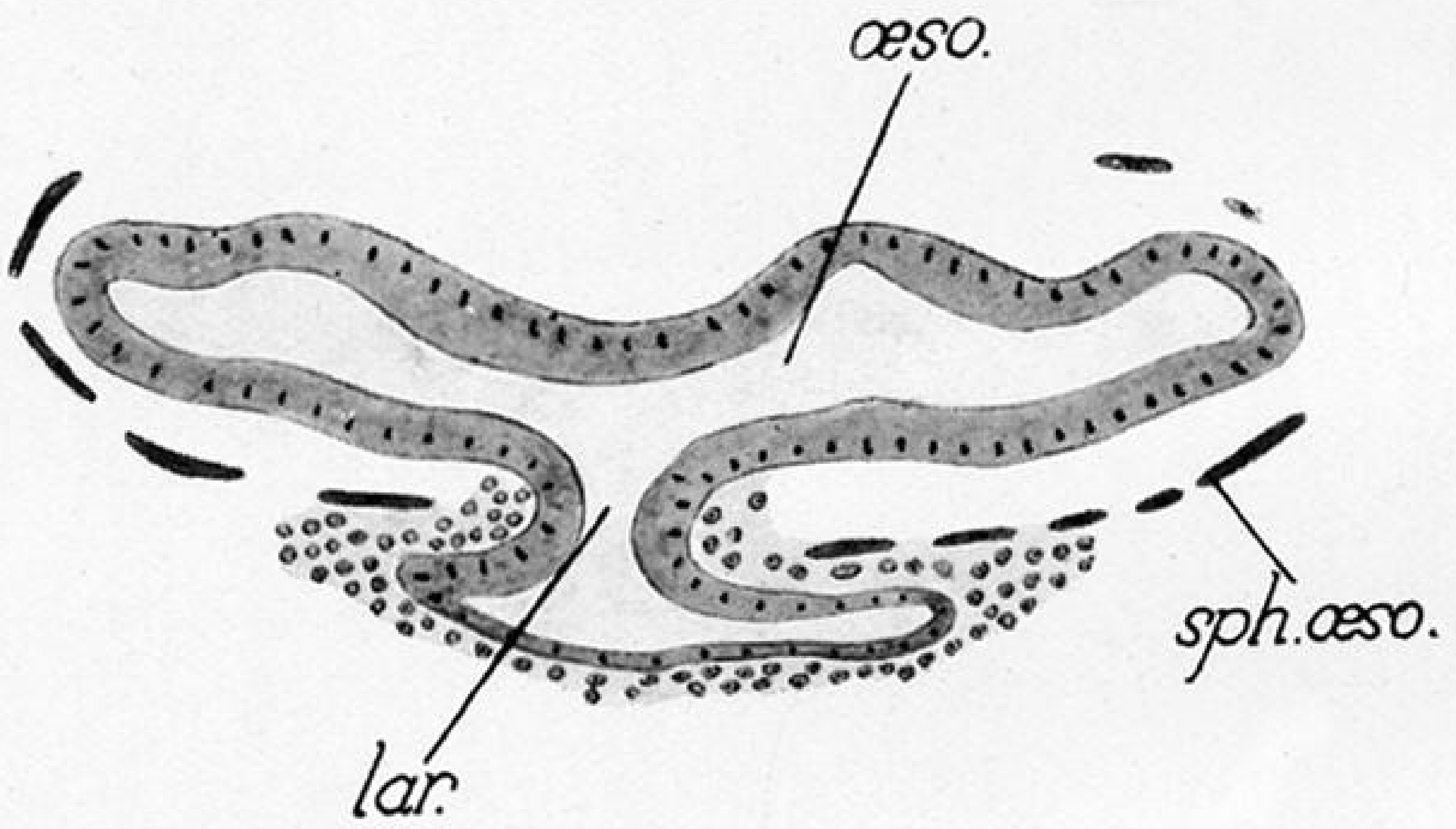

49

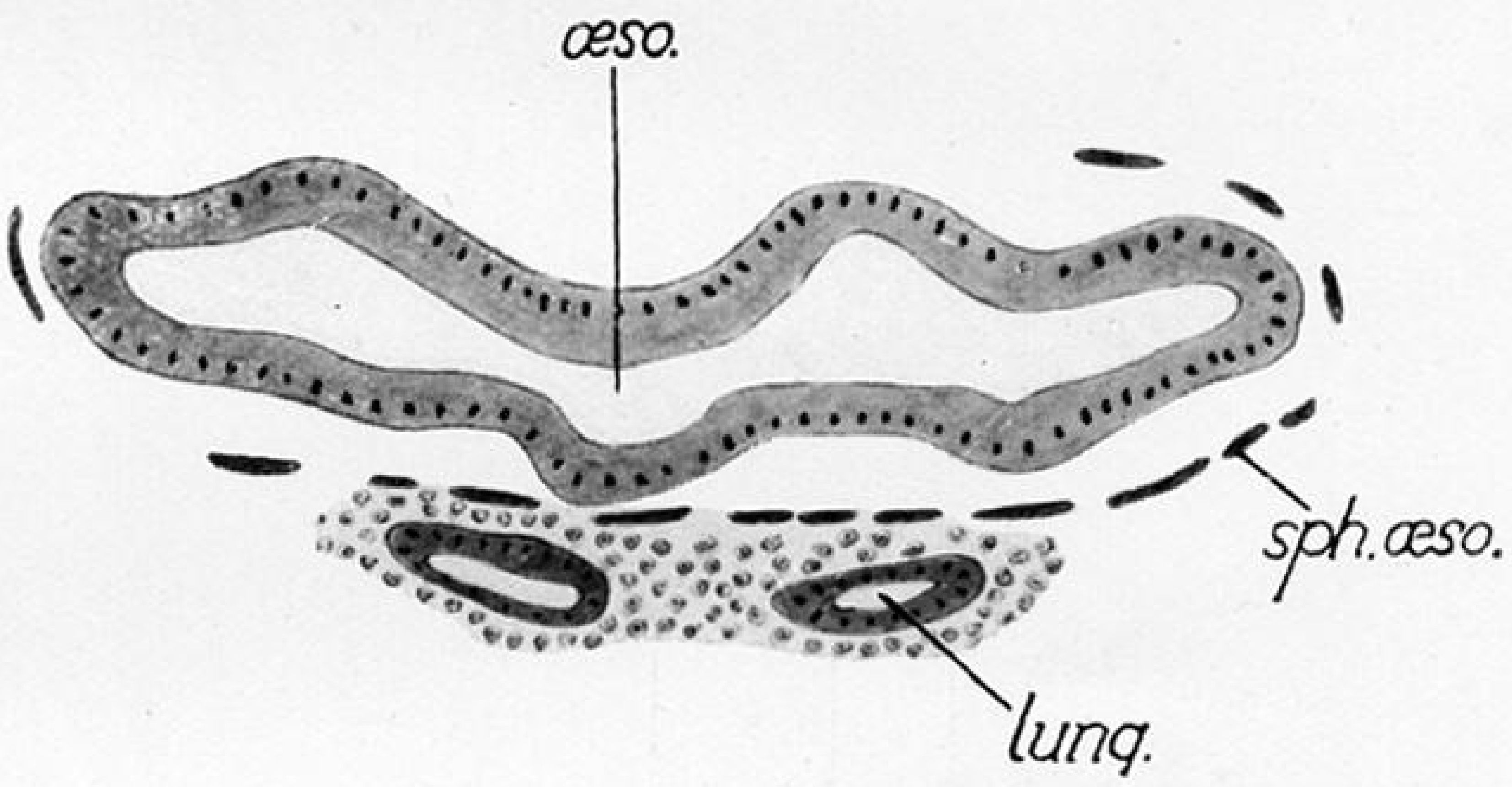

50

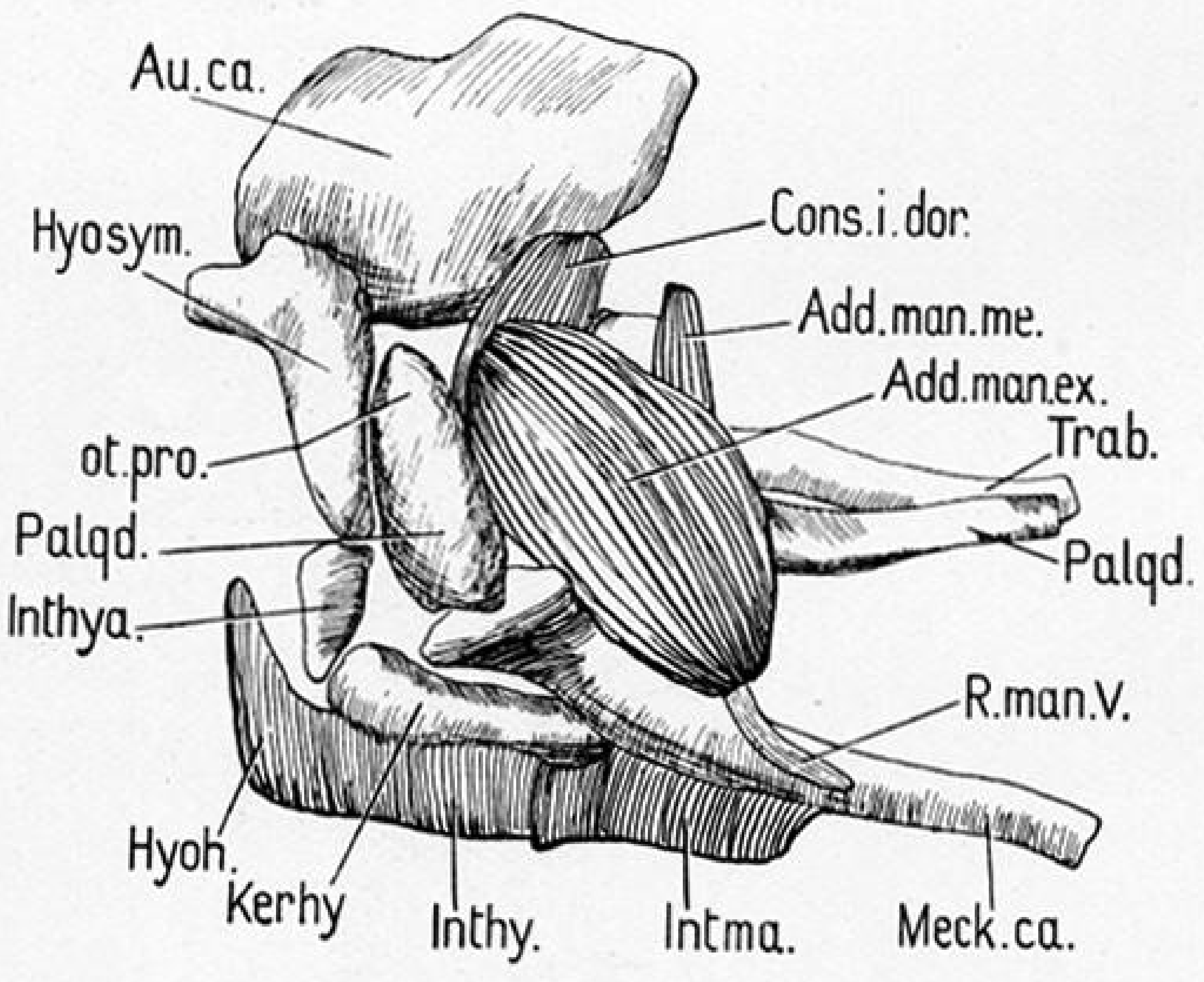

51

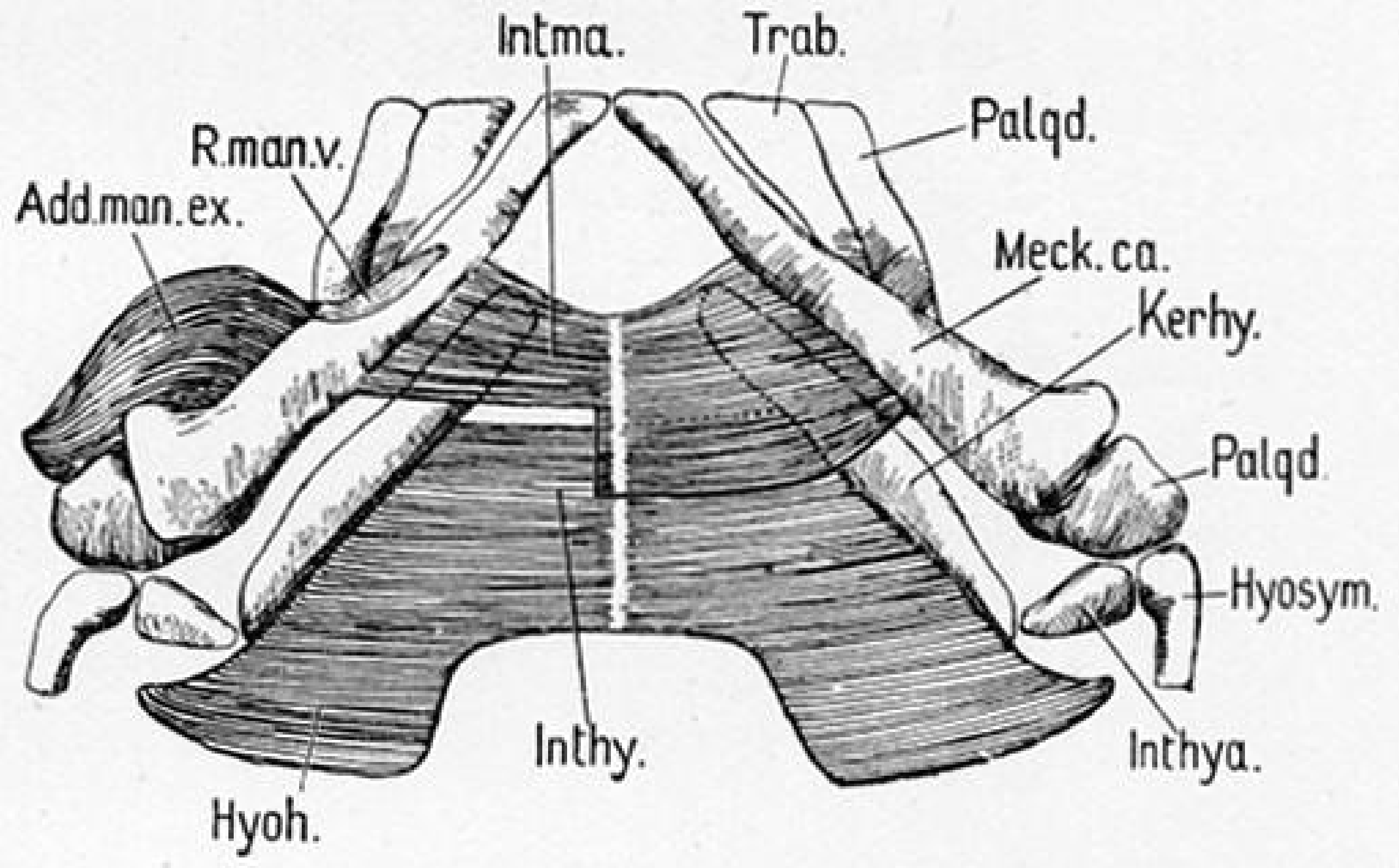

52

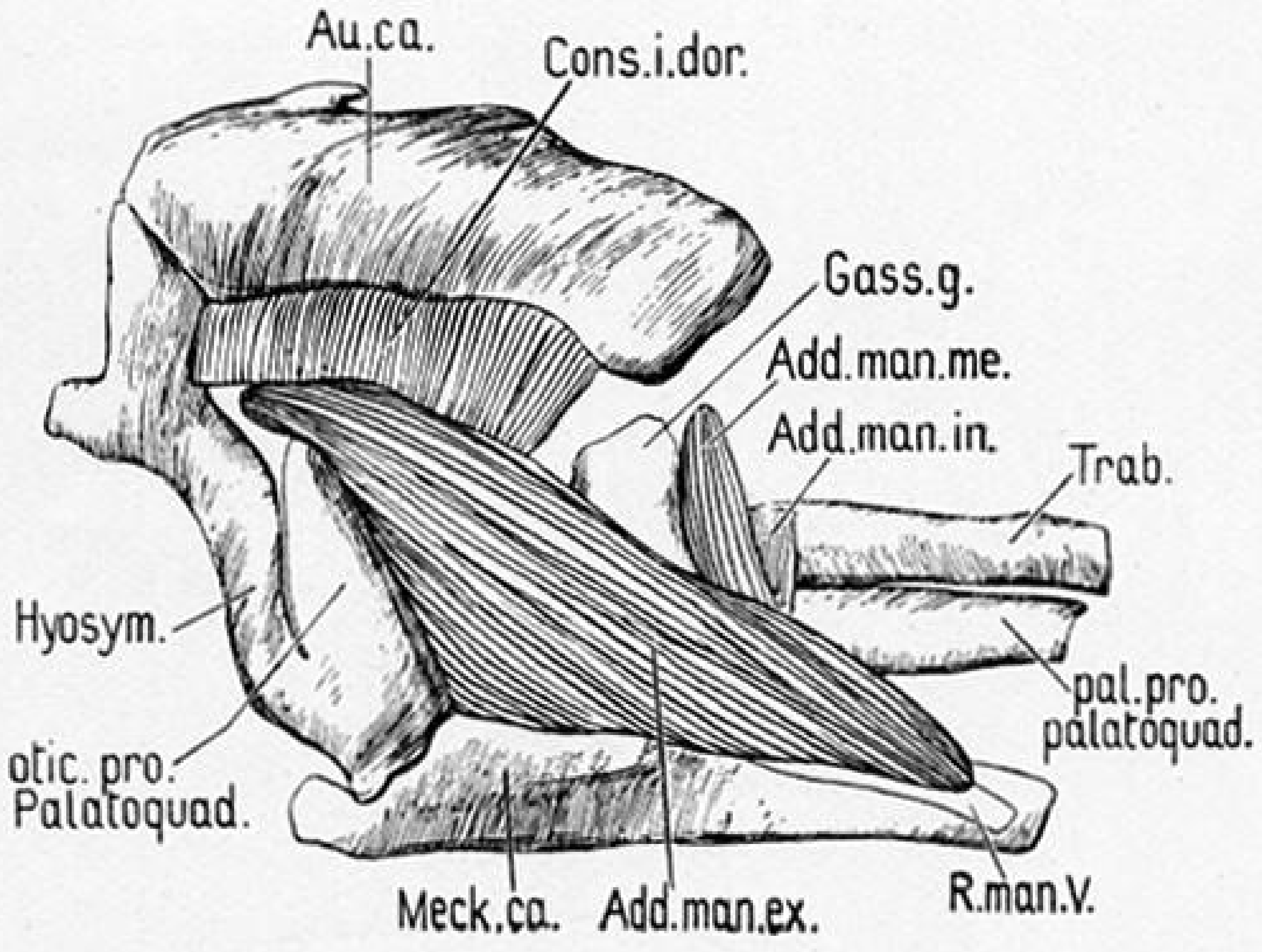

53

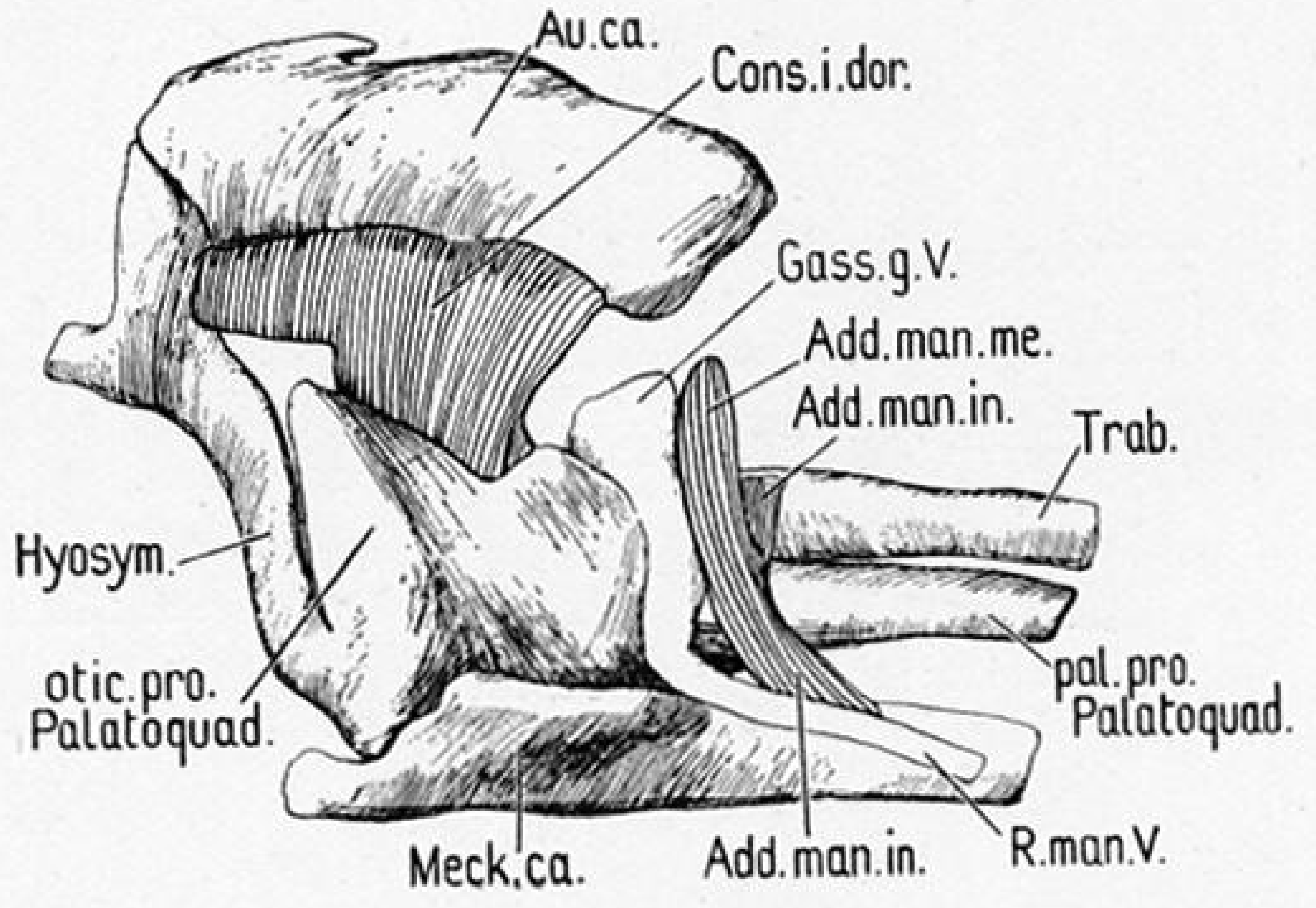

54

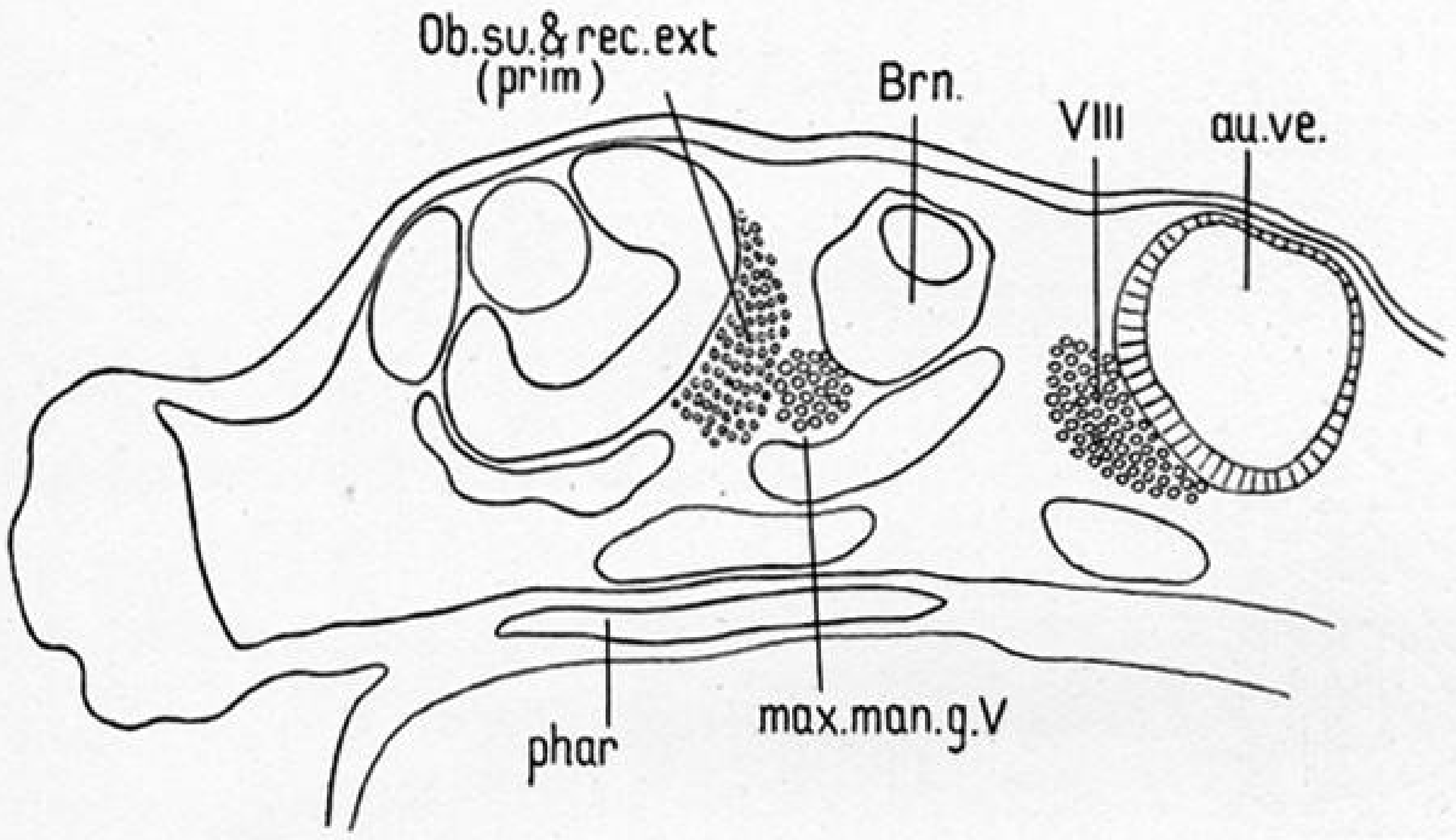

67

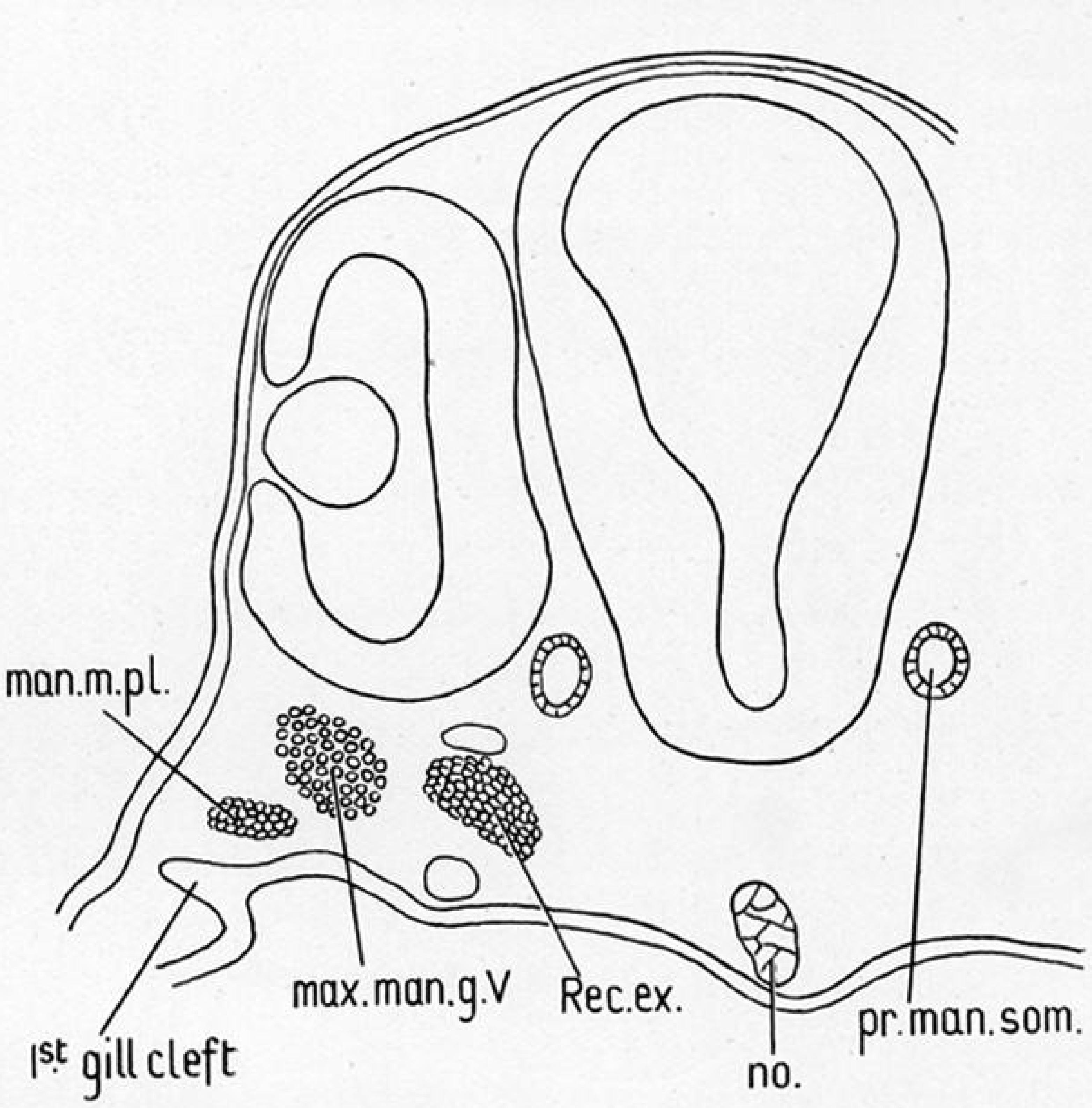

70

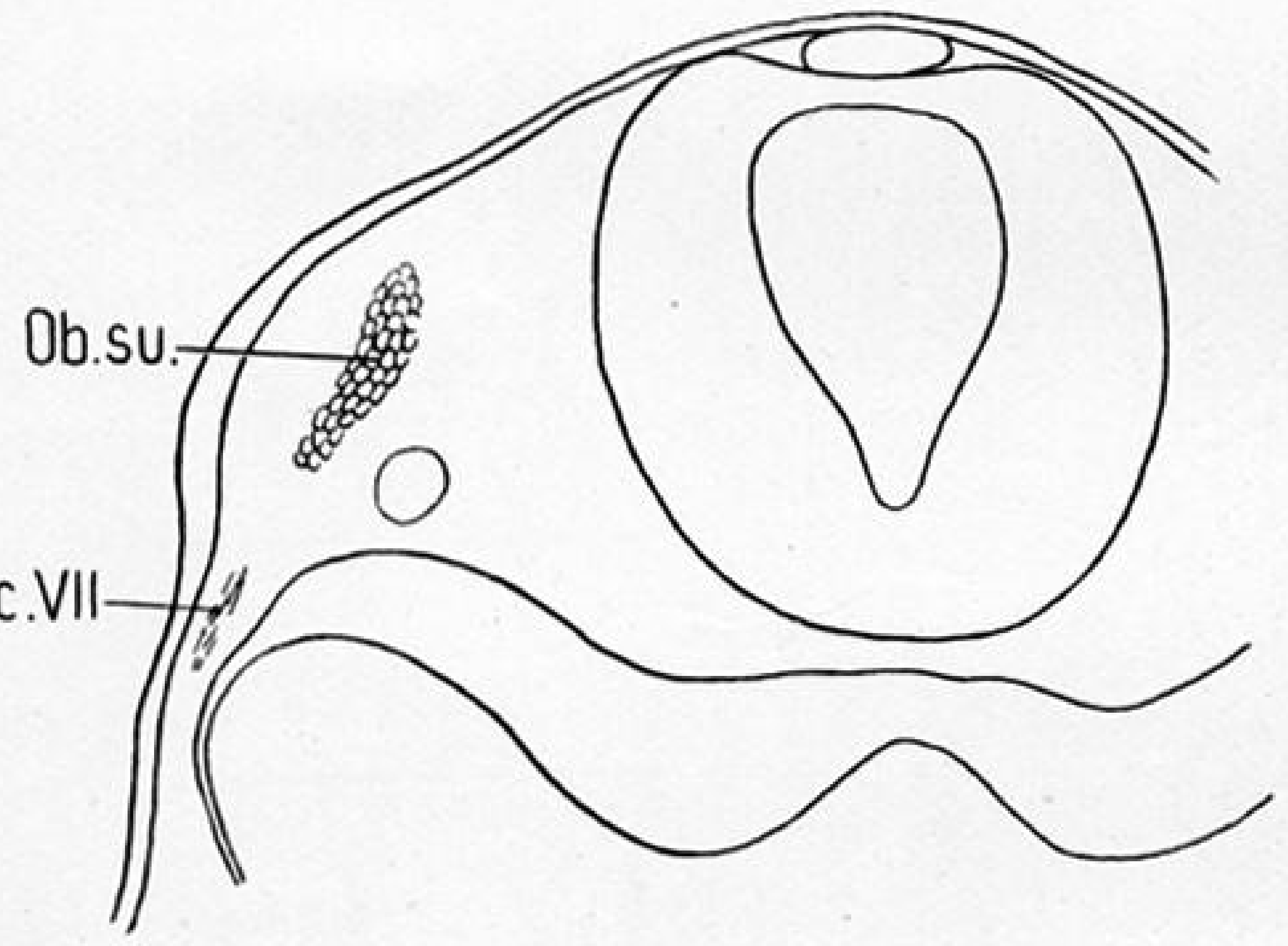

68

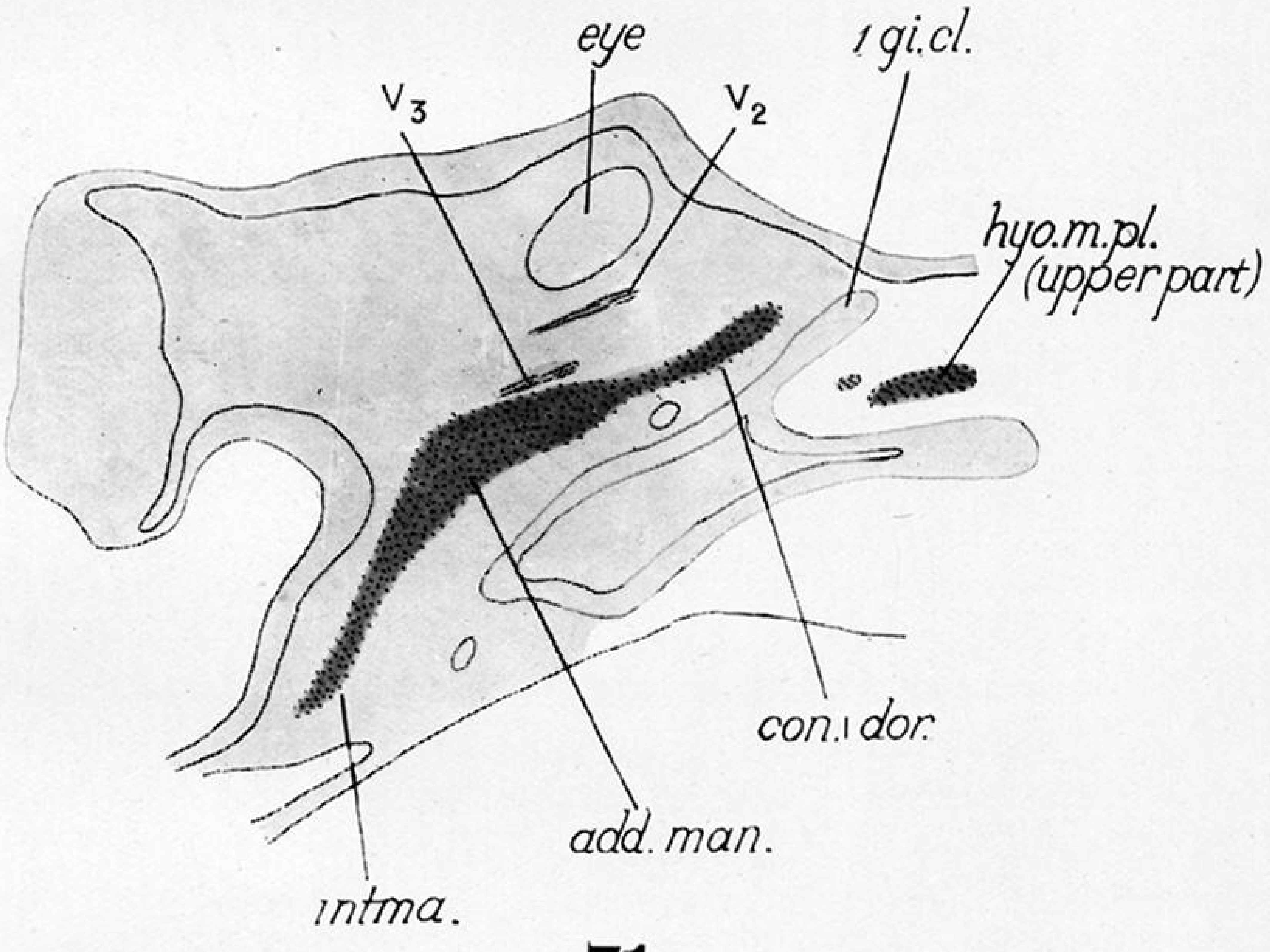

71

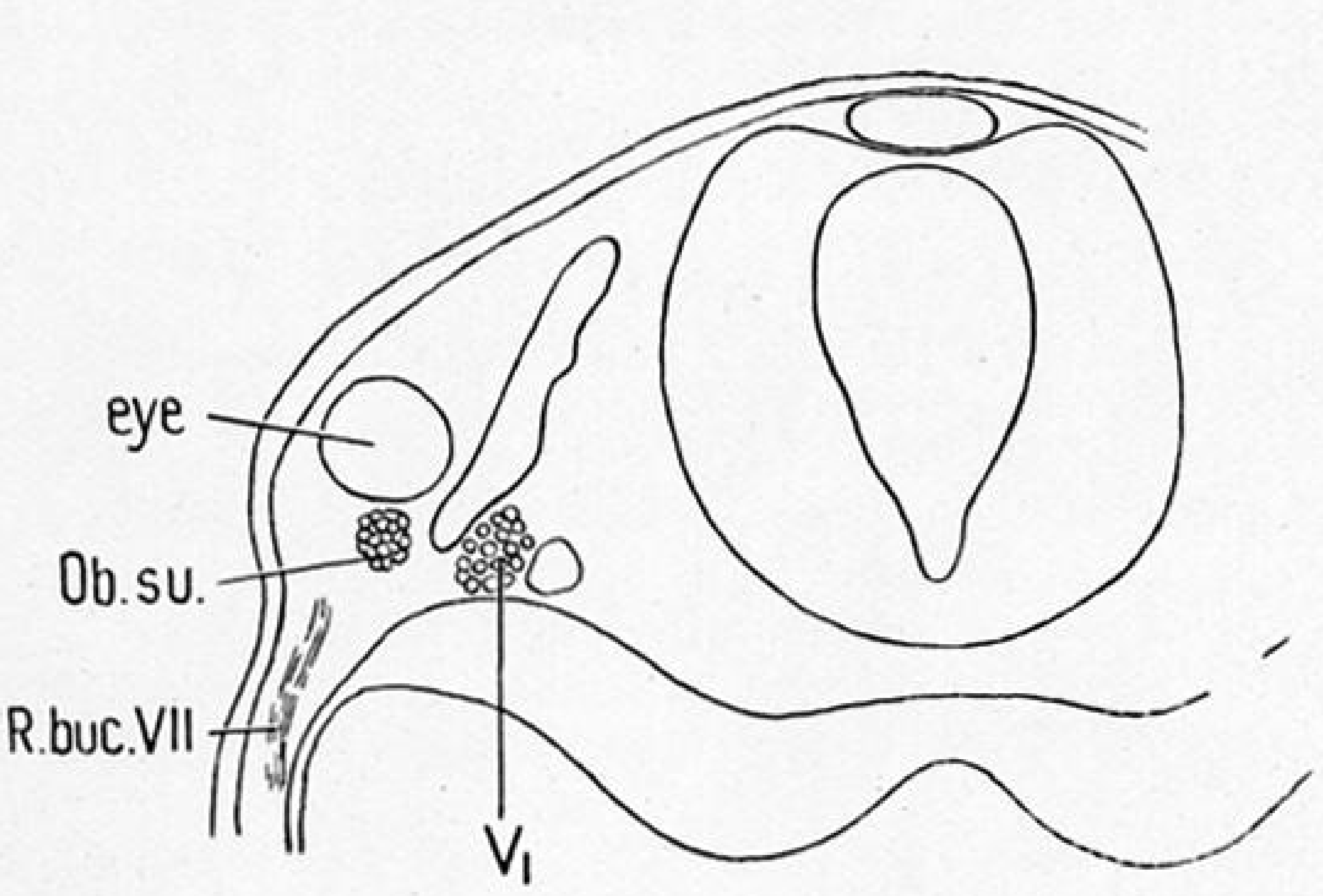

69

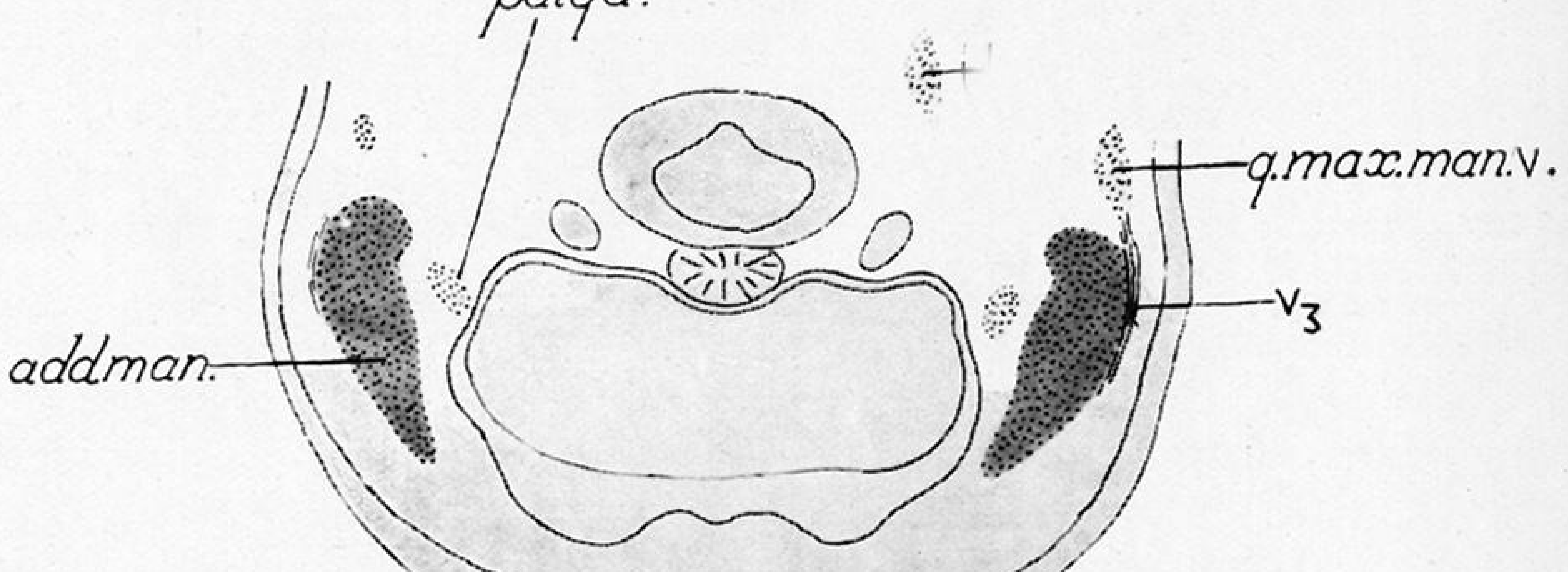

72

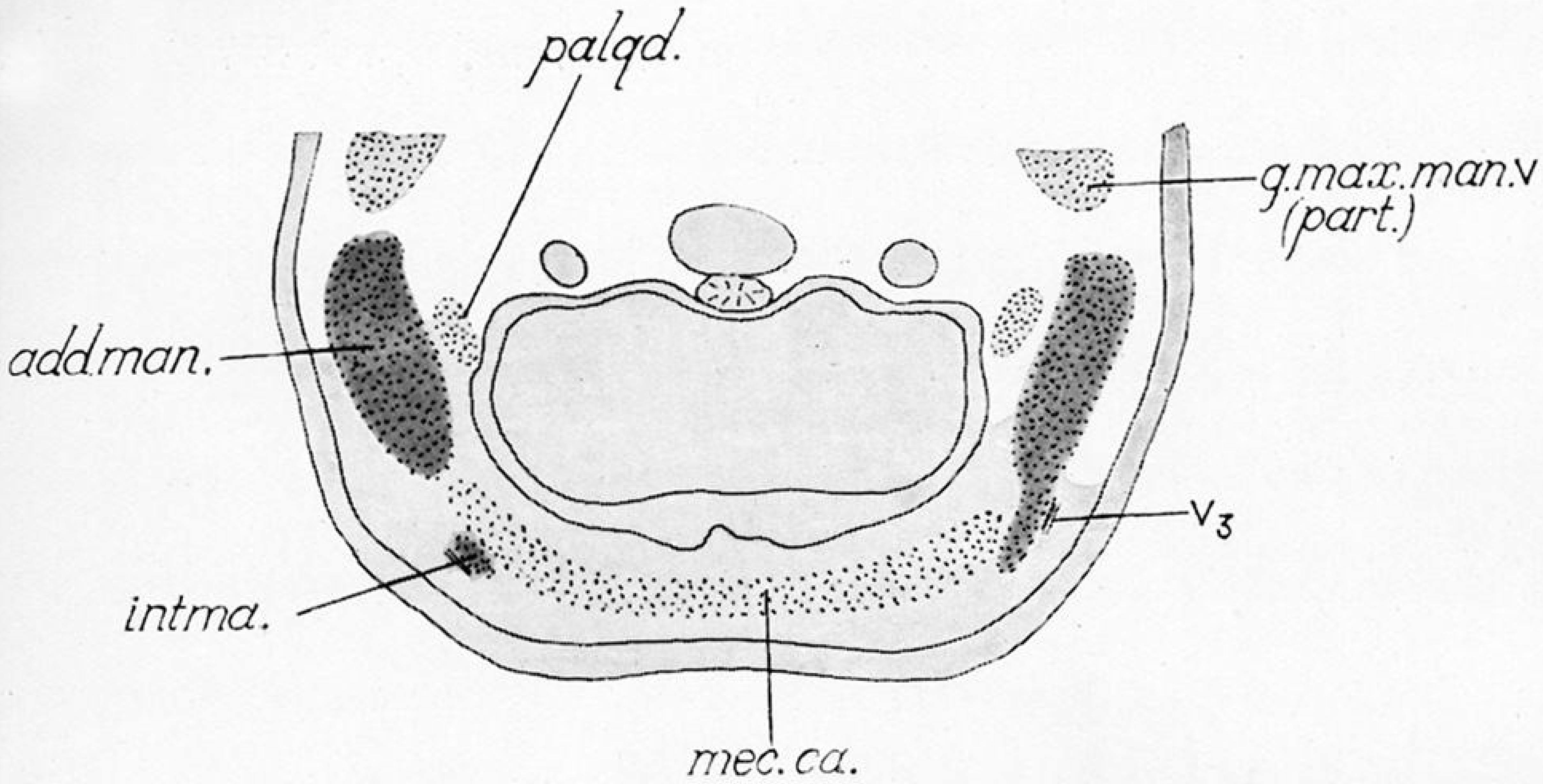

73

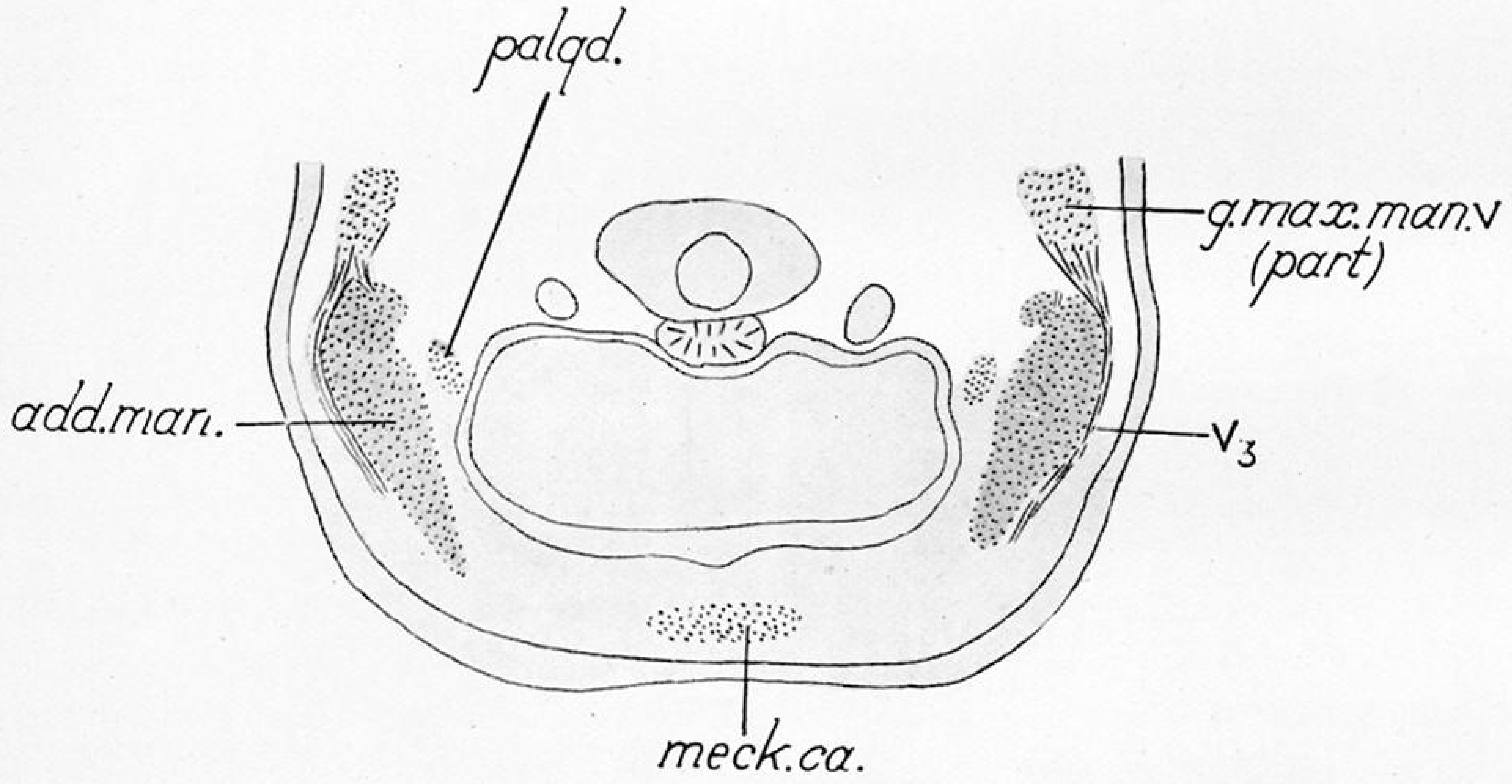

74

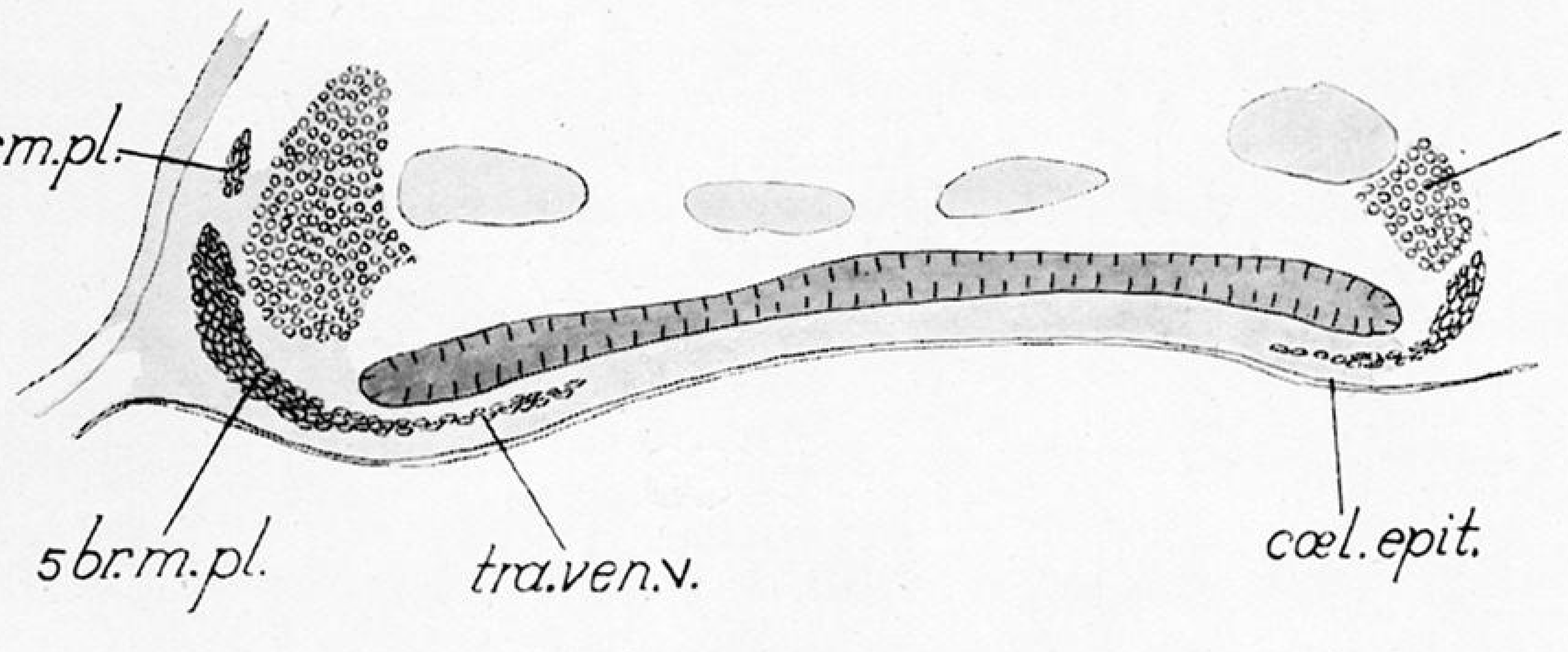

75

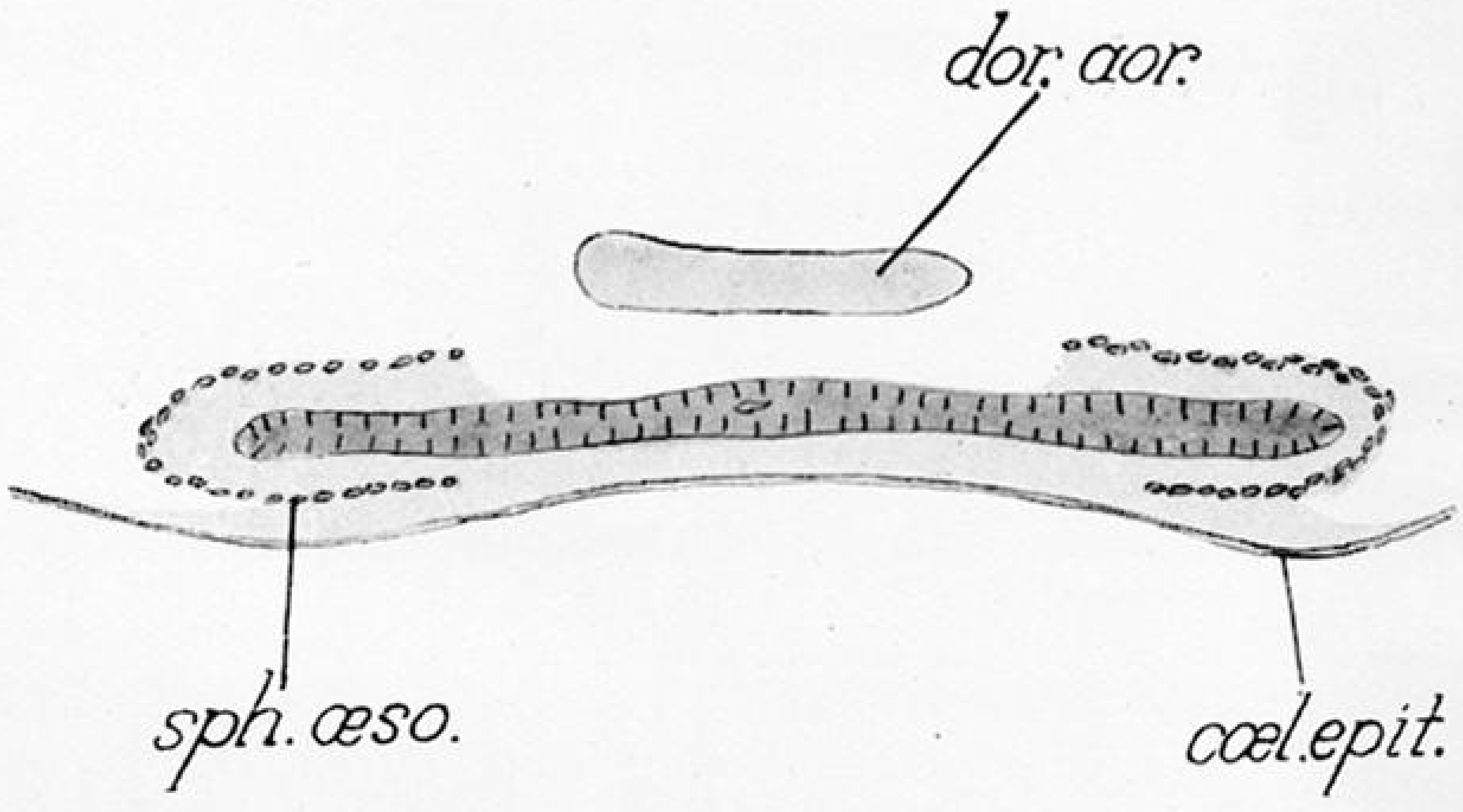

76

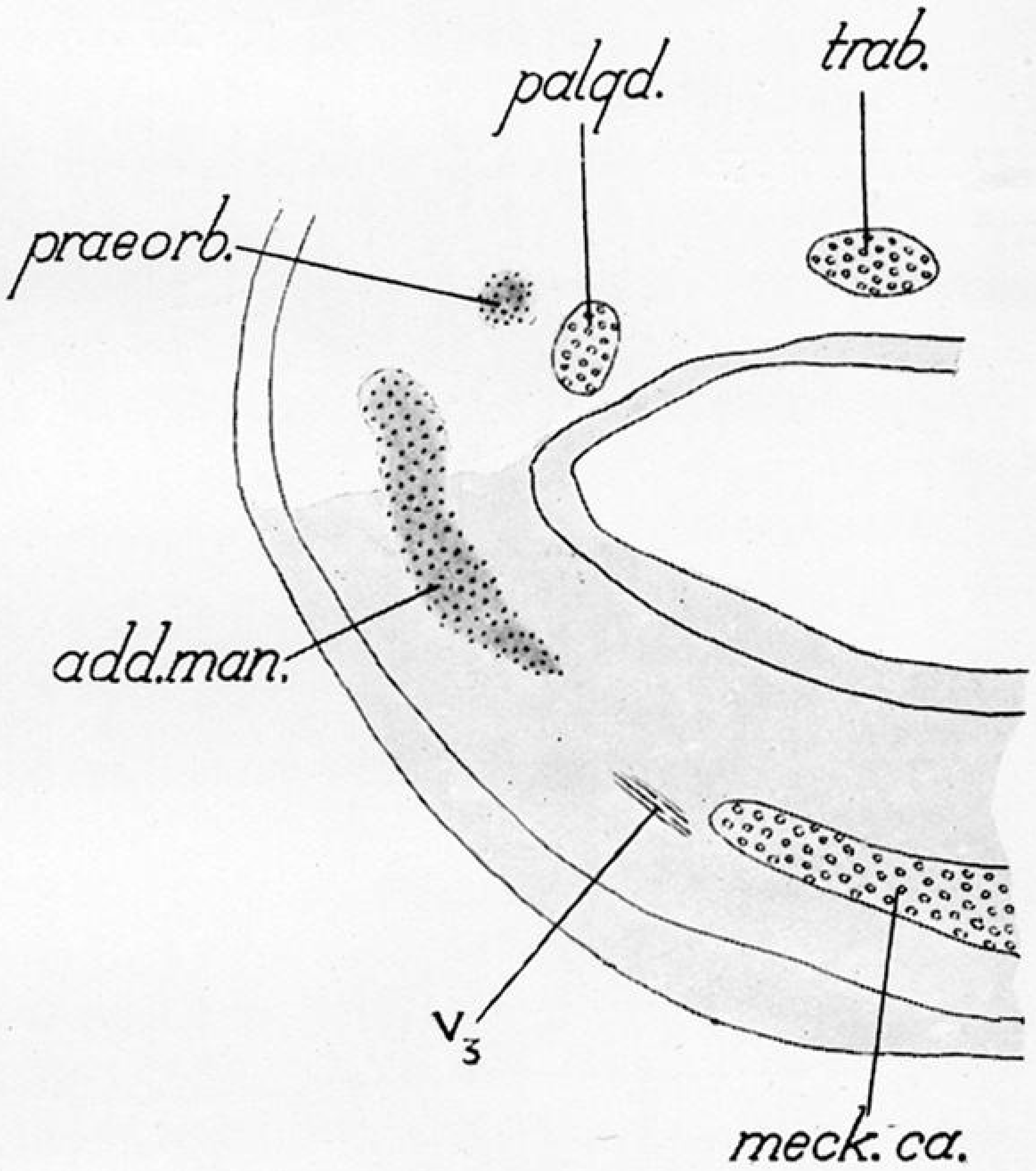

77

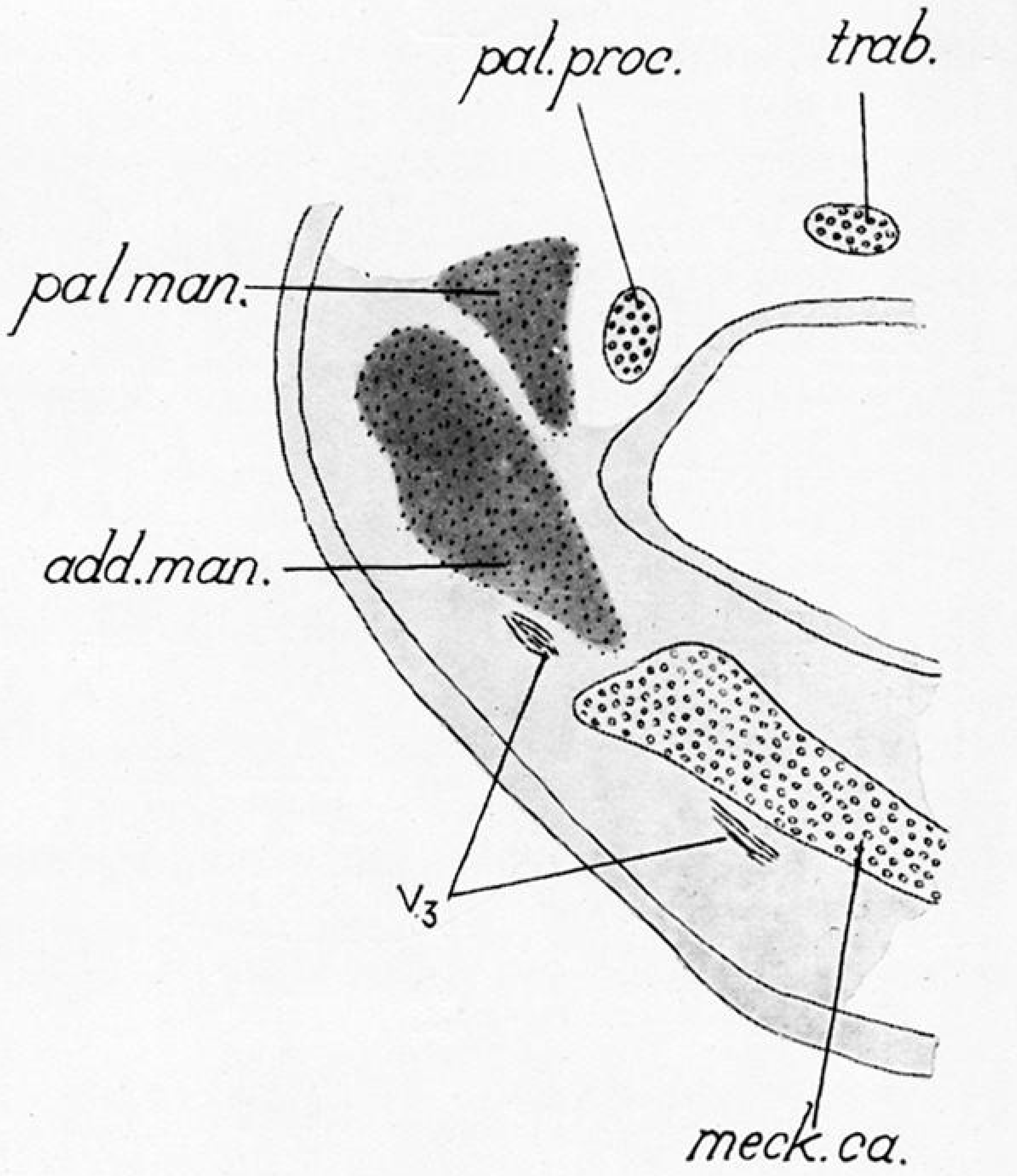

78

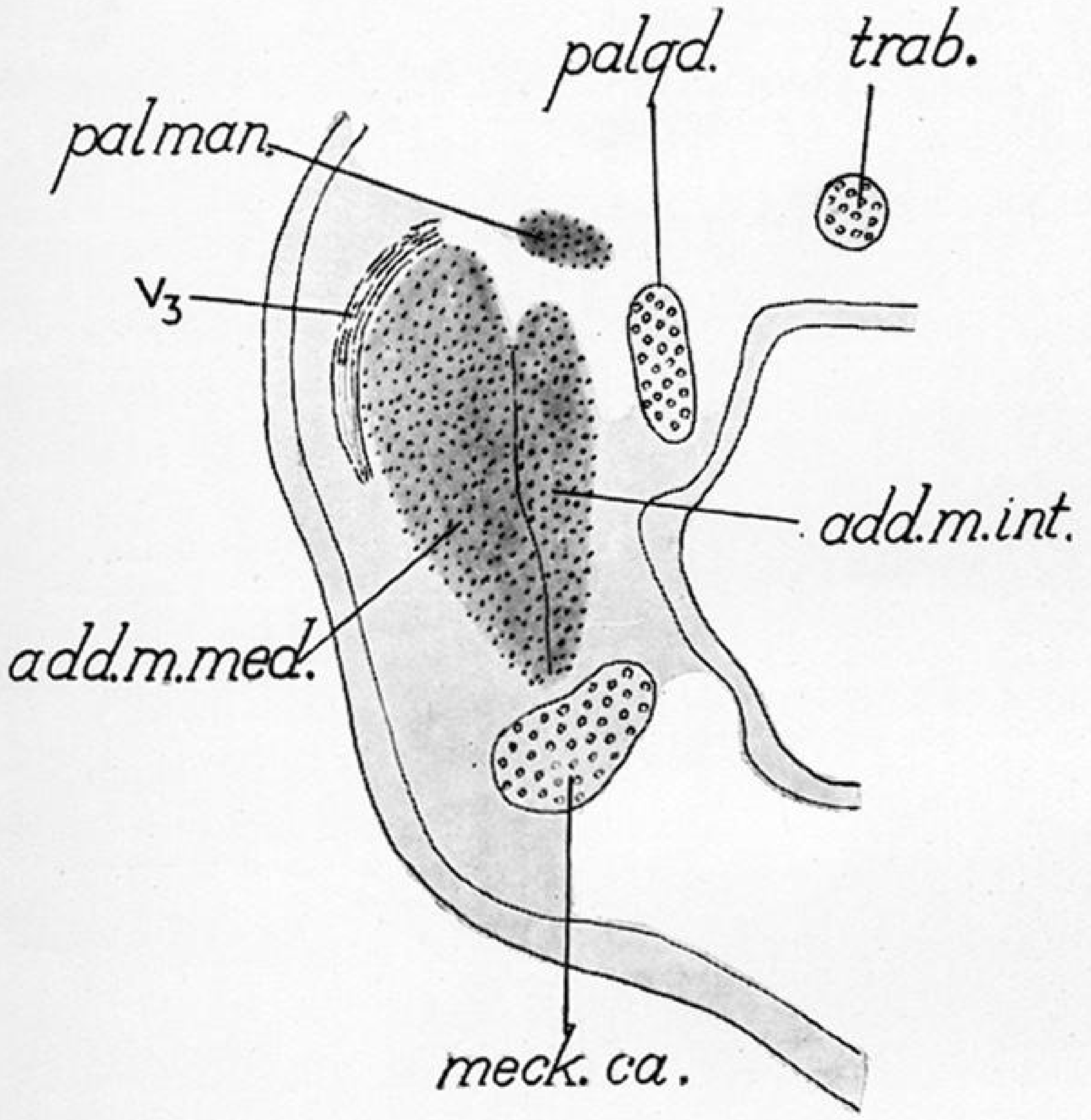
palqd.
trab.
palman.
V3
add.m.int.
add.m.med.
meck. ca.

79

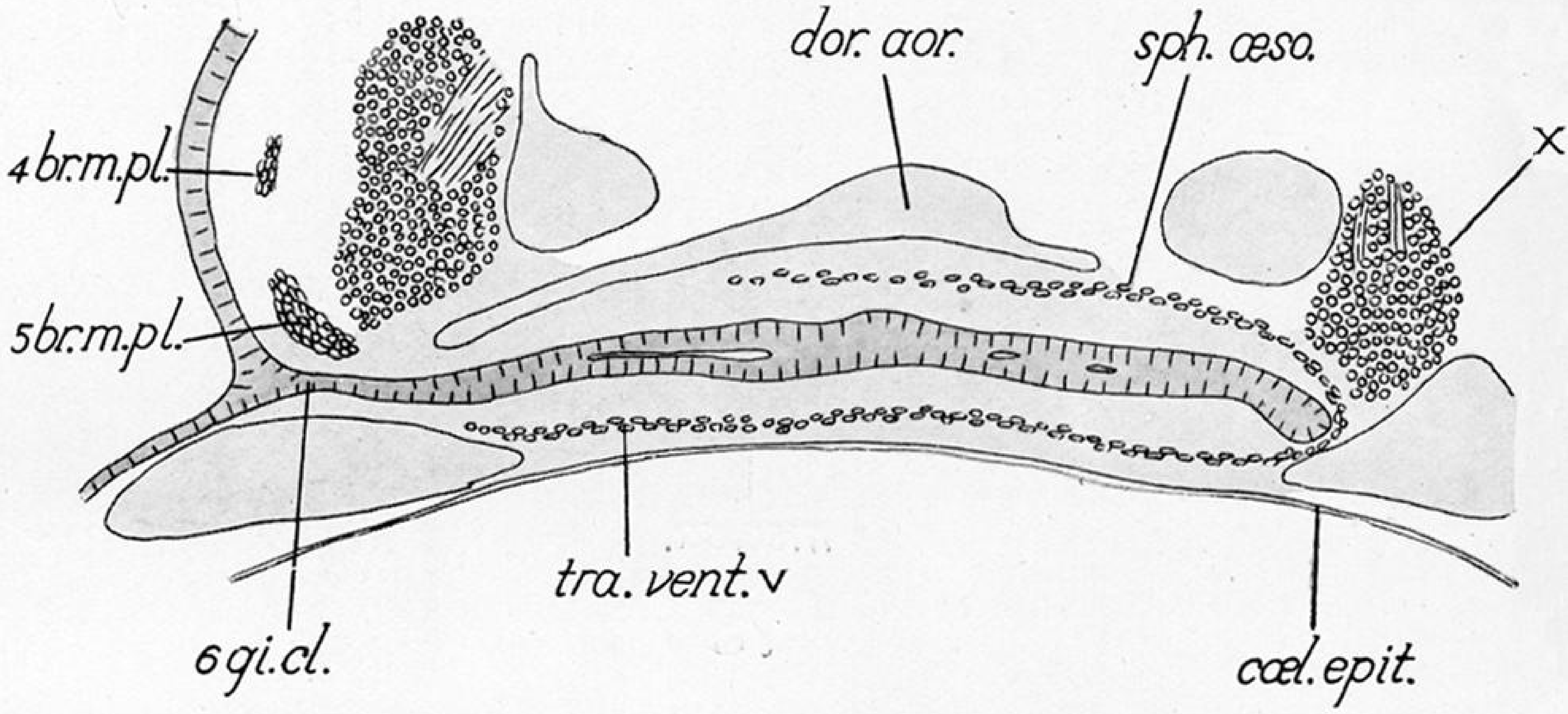
dor. aor.
sph. œso.
X
4br.m.pl.
5br.m.pl.
tra. vent. v
6gi.cl.
cœl. epit.

80

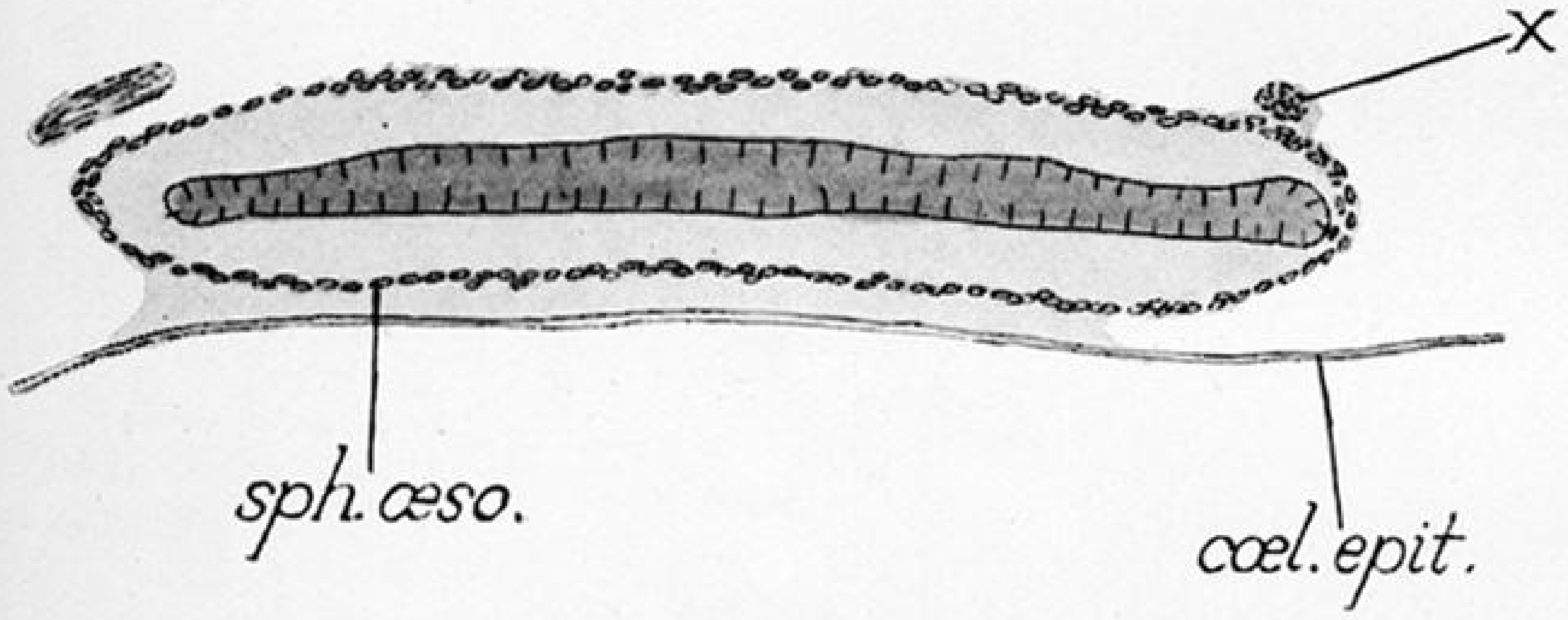
X
sph. œso.
cœl. epit.

81

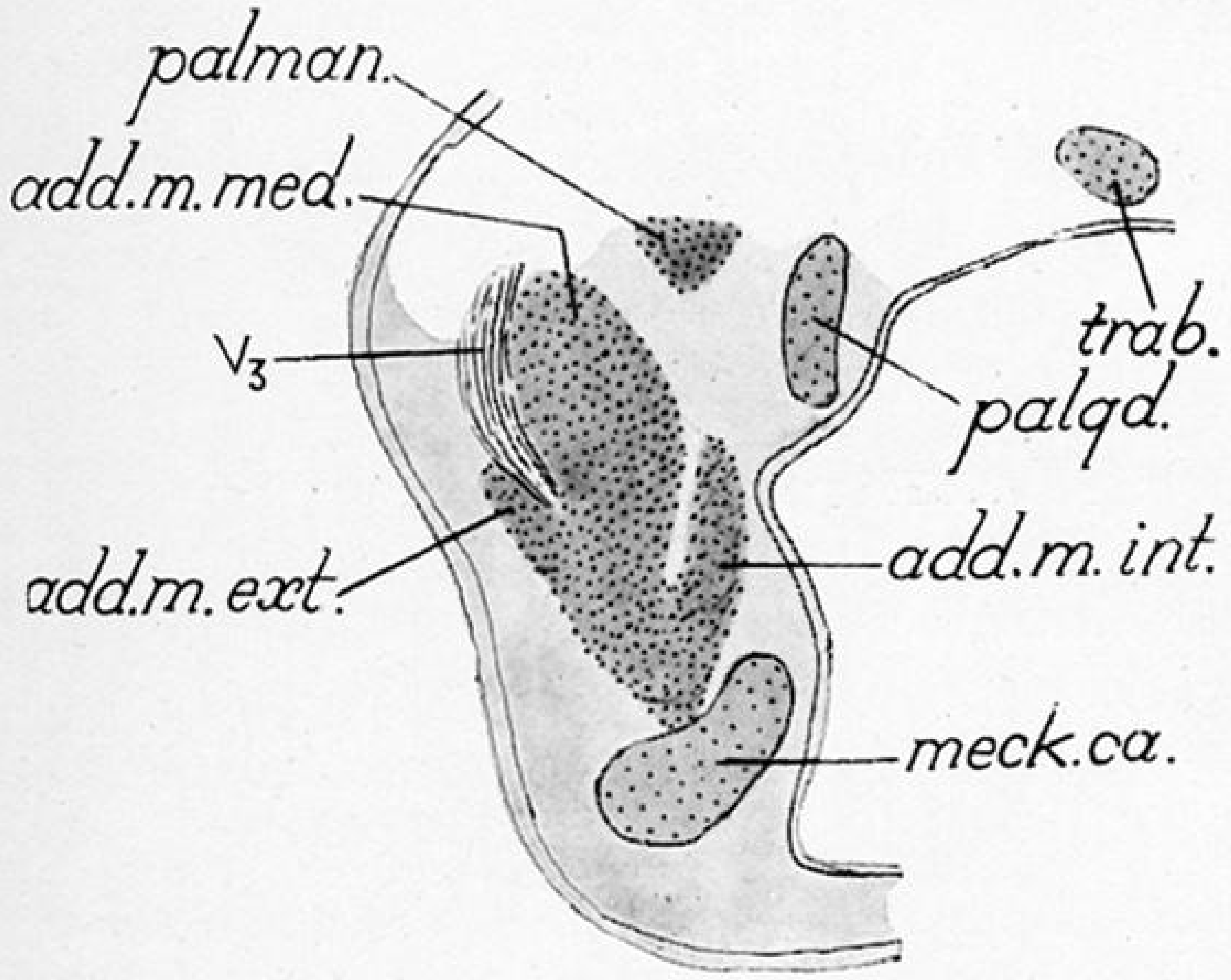
palman.
add.m.med.
V3
trab.
palqd.
add.m.ext.
add.m.int.
meck.ca.

82

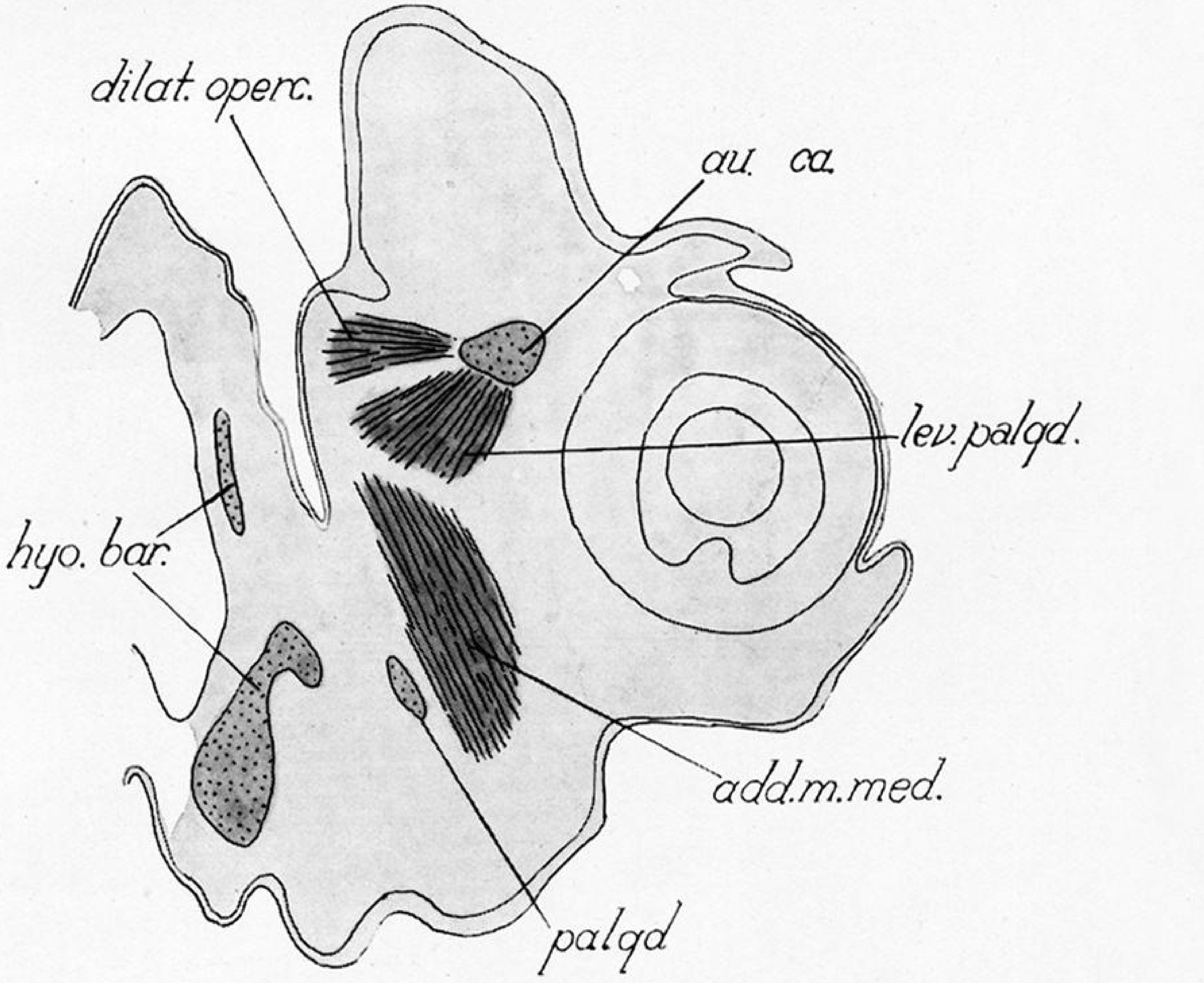
dilat. operc.
au. ca.
lev. palqd.
hyo. bar.
add.m.med.
palqd

83

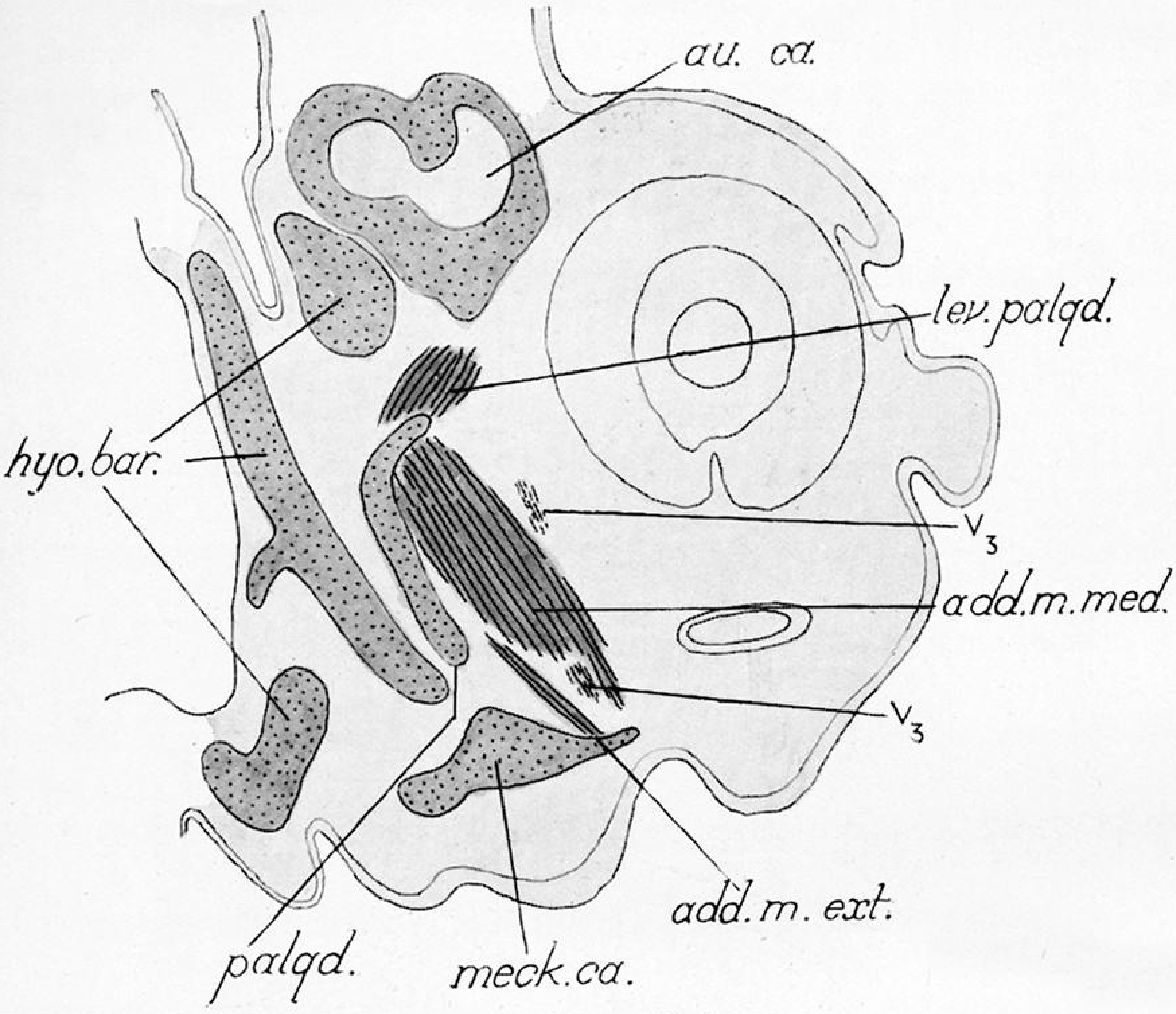

84

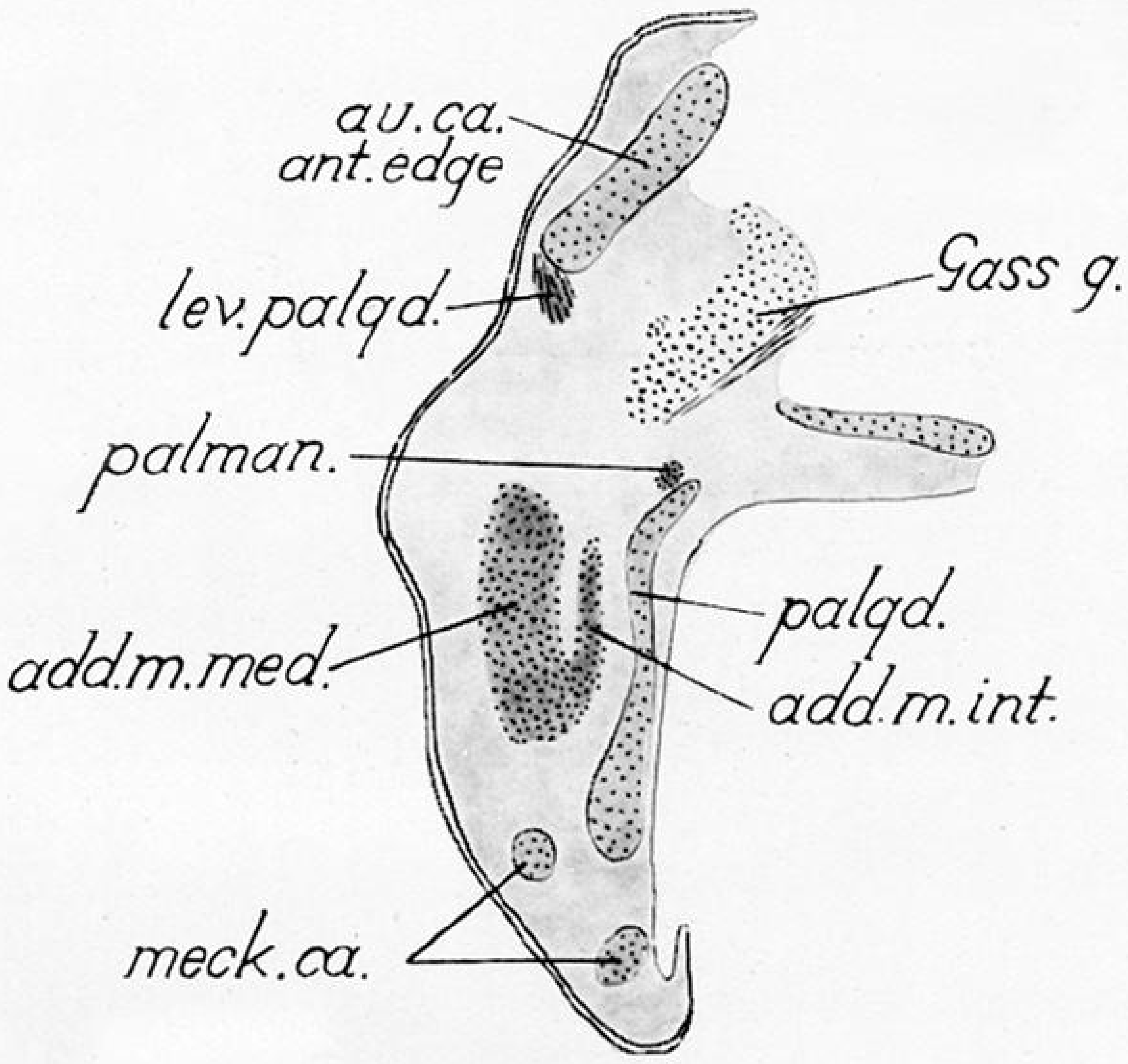

85

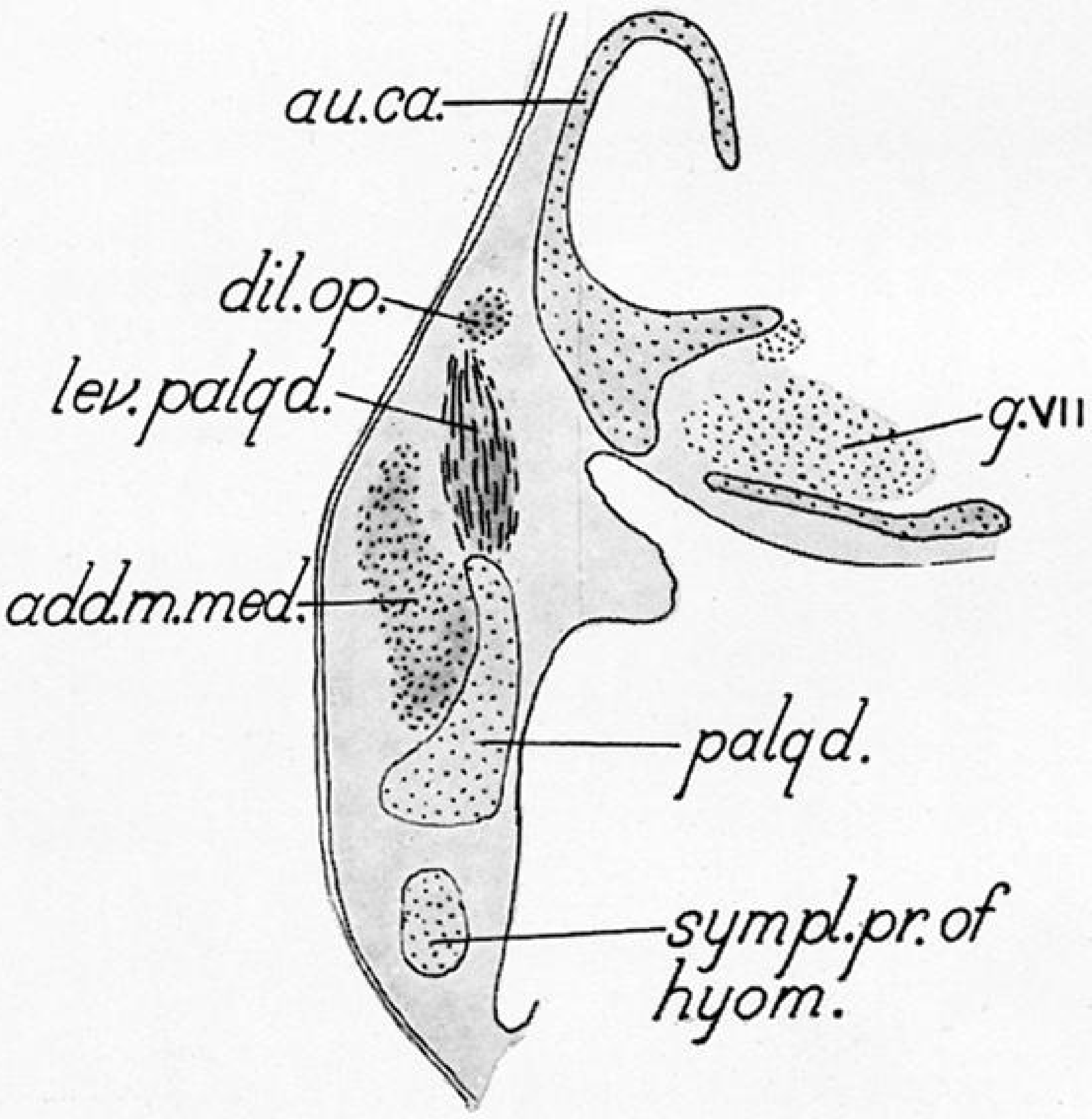

86

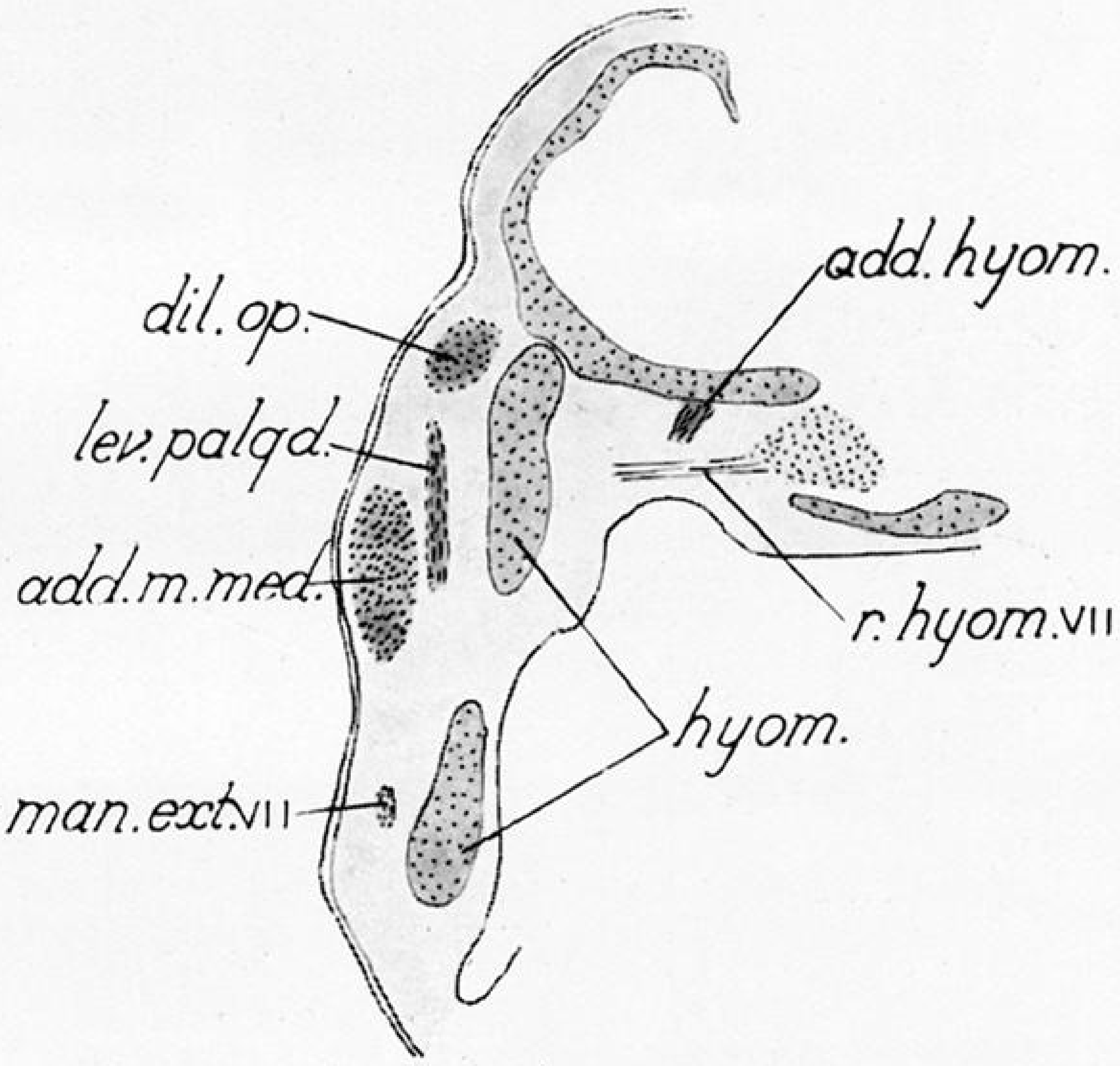

87

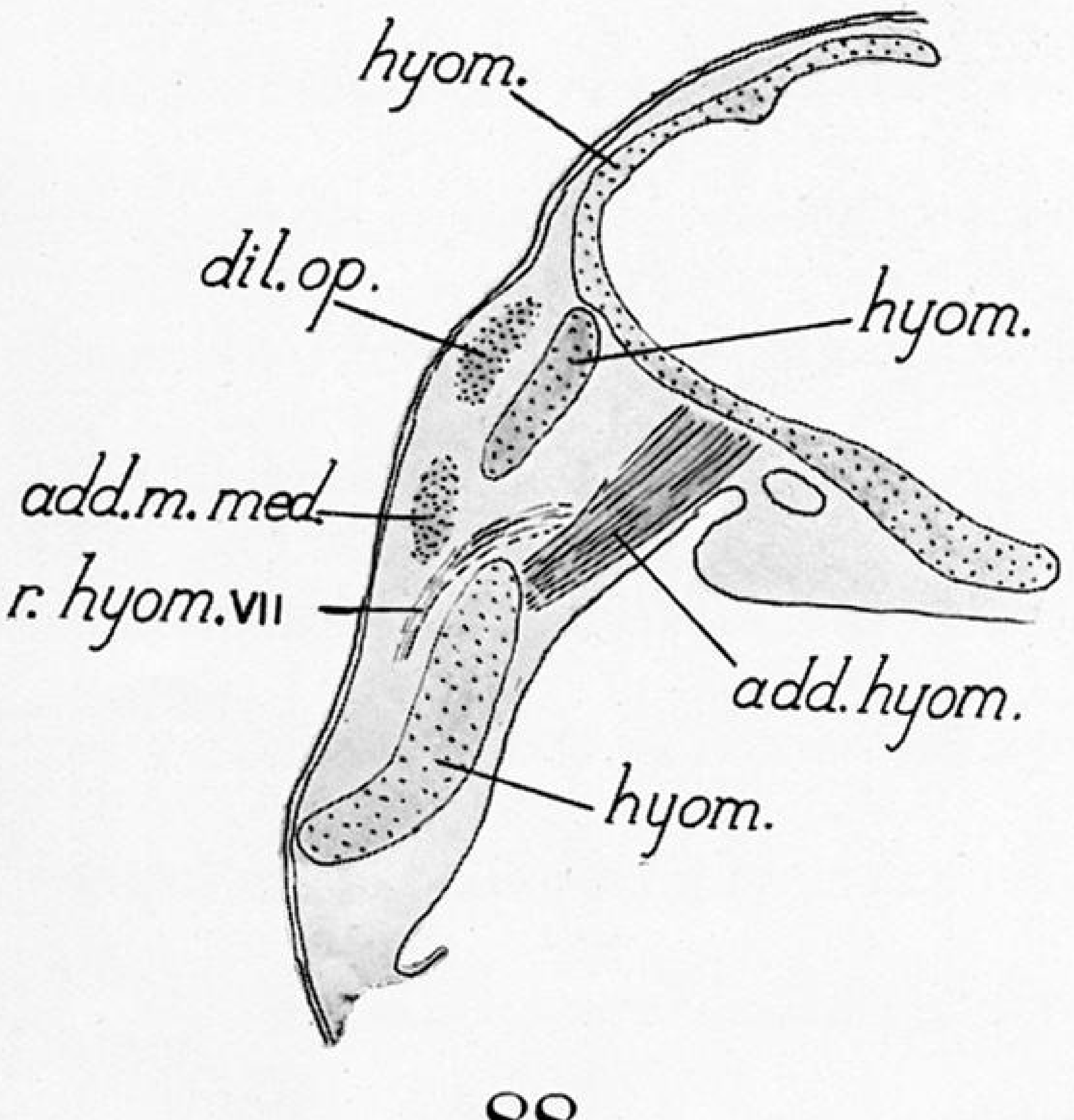

88

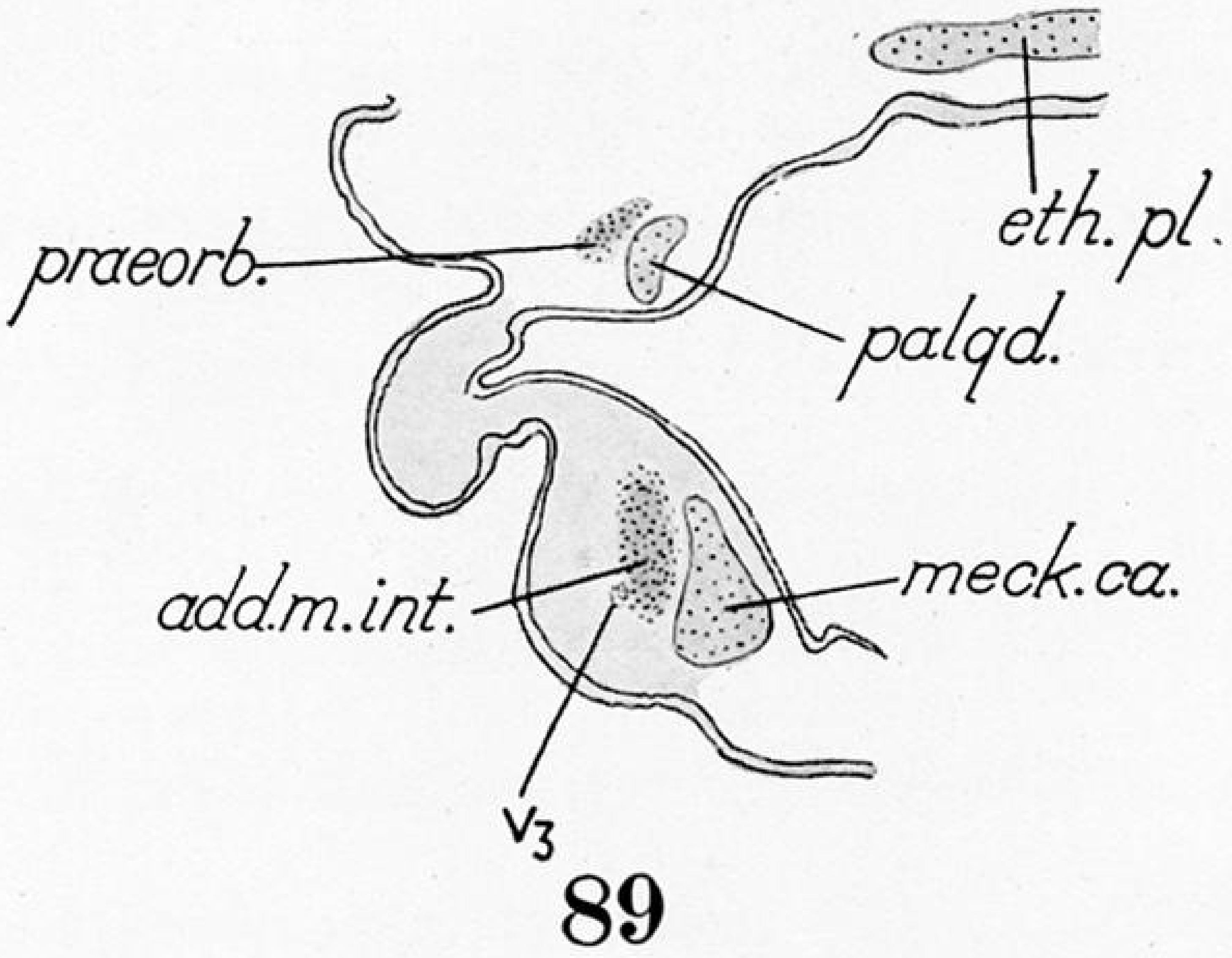

89

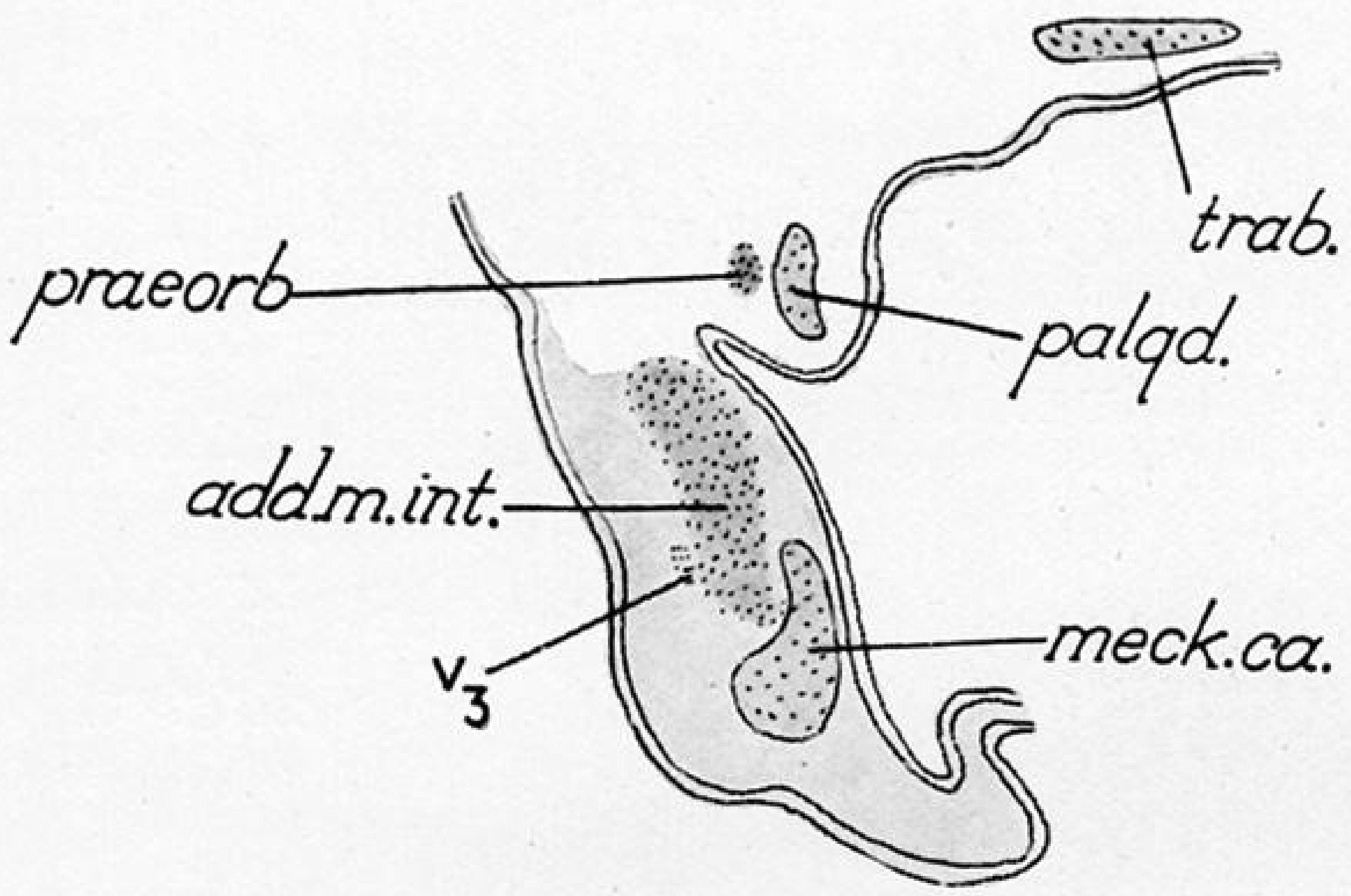
trab.
praeorb
palqd.
add.m.int.
V_3
meck.ca.

90

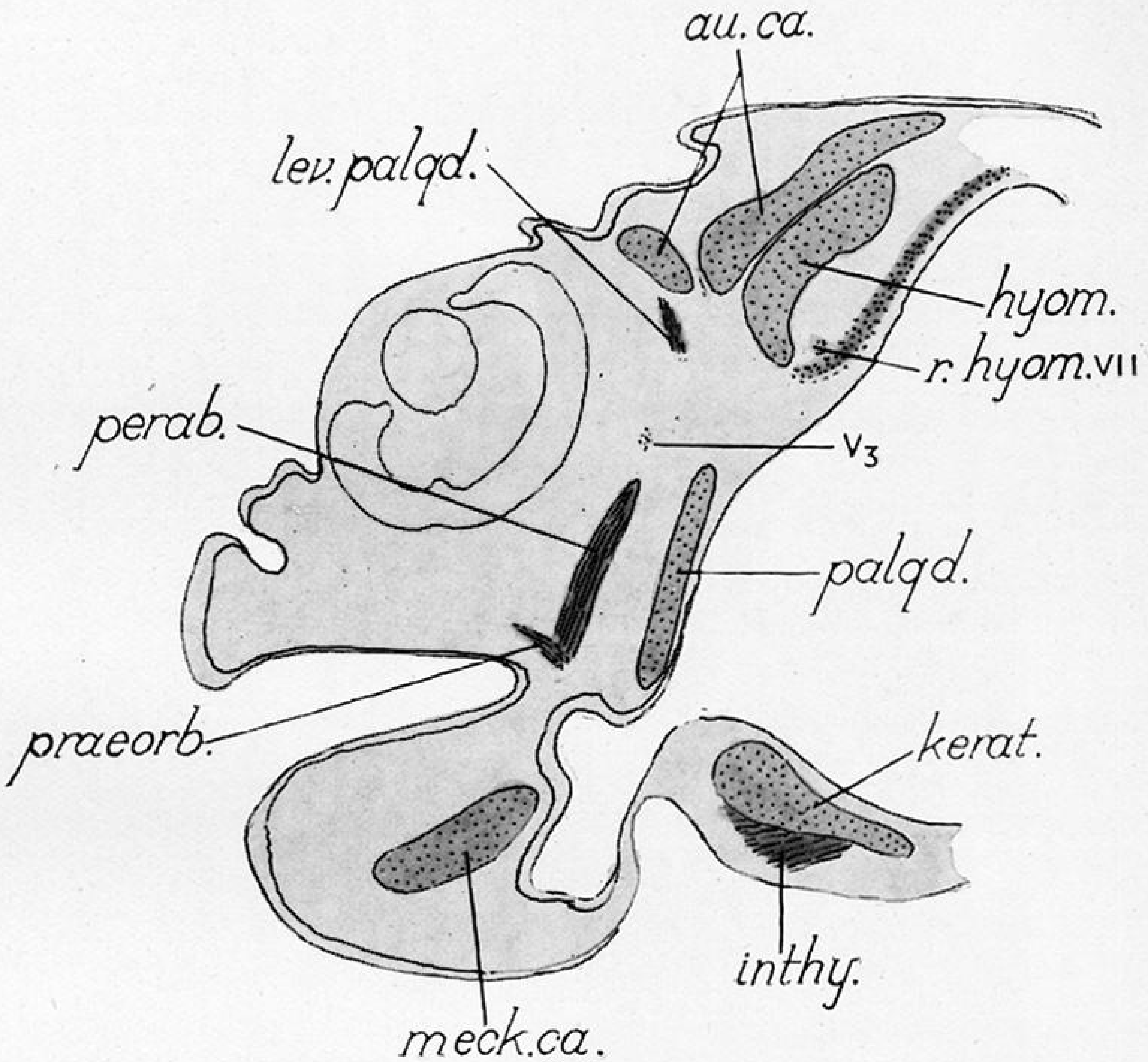
au.ca.
lev.palqd.
hyom.
r.hyom.VII
perab.
V_3
palqd.
praeorb.
kerat.
inthy.
meck.ca.

91

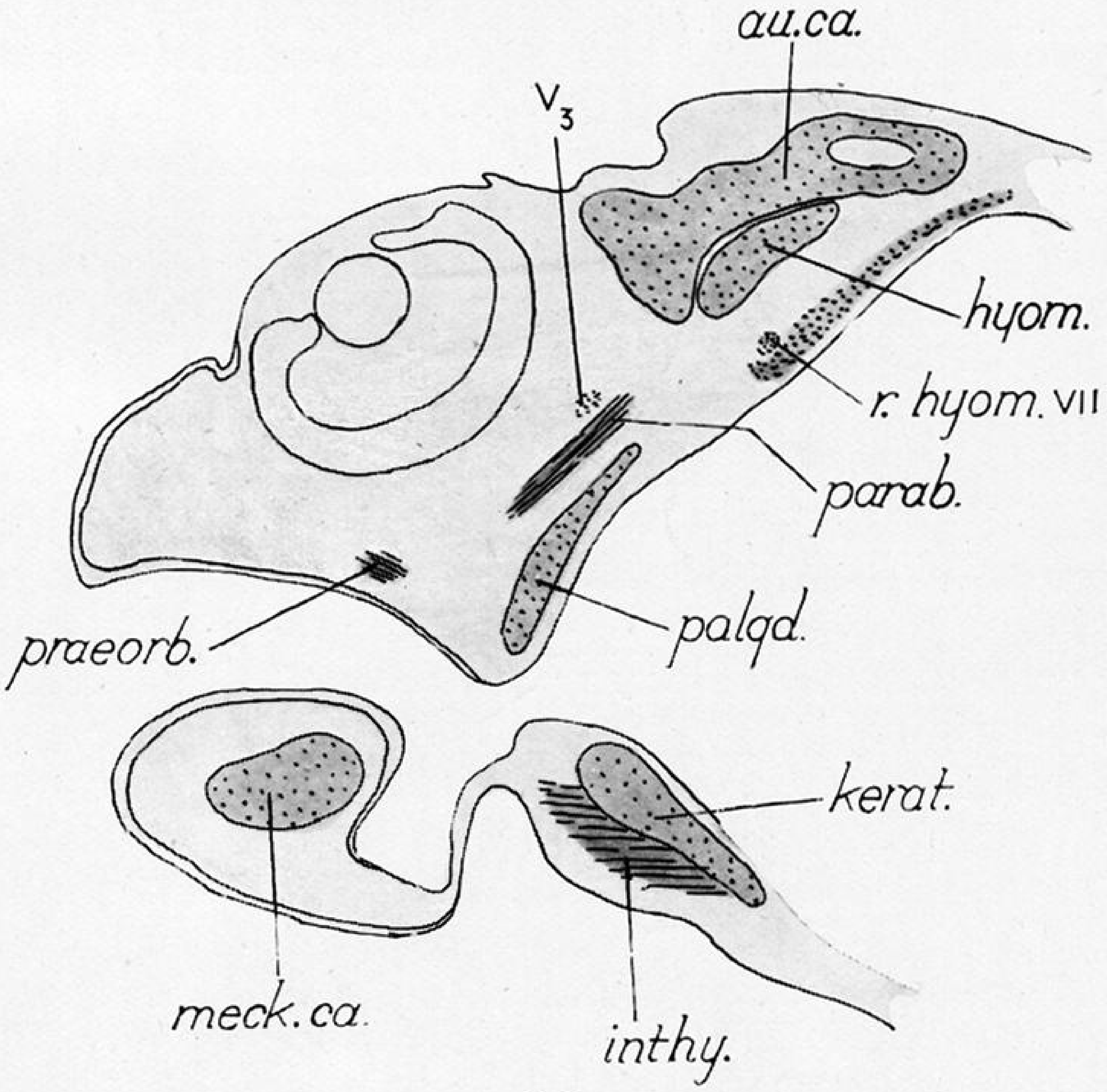
au.ca.
V_3
hyom.
r.hyom.VII
parab.
praeorb.
palqd.
kerat.
meck.ca.
inthy.

92

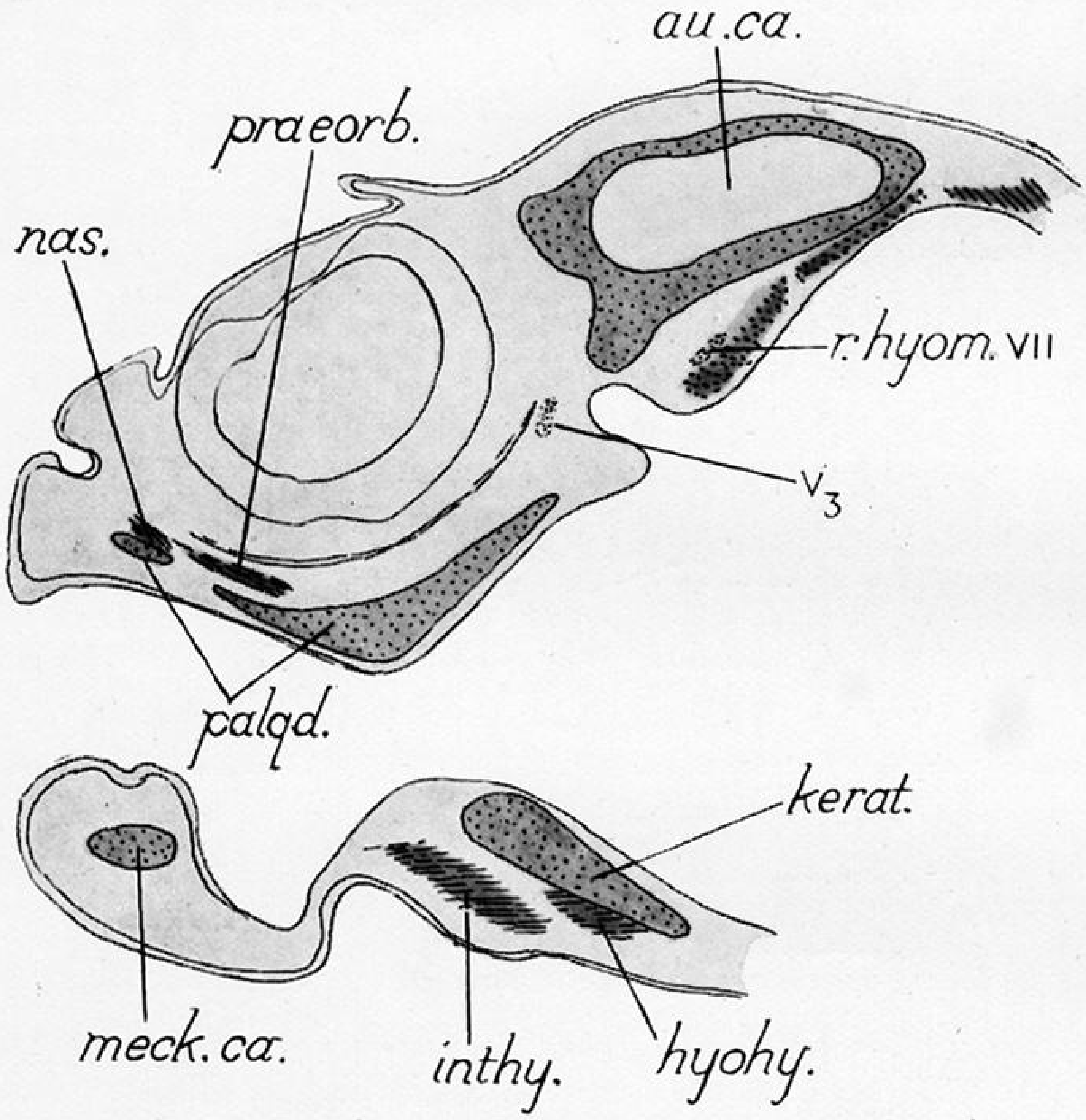
au.ca.
praeorb.
nas.
r.hyom.VII
V_3
palqd.
kerat.
meck.ca.
inthy.
hyohy.

93

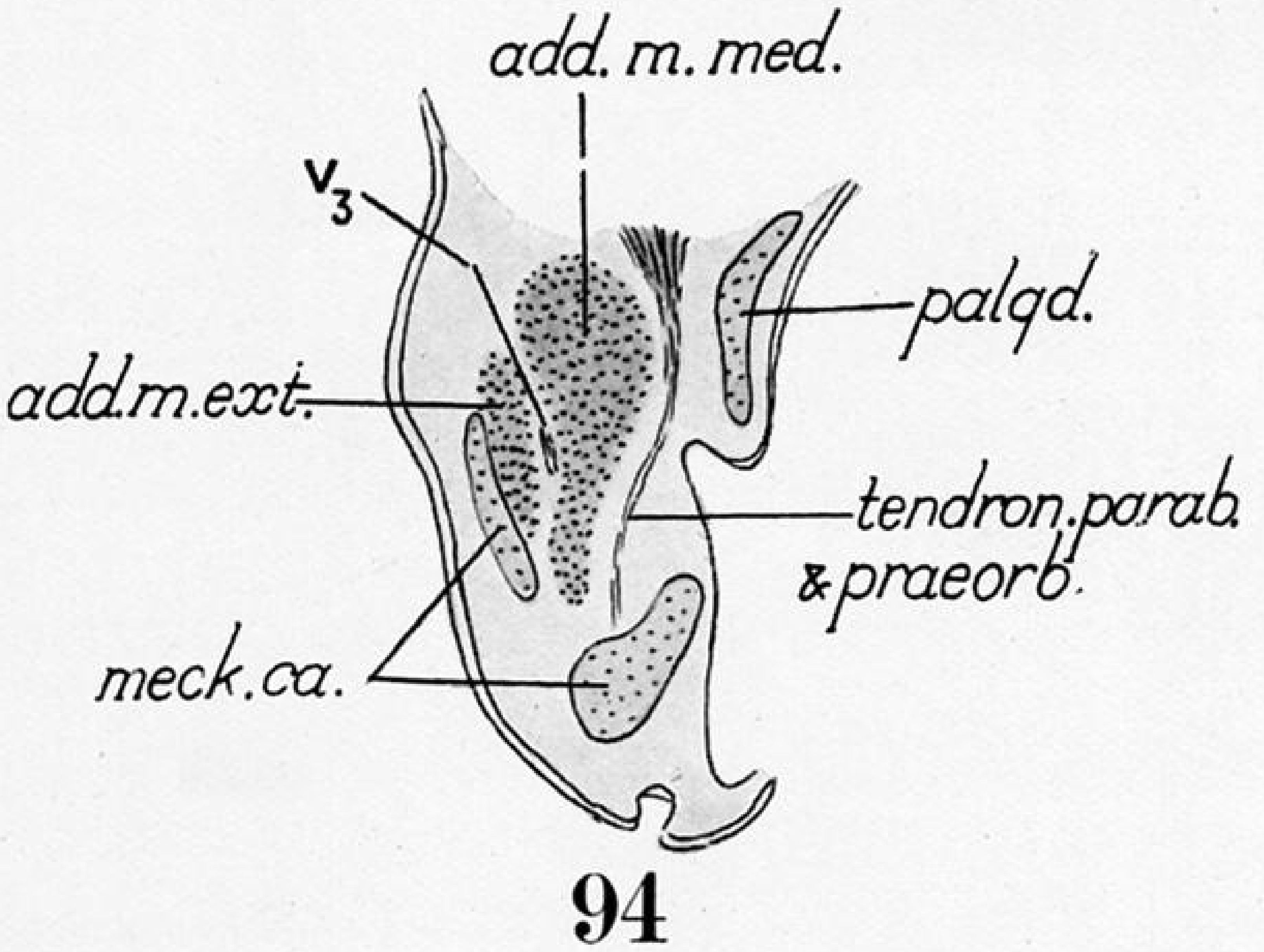
add.m.med.
V_3
palqd.
add.m.ext.
tendron.parab. & praeorb.
meck.ca.

94

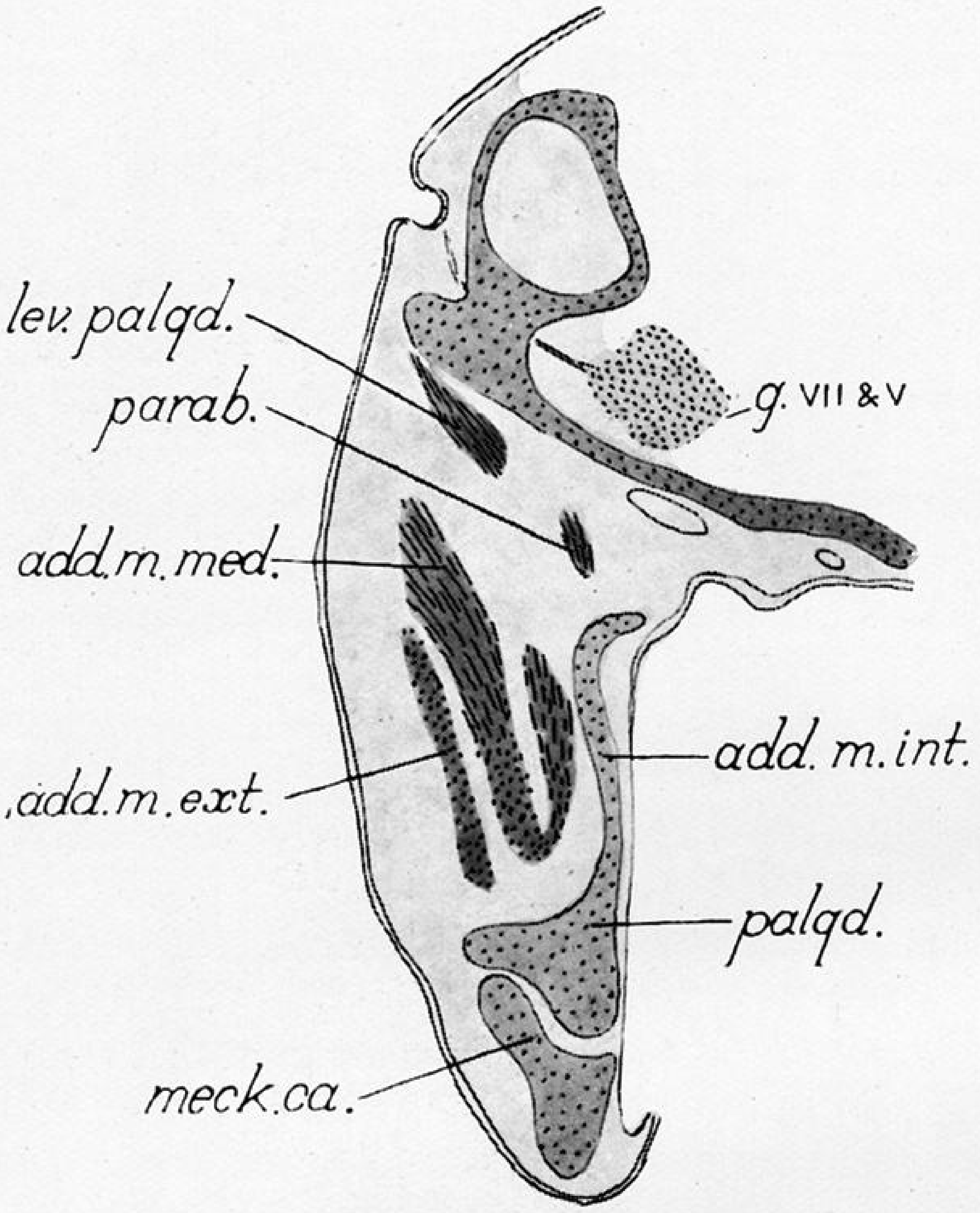

95

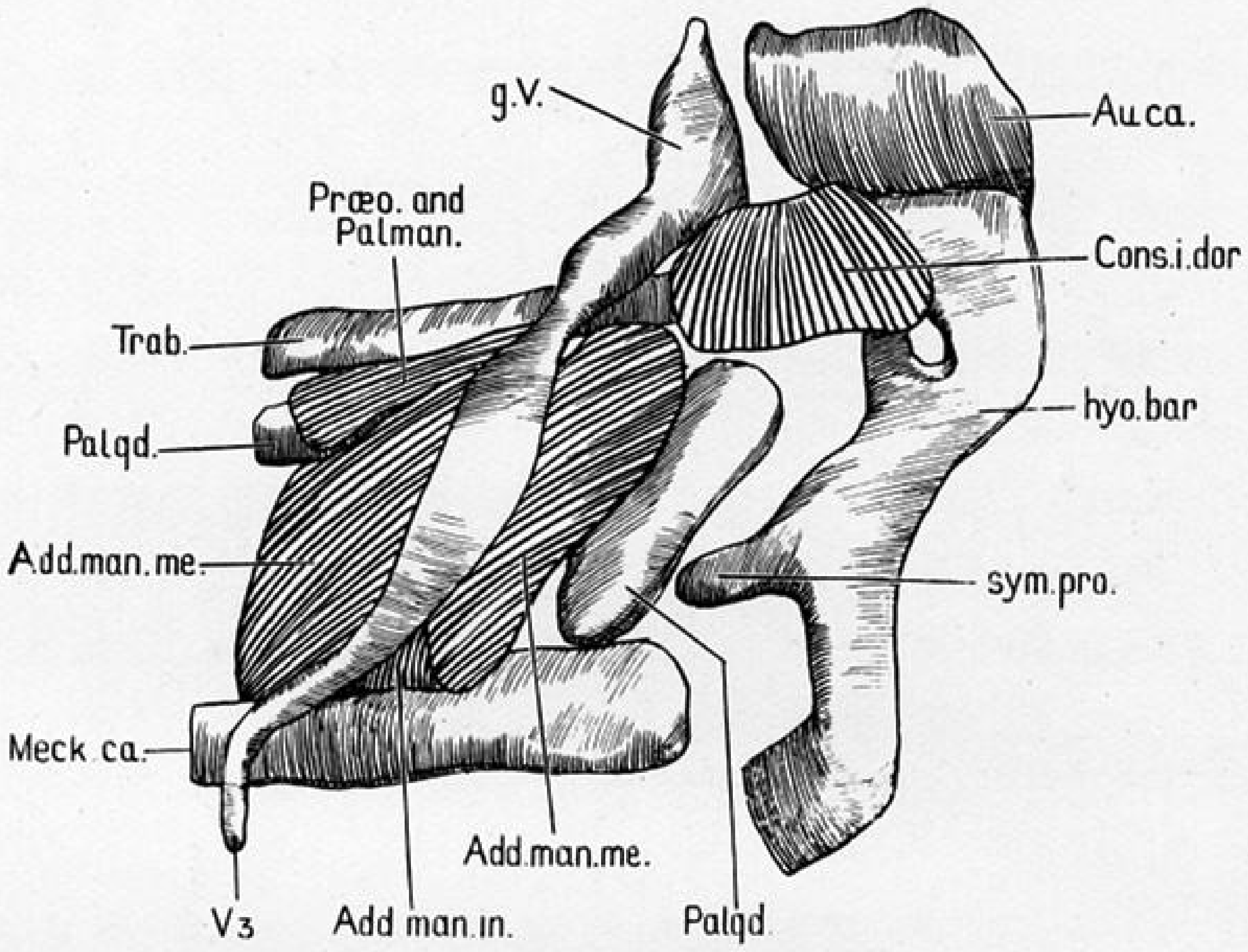

96

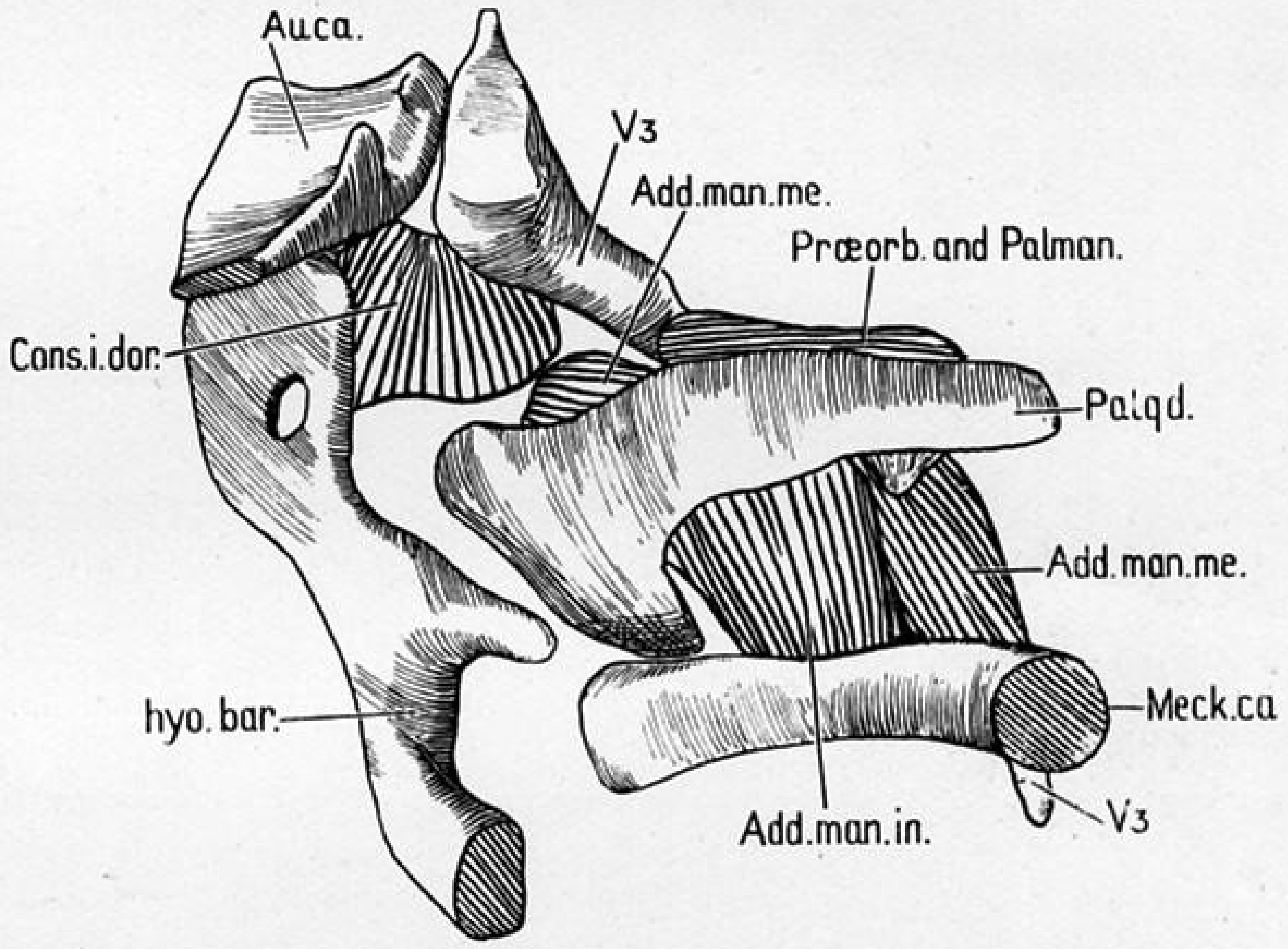

97

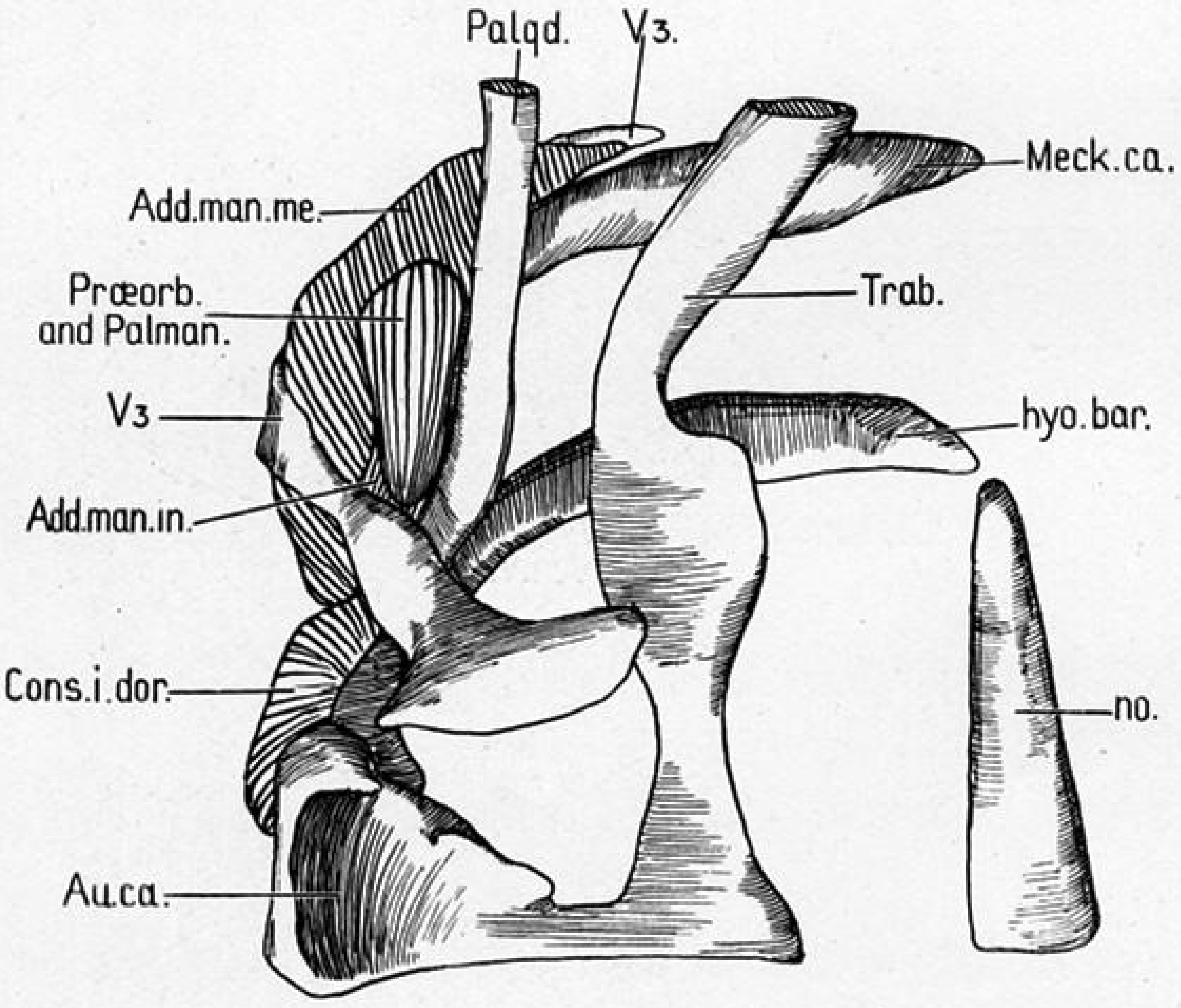

98

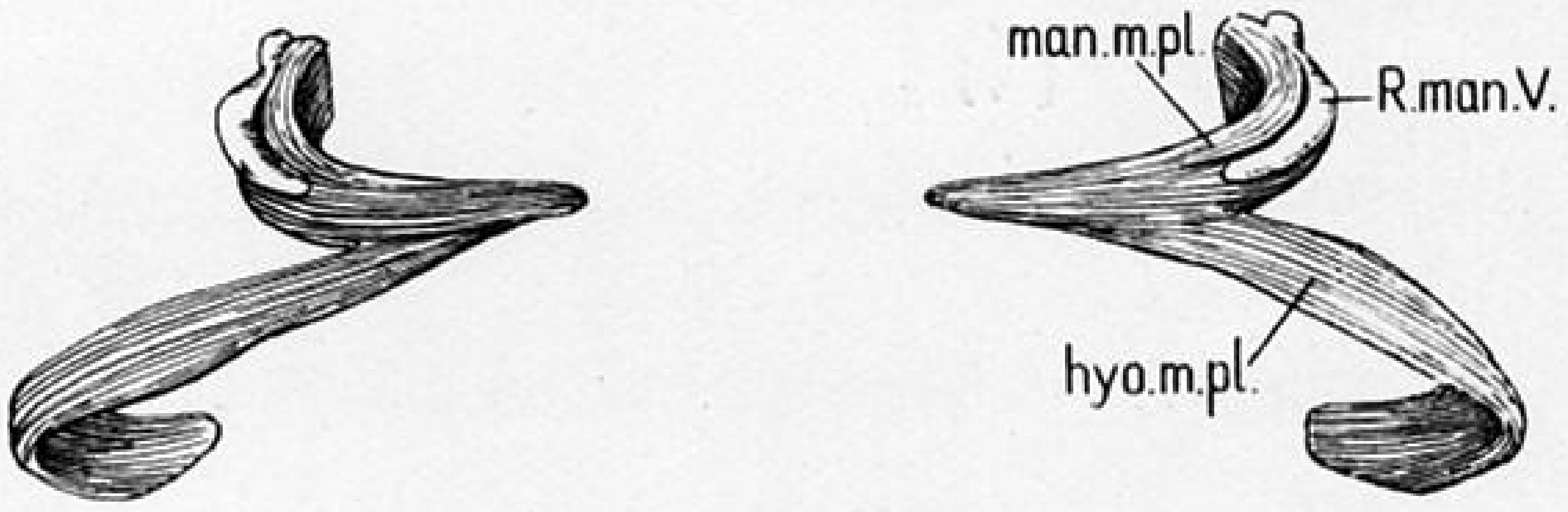

99

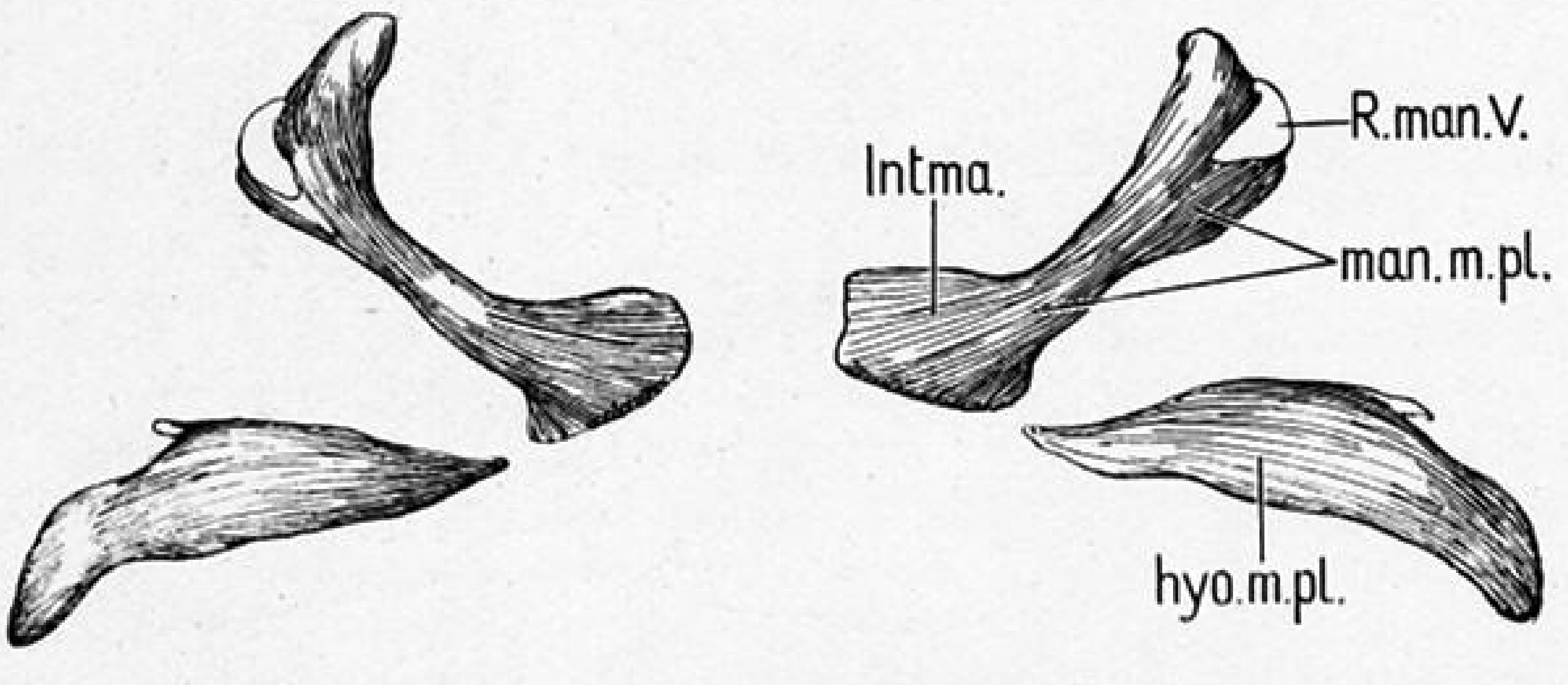

100

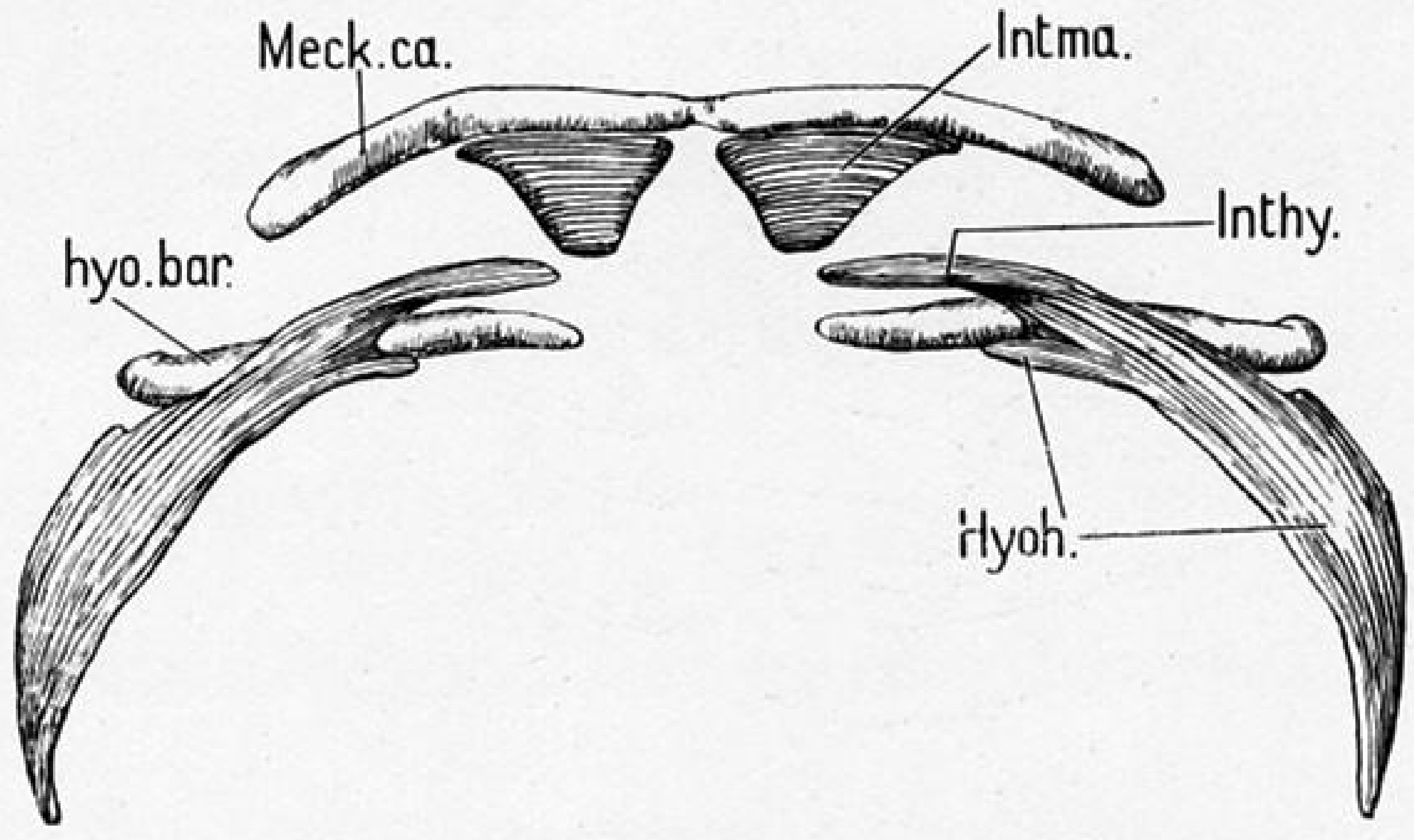

101

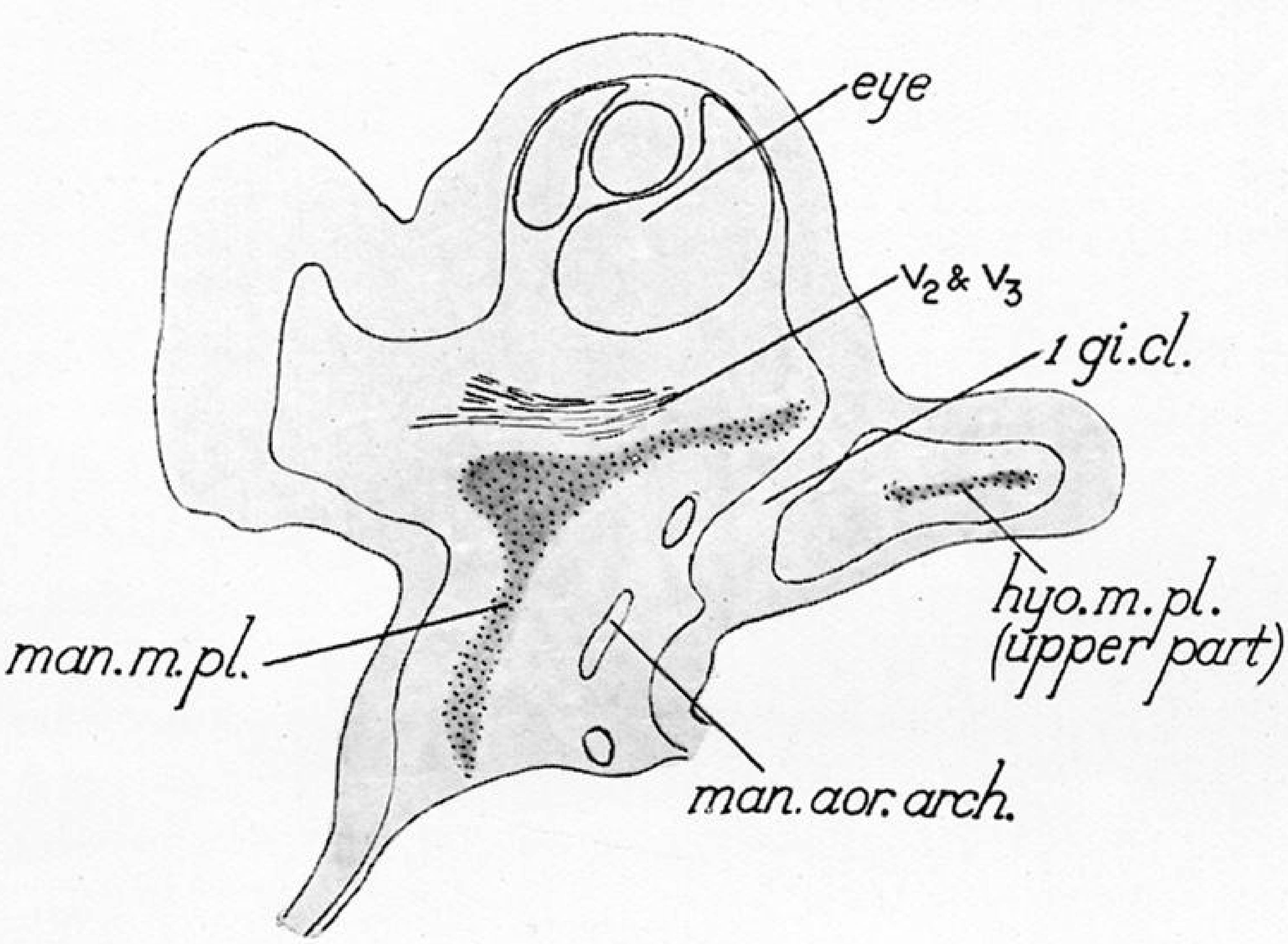

114

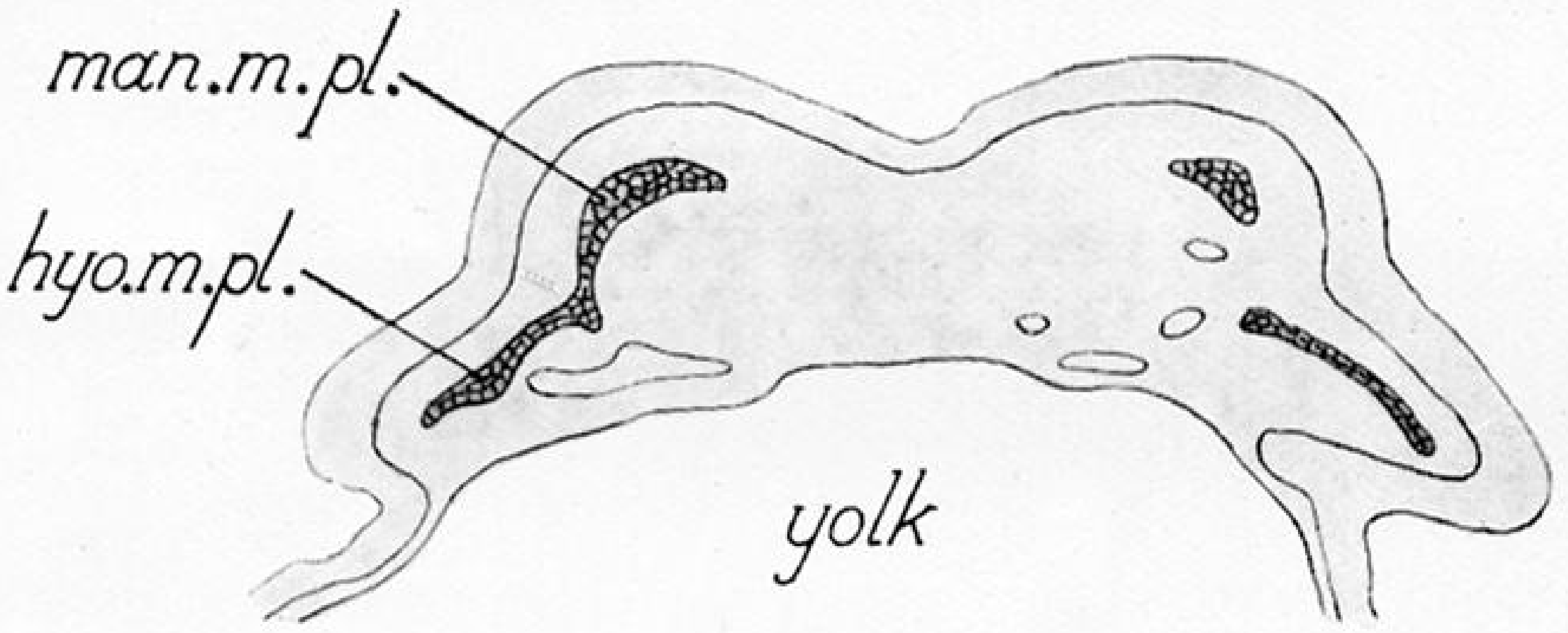

115

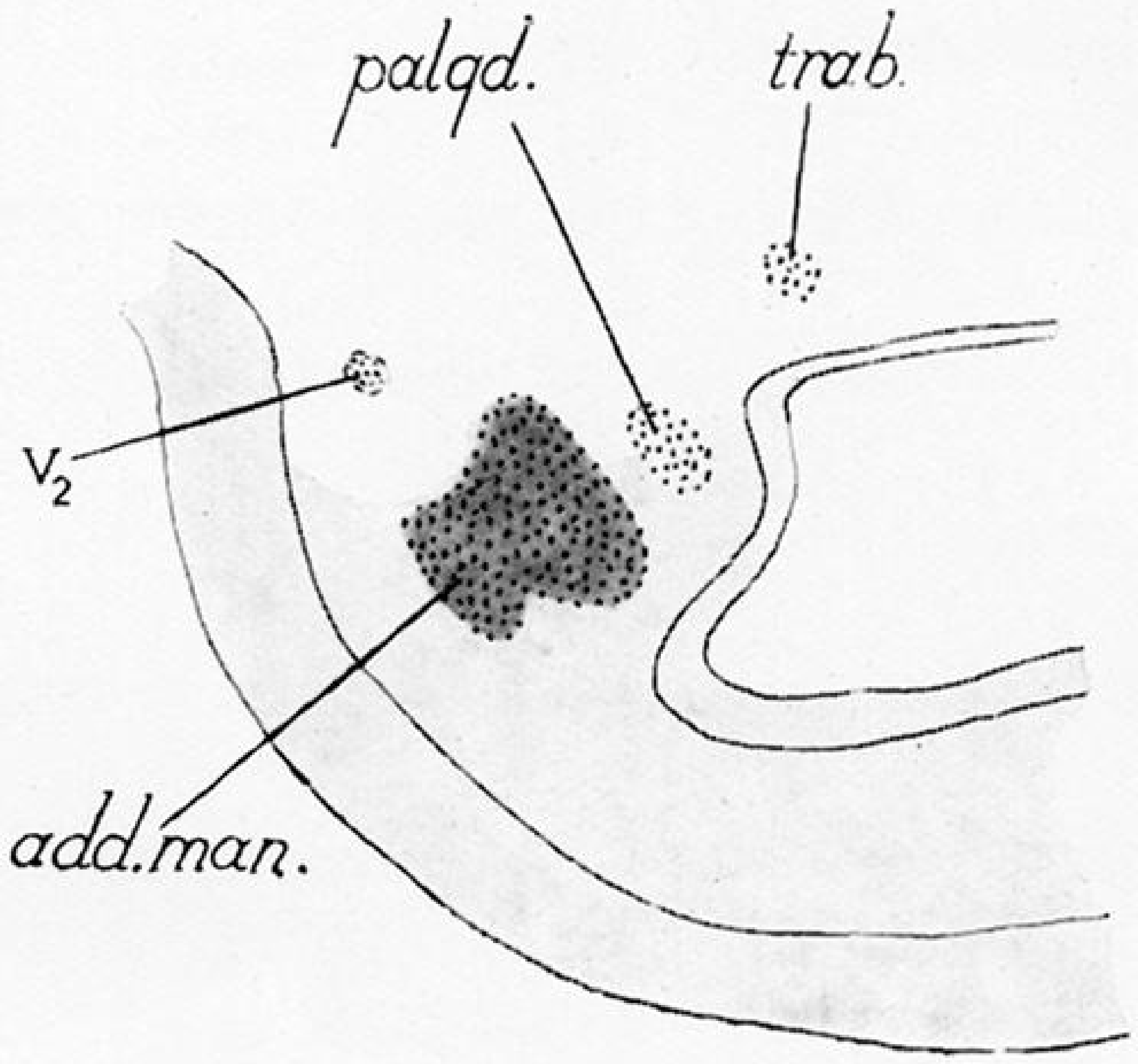

116

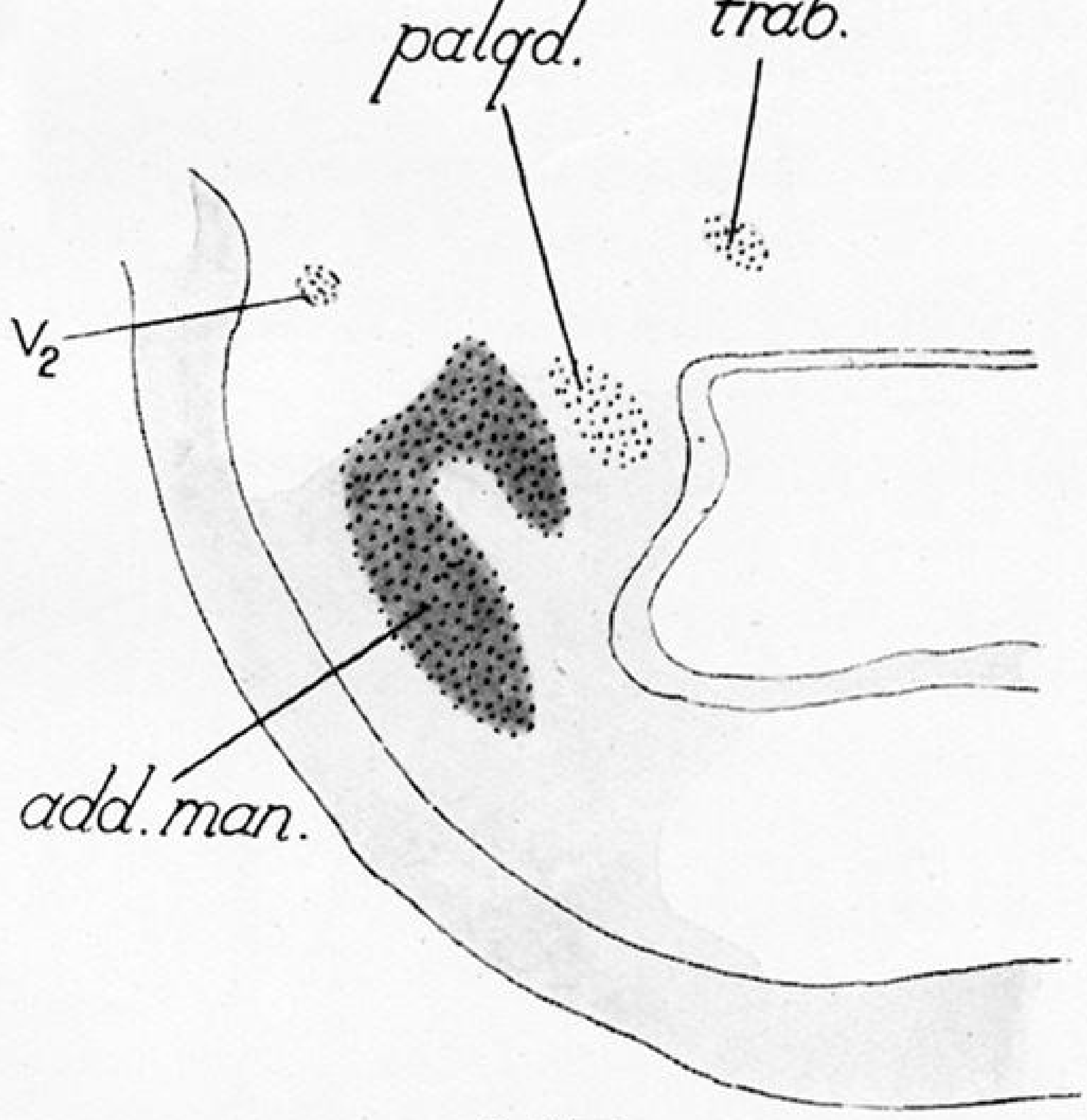

117

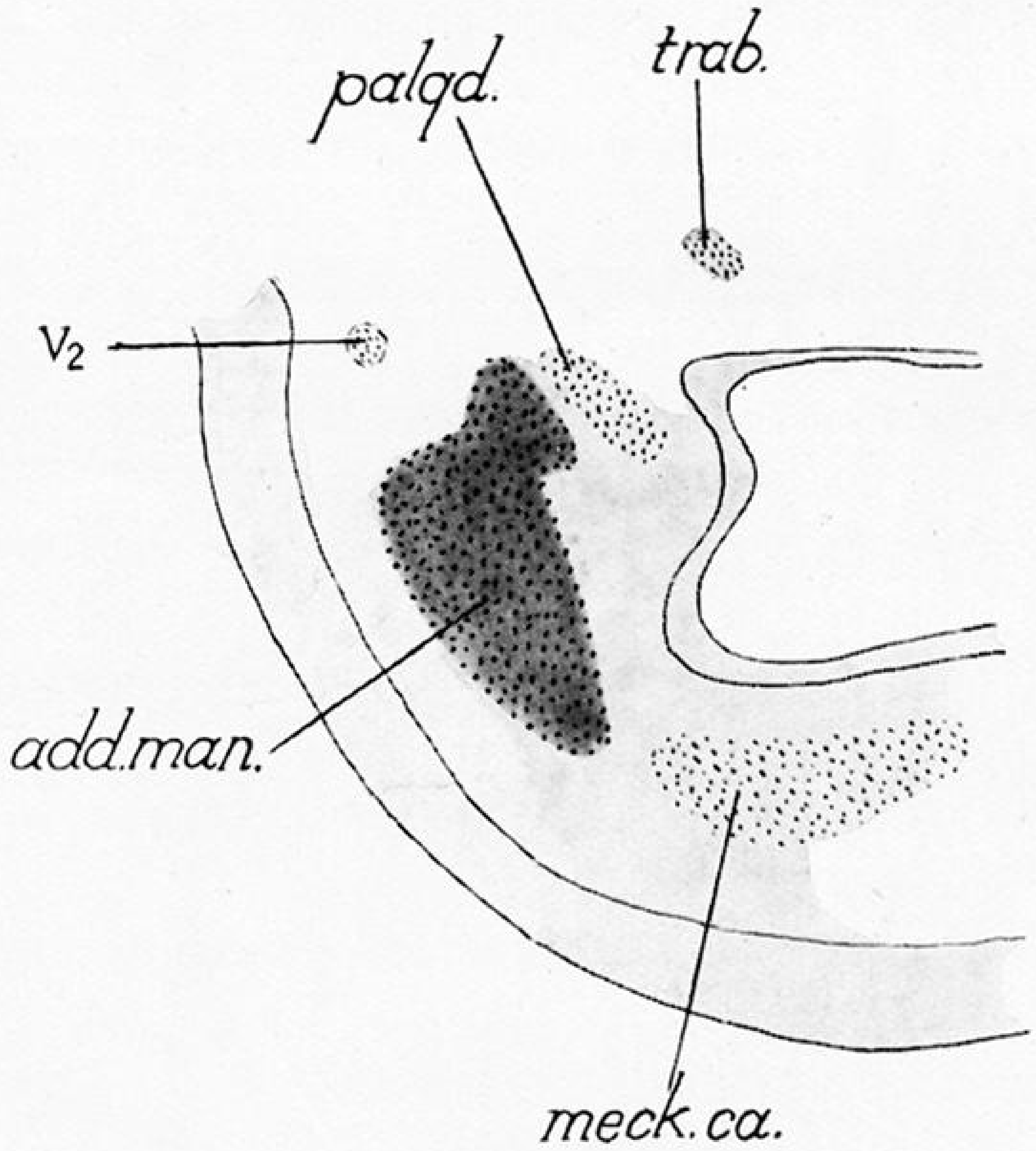

118

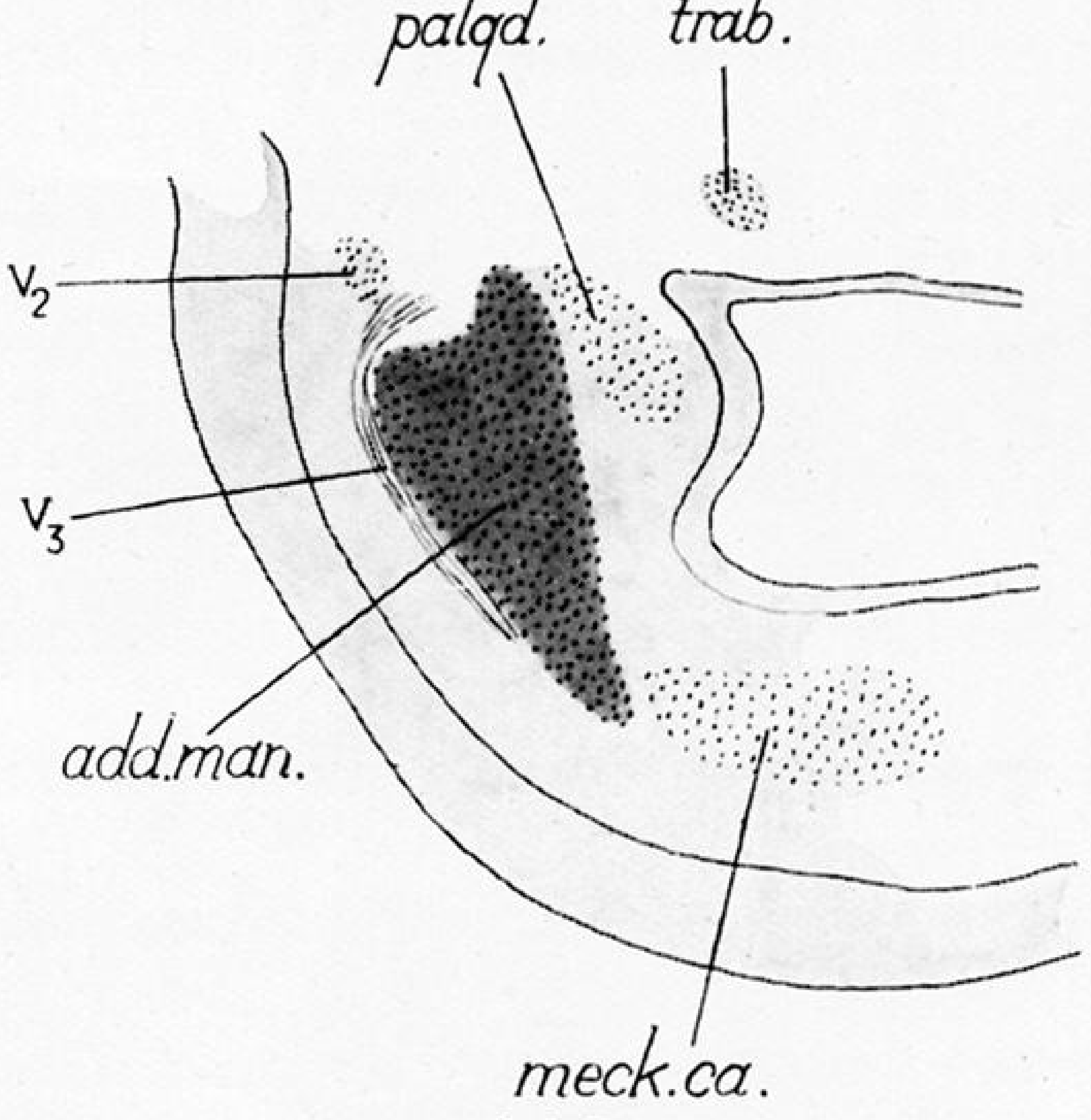

119

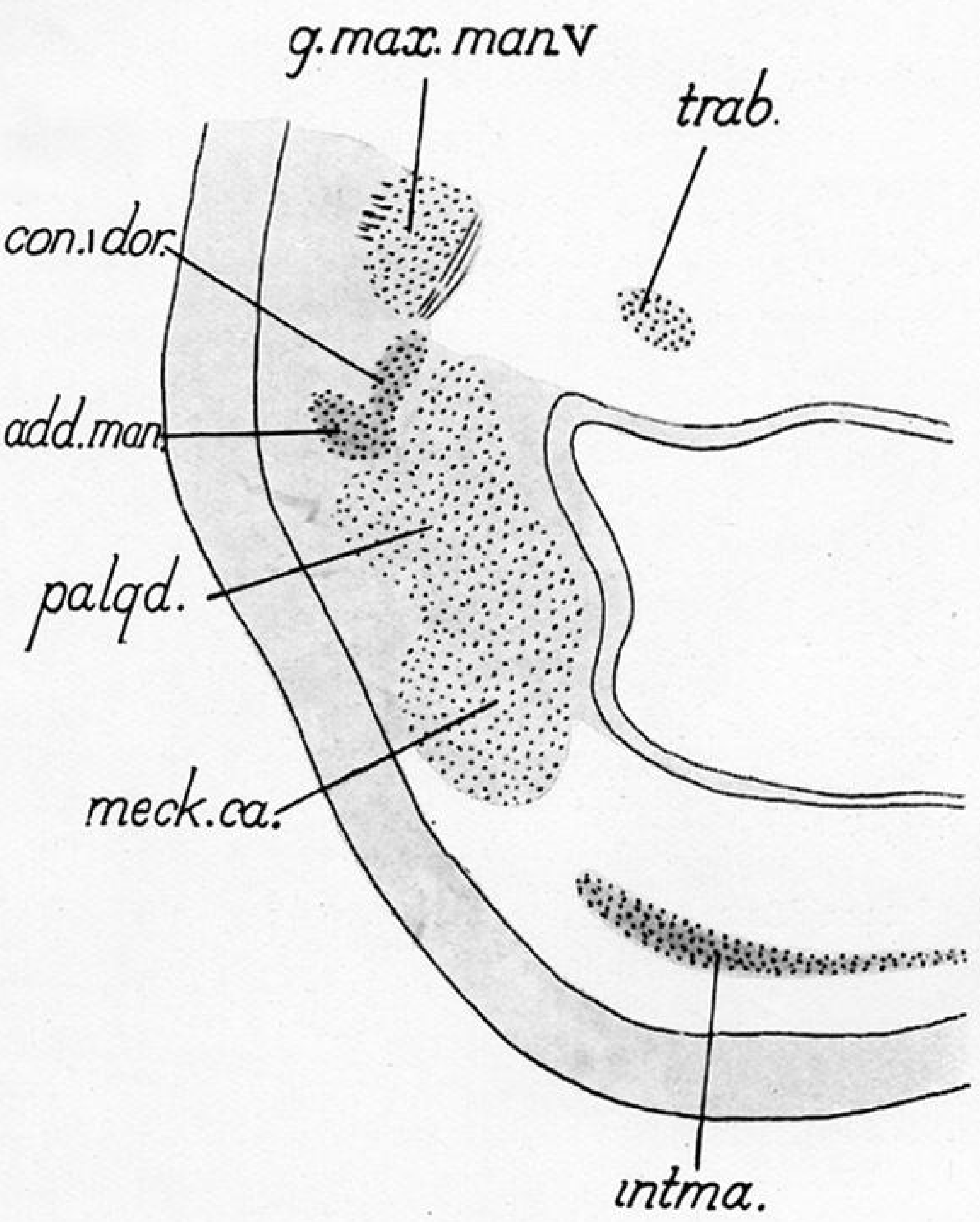

120

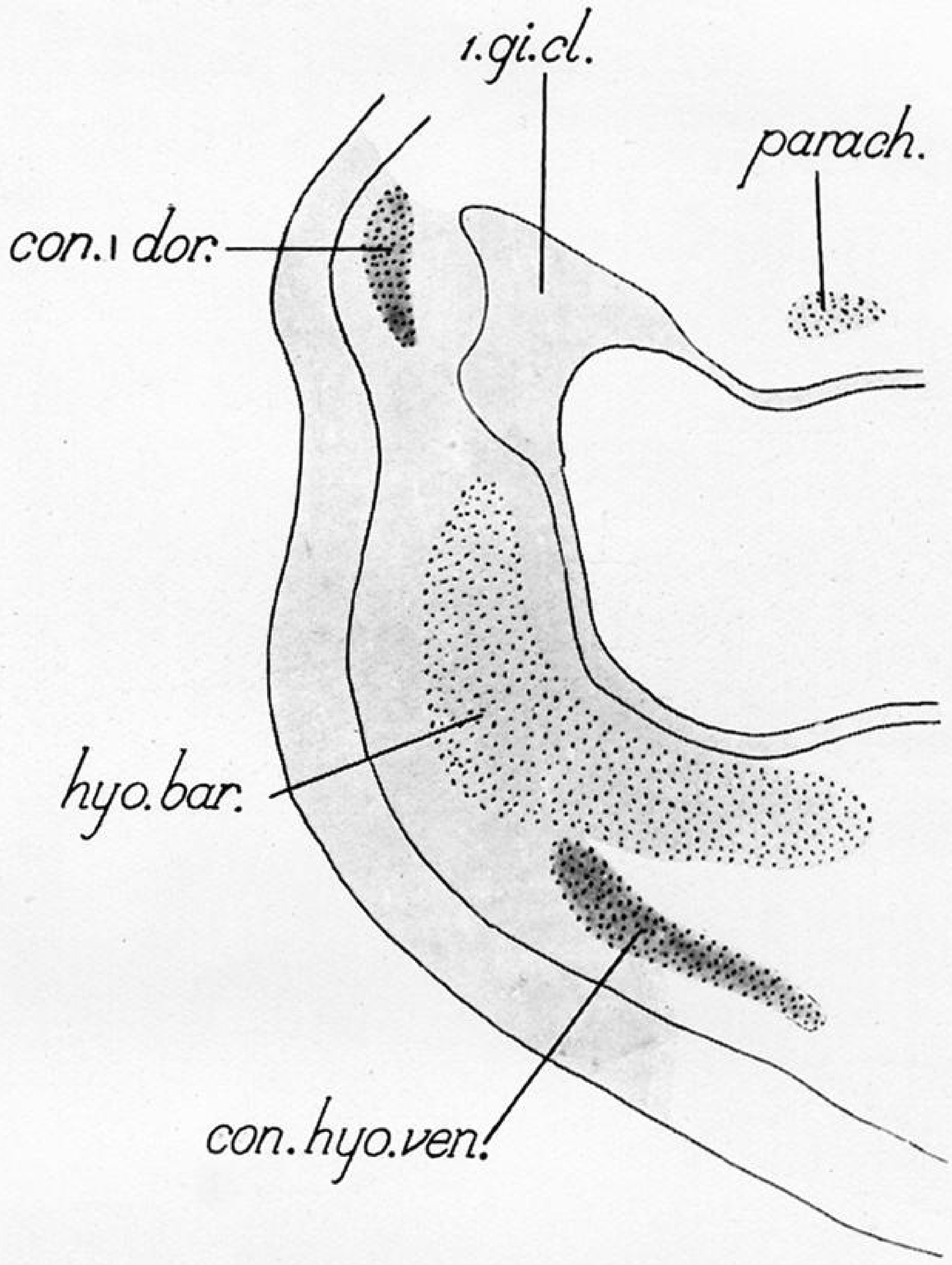

121

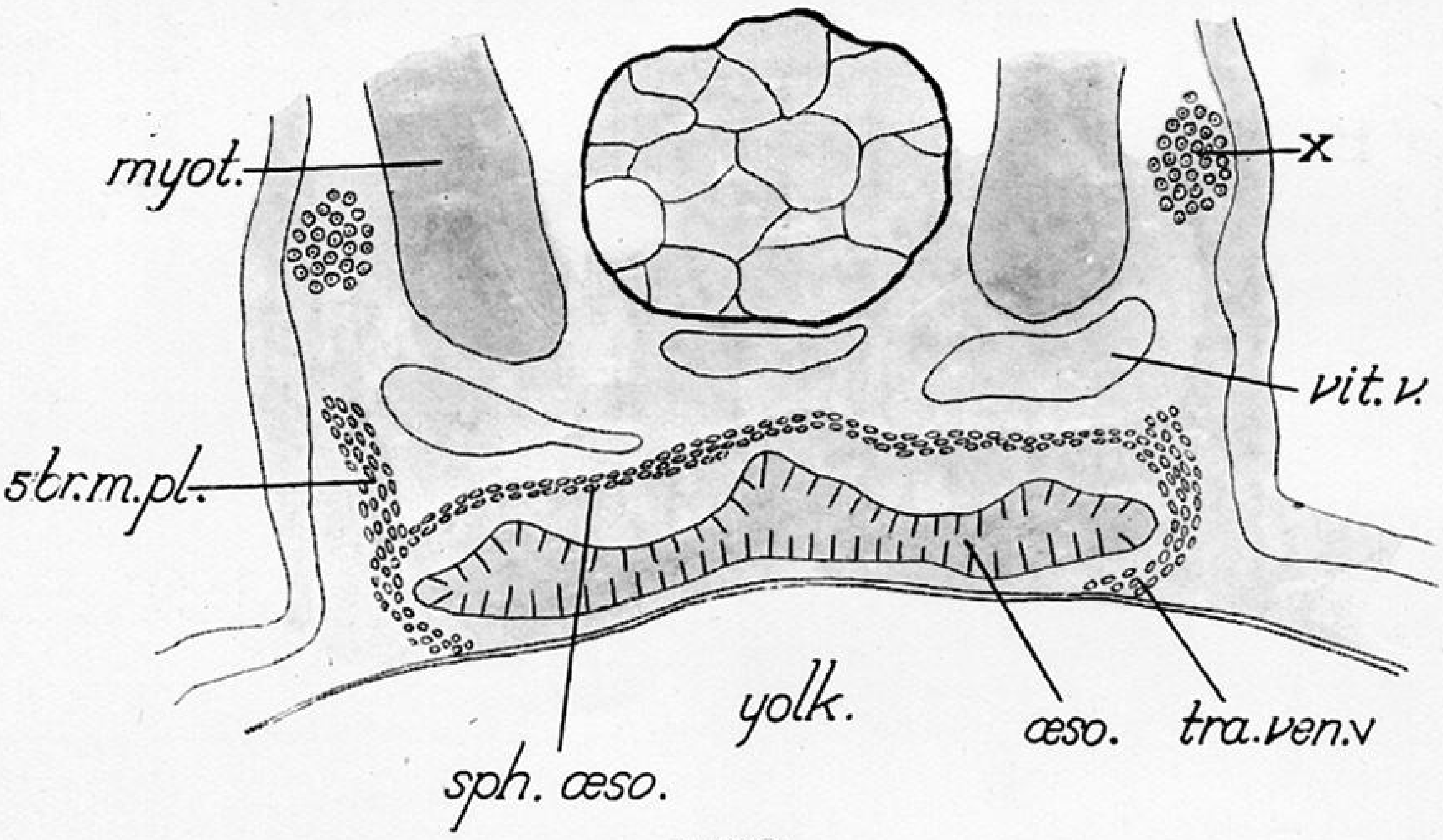

122

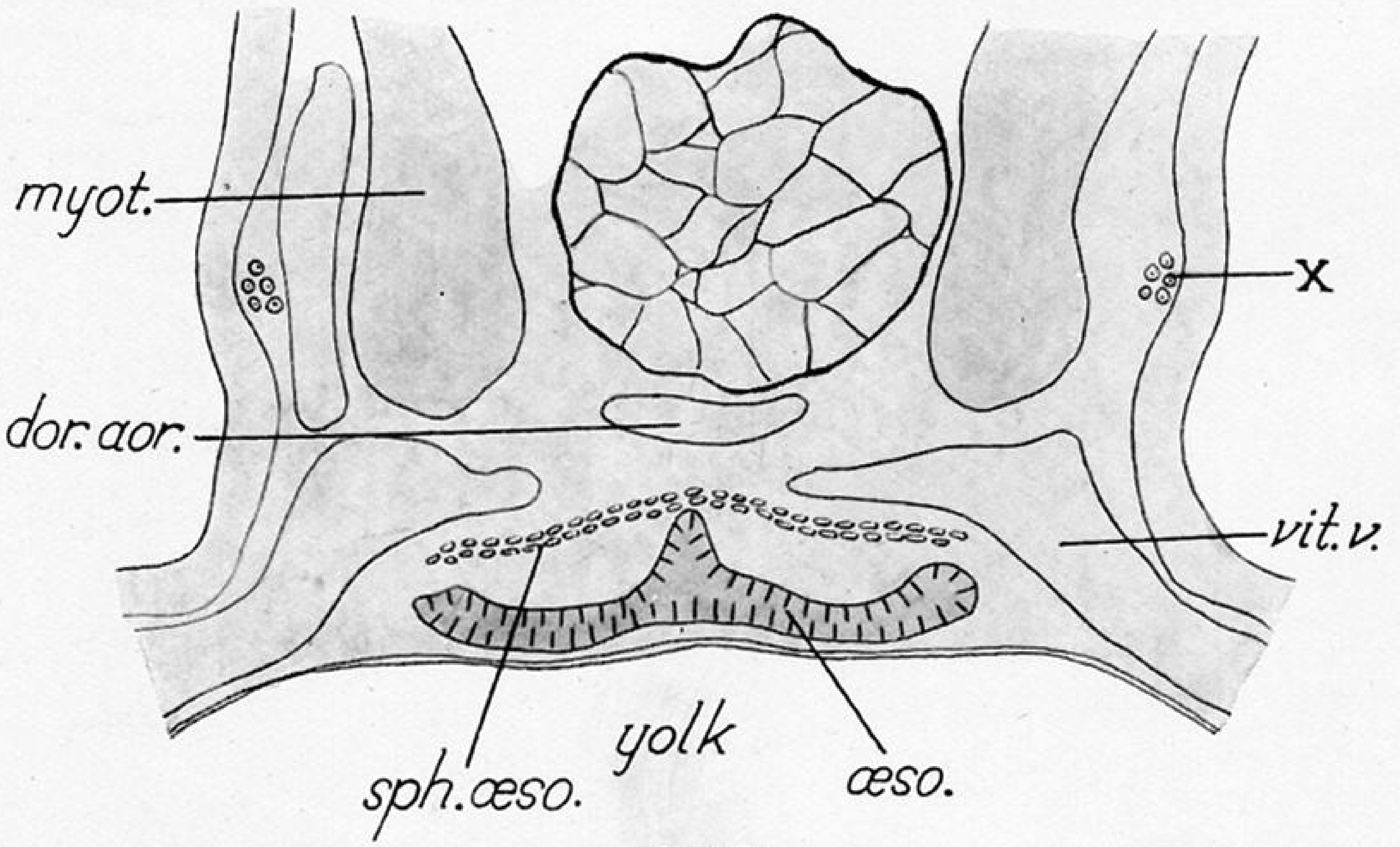

123

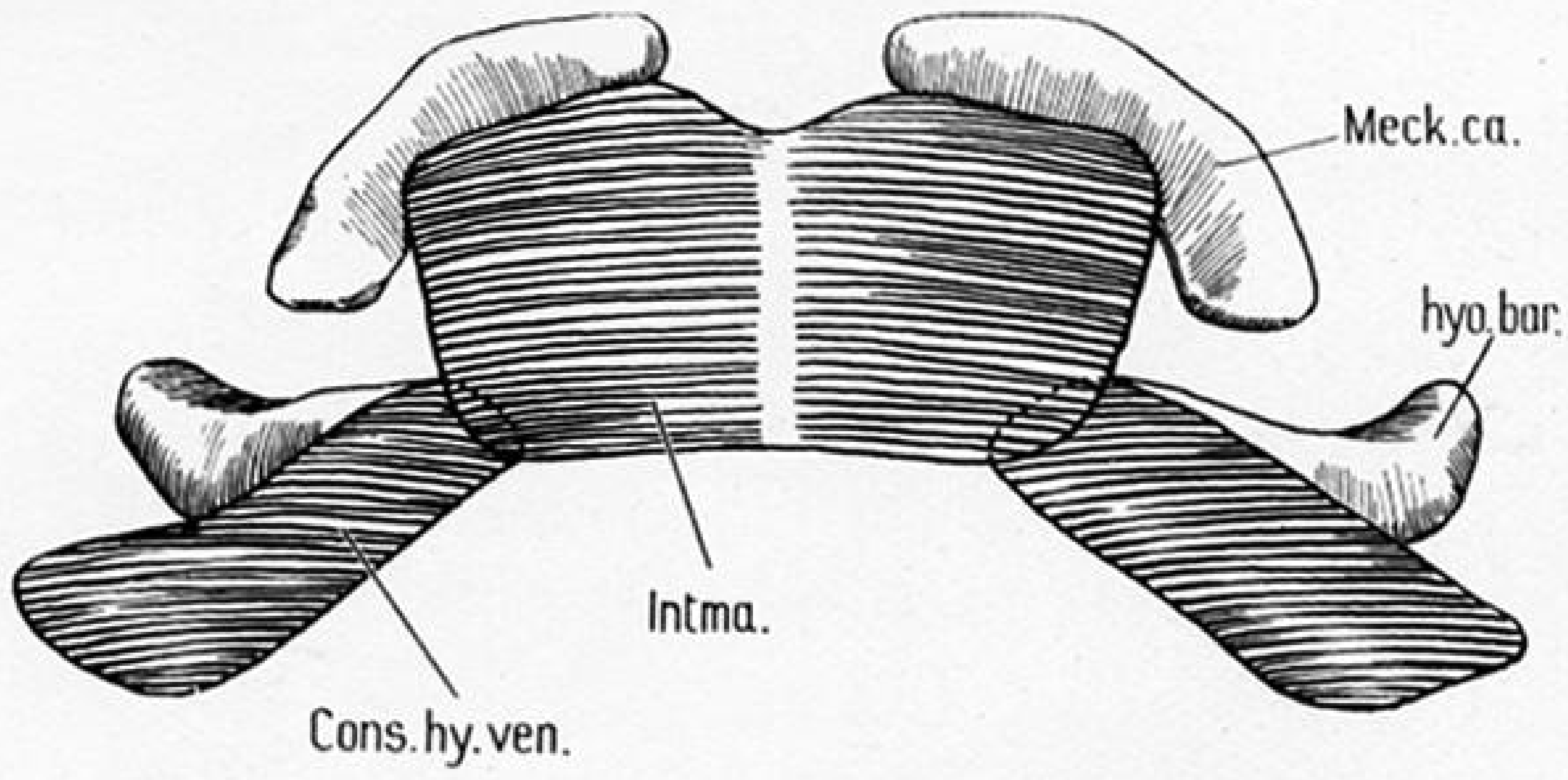

124

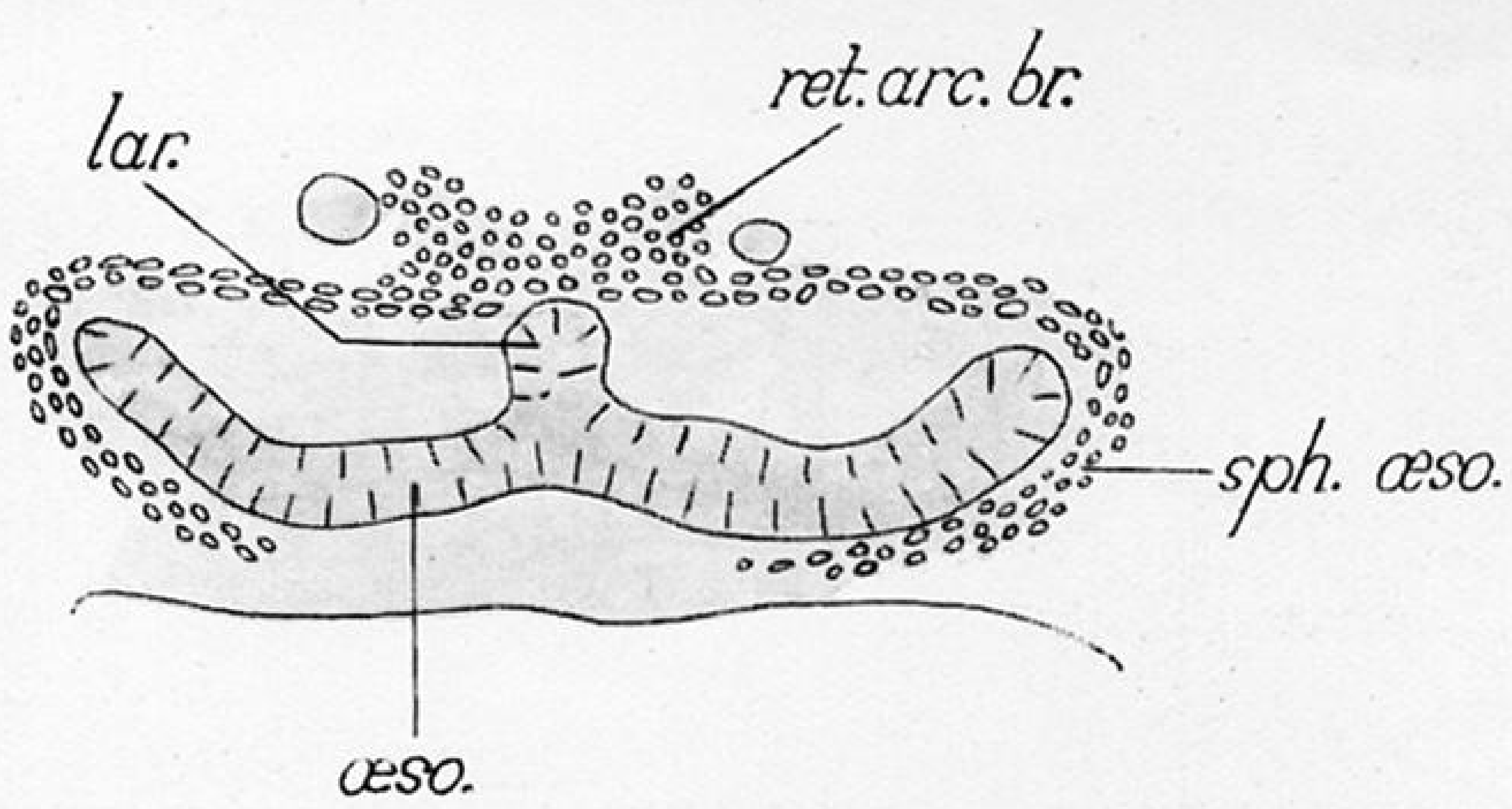

125

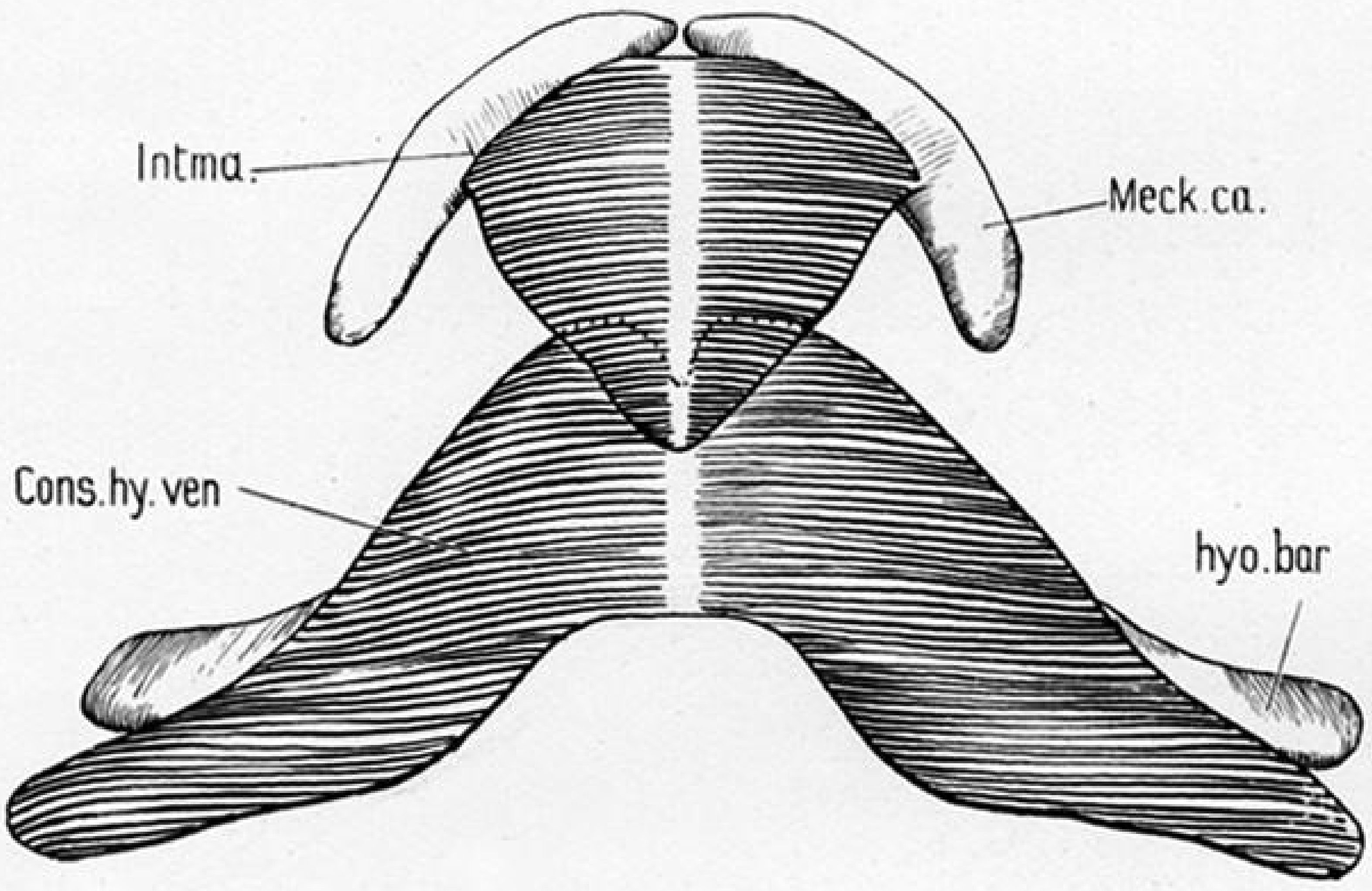

126

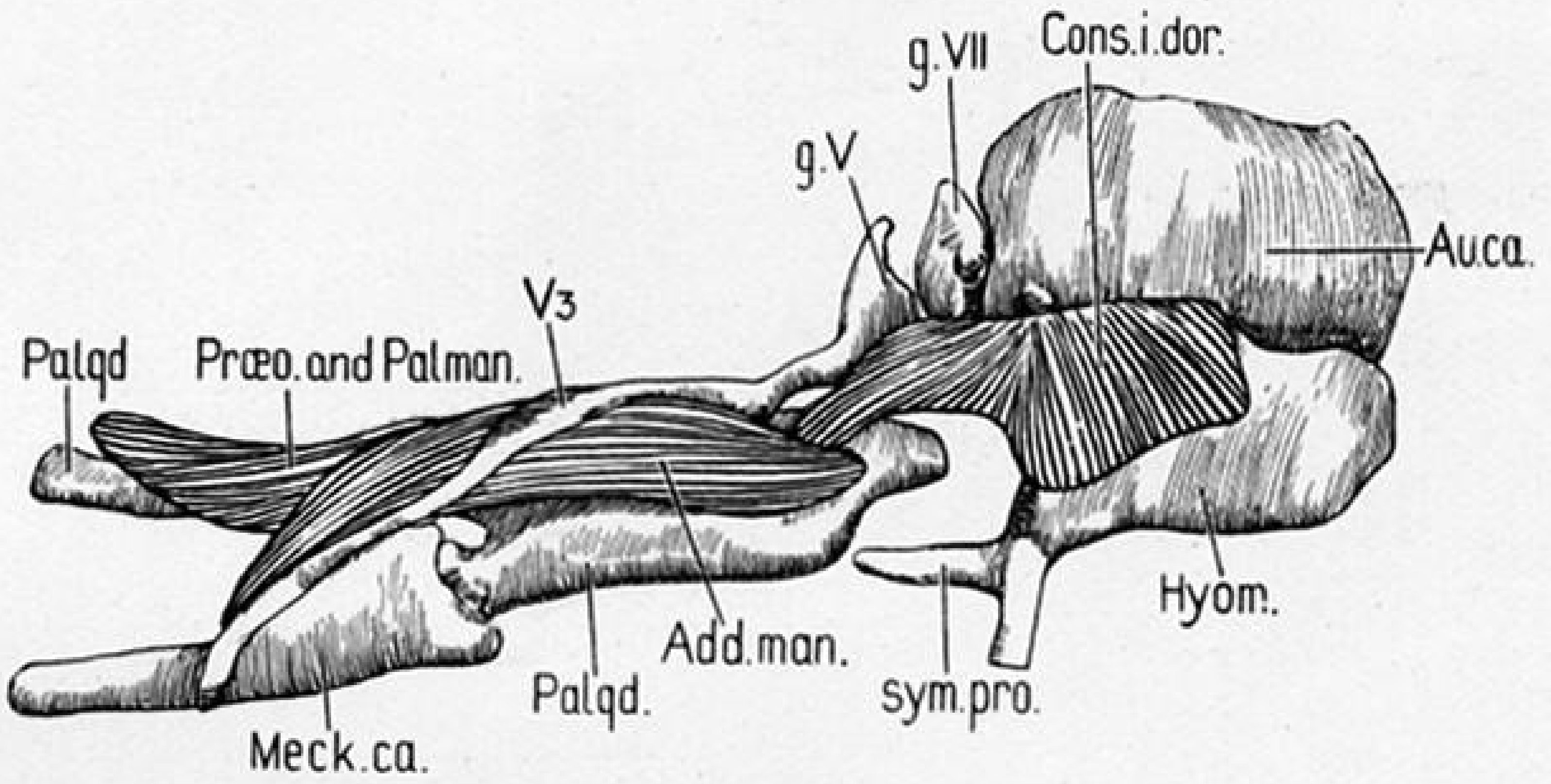

127

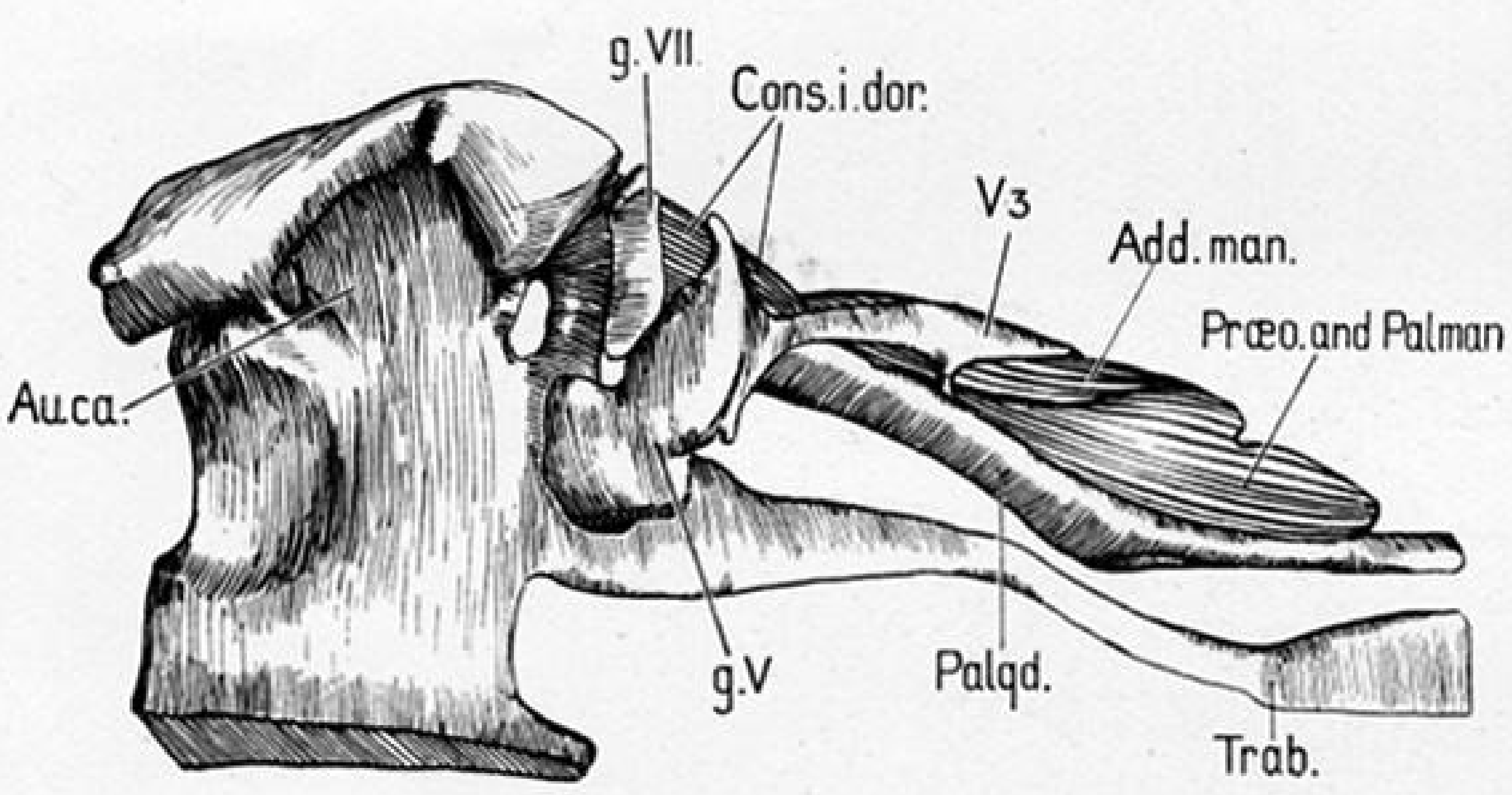

128

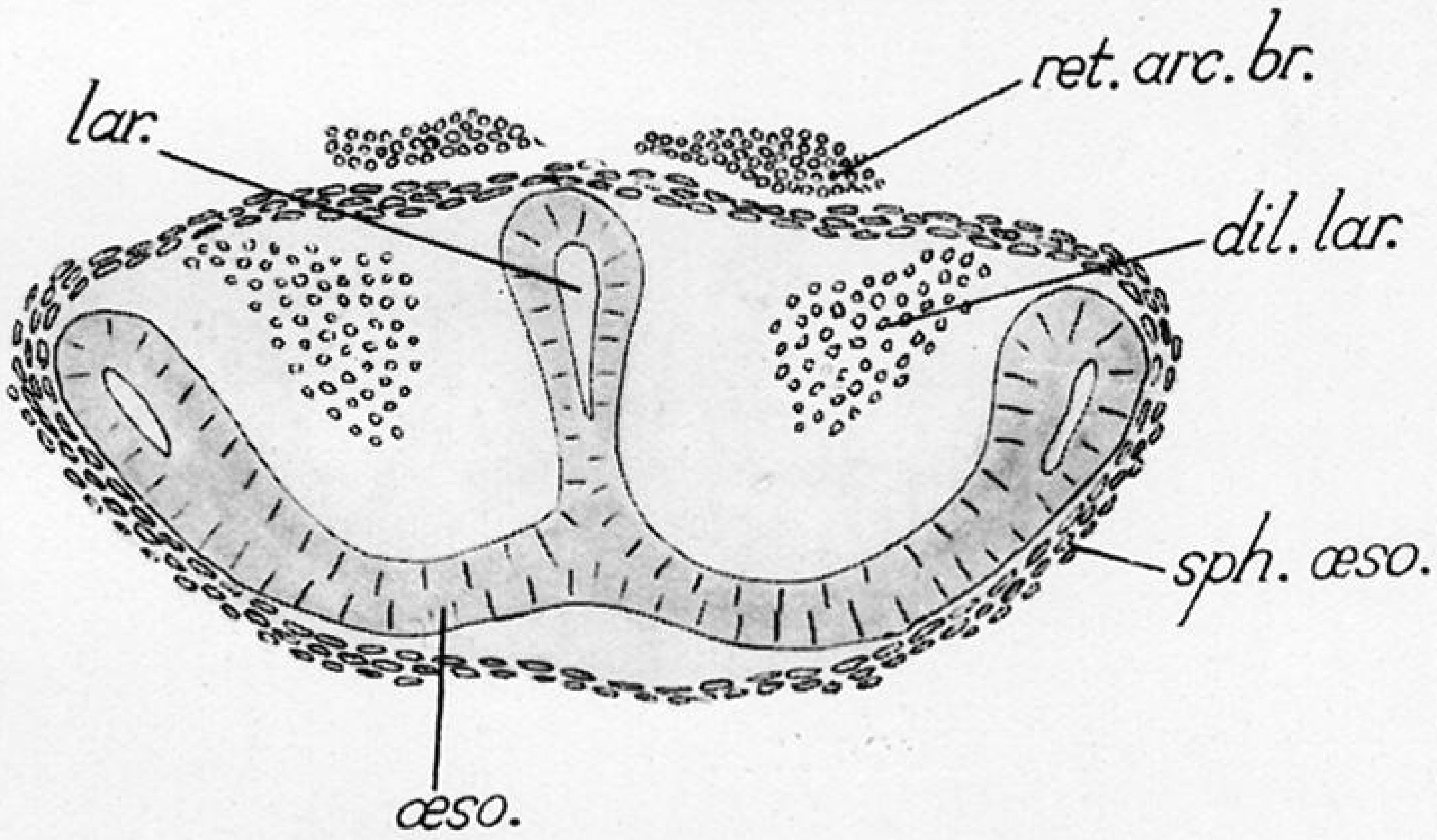

129

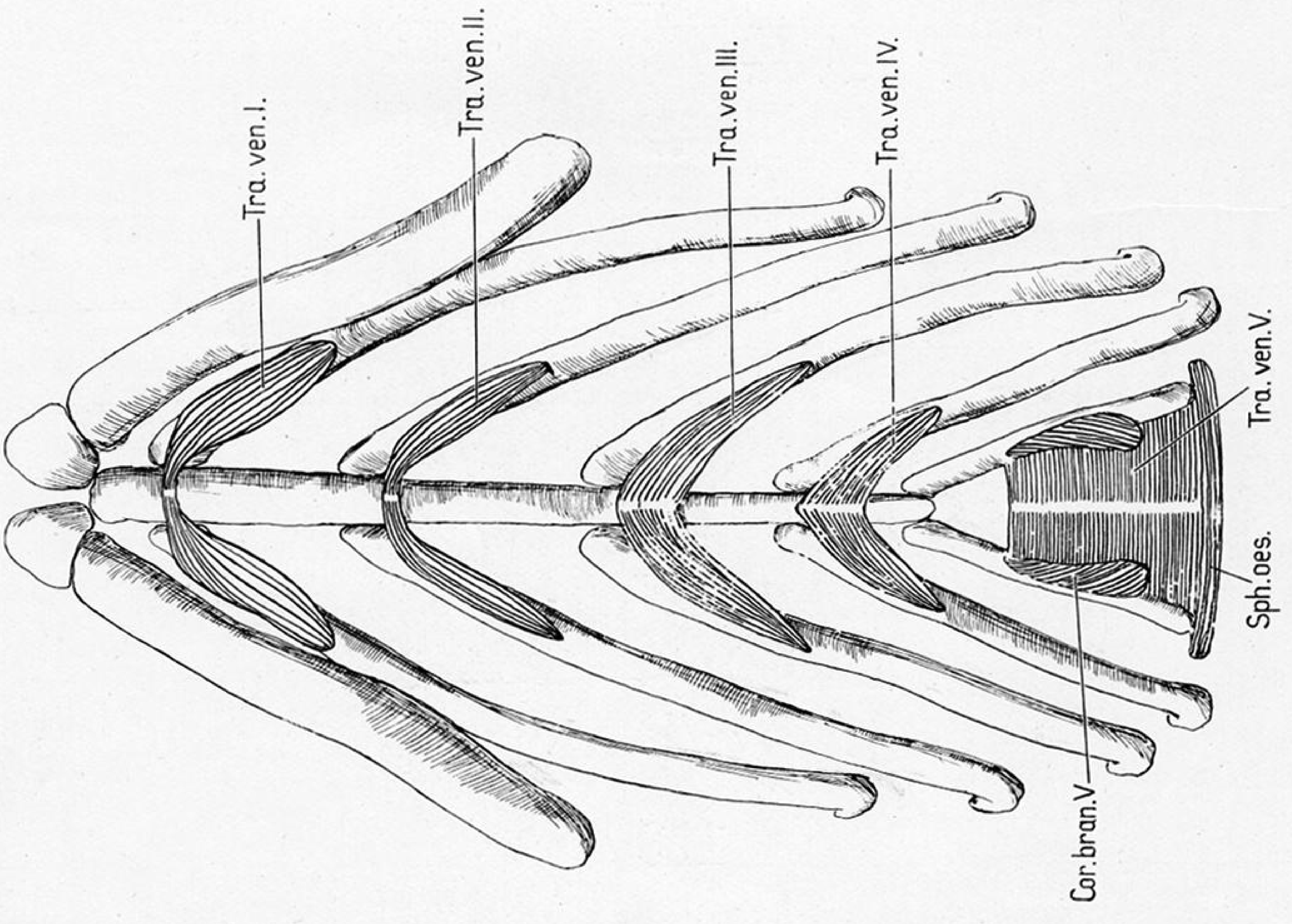

130

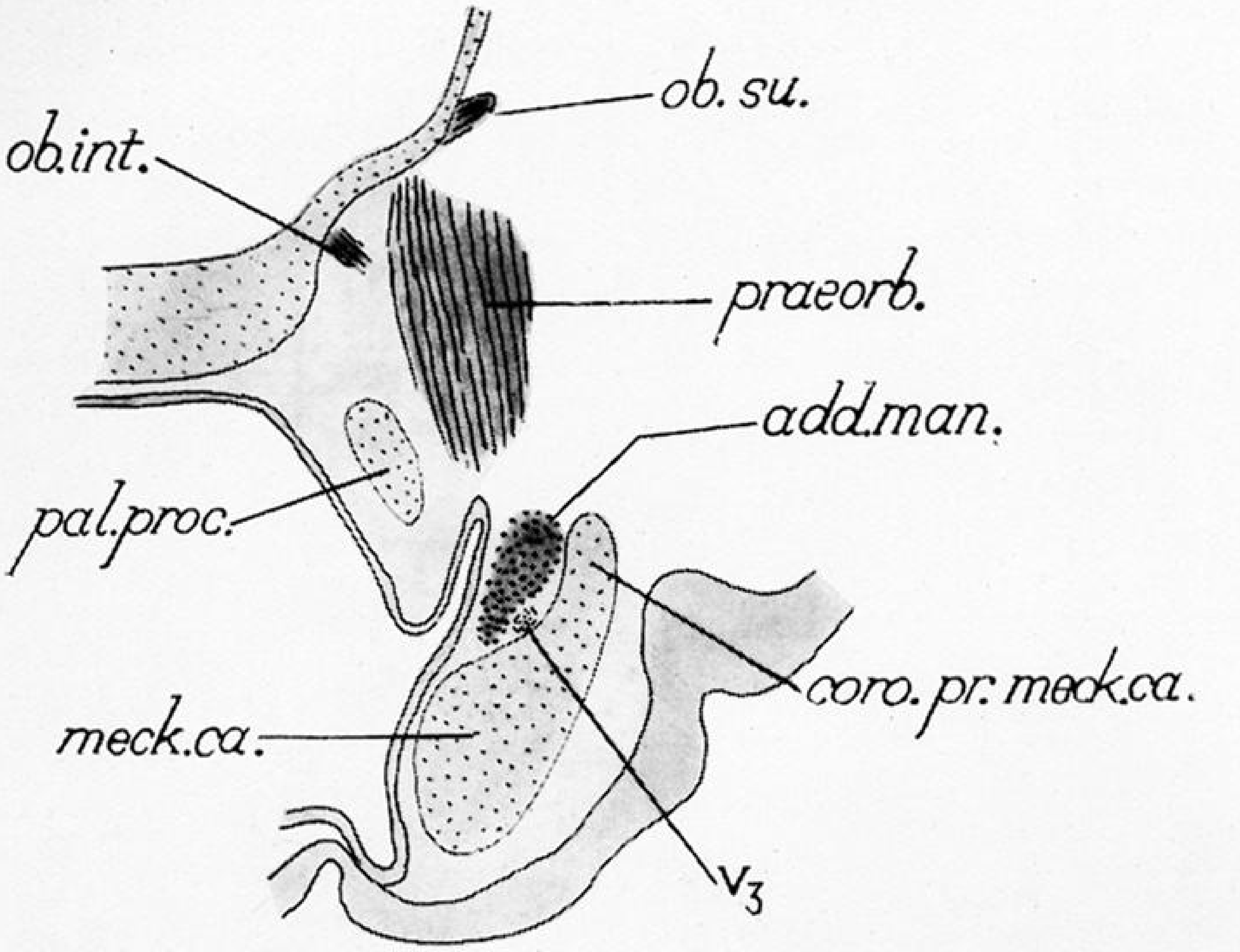

131

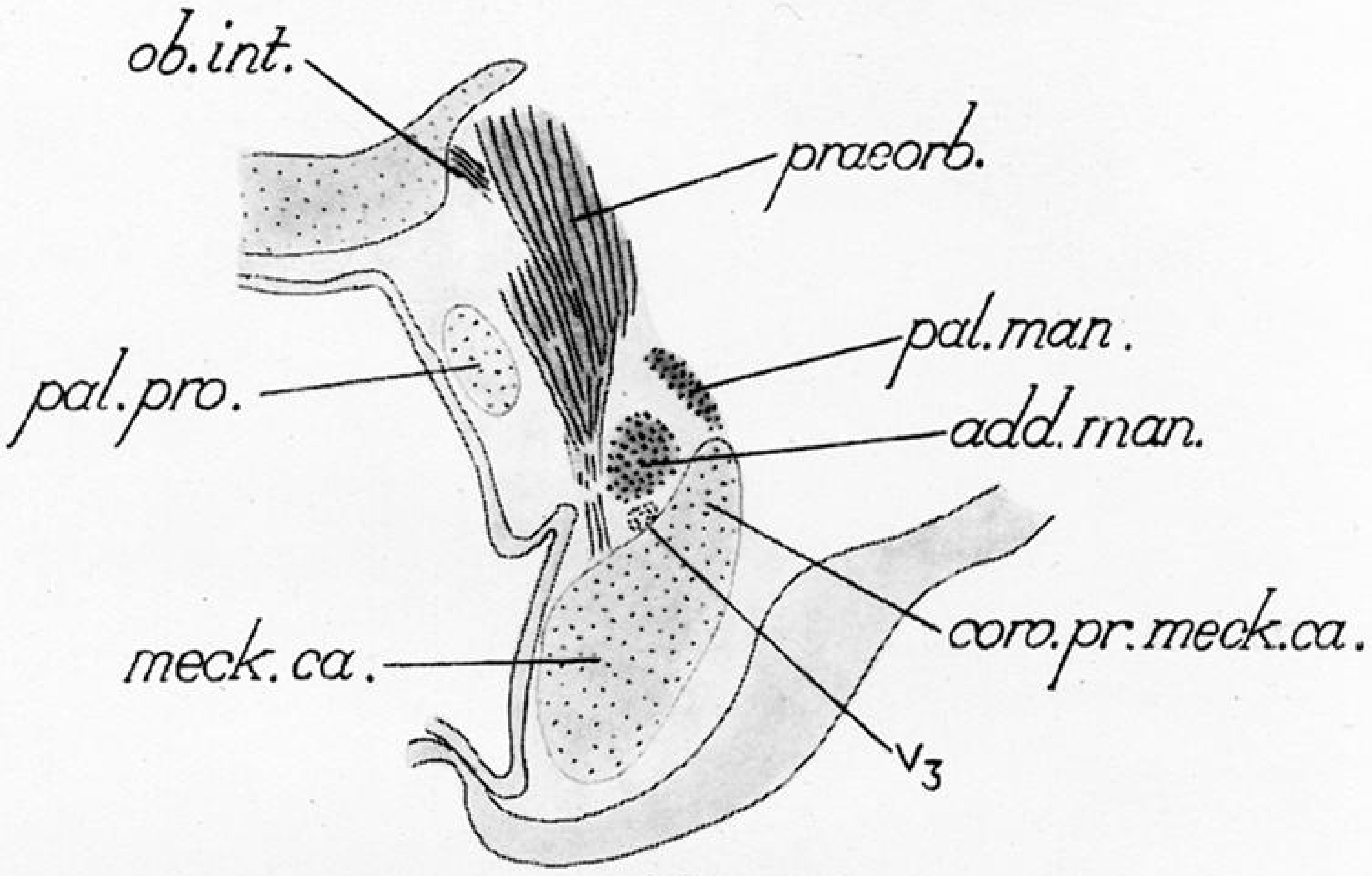

132

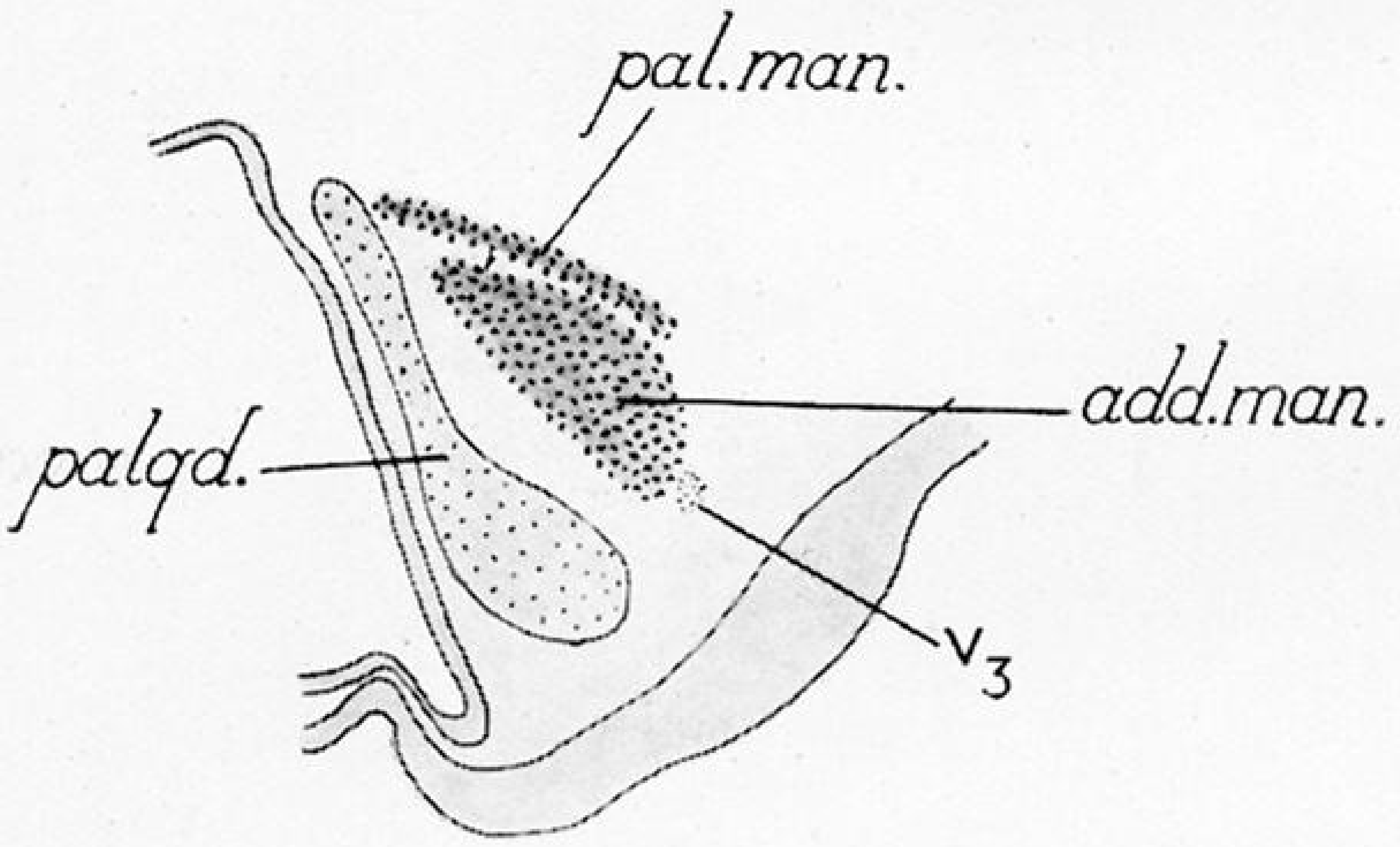

133

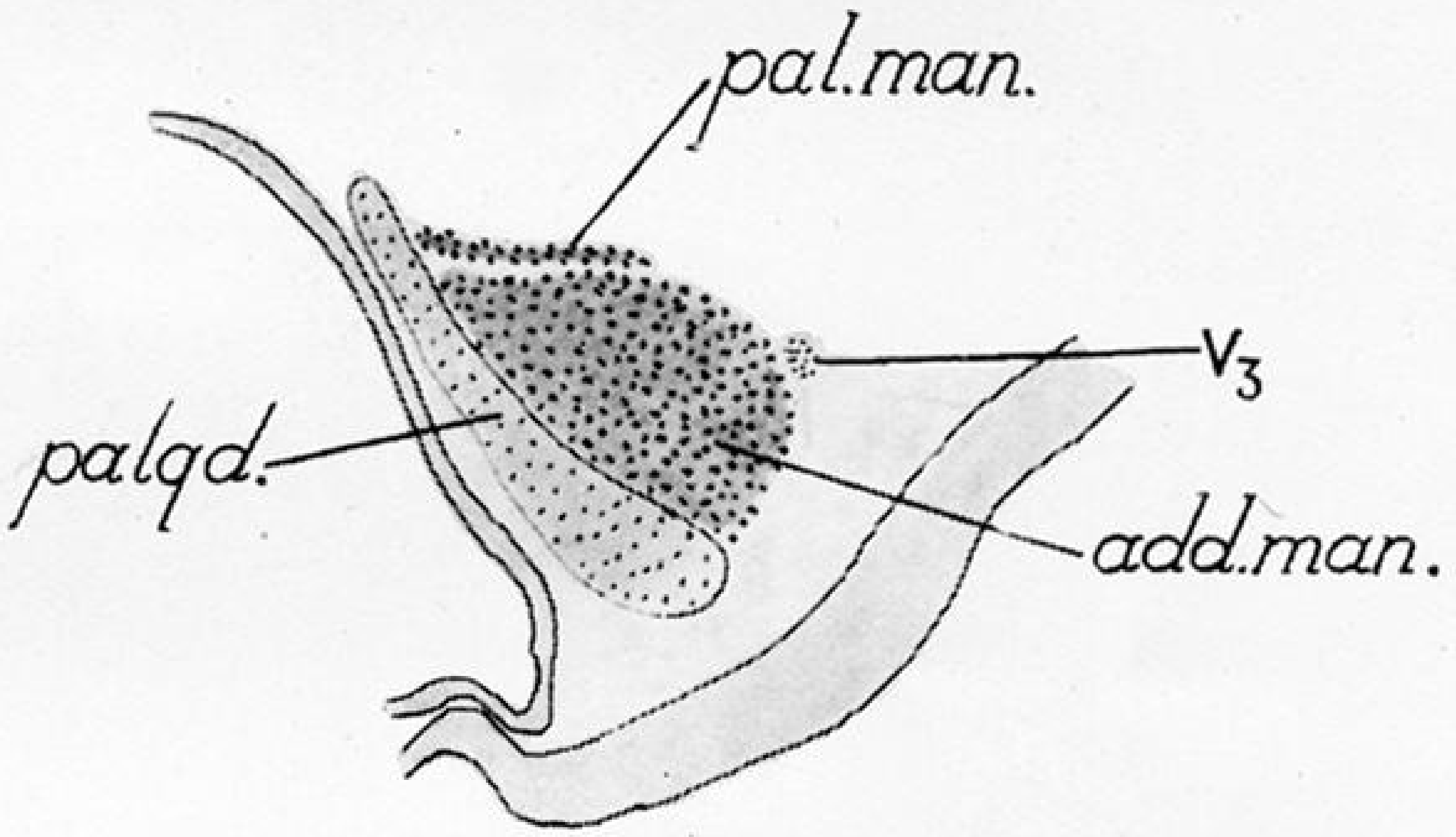

134

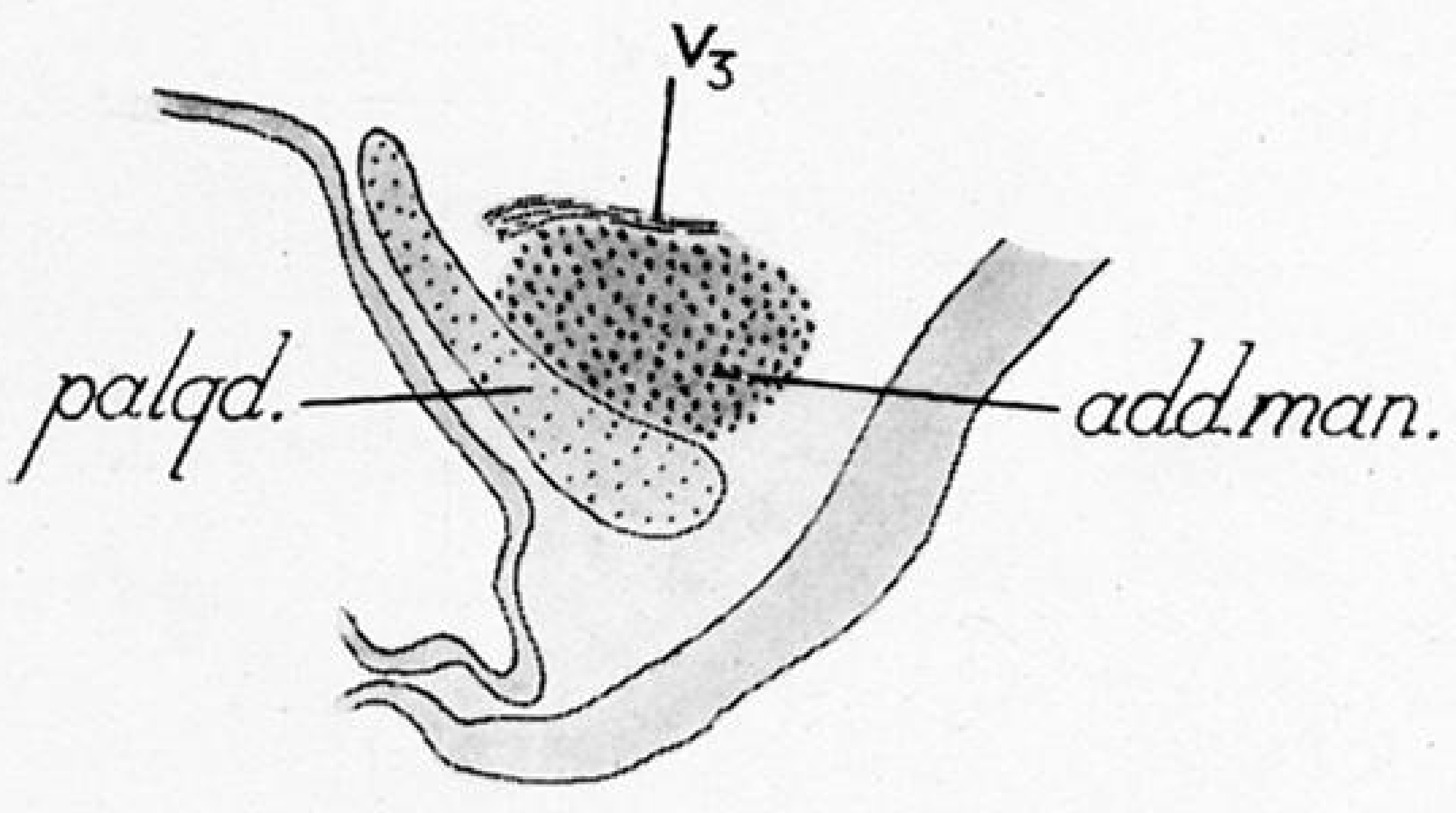

135

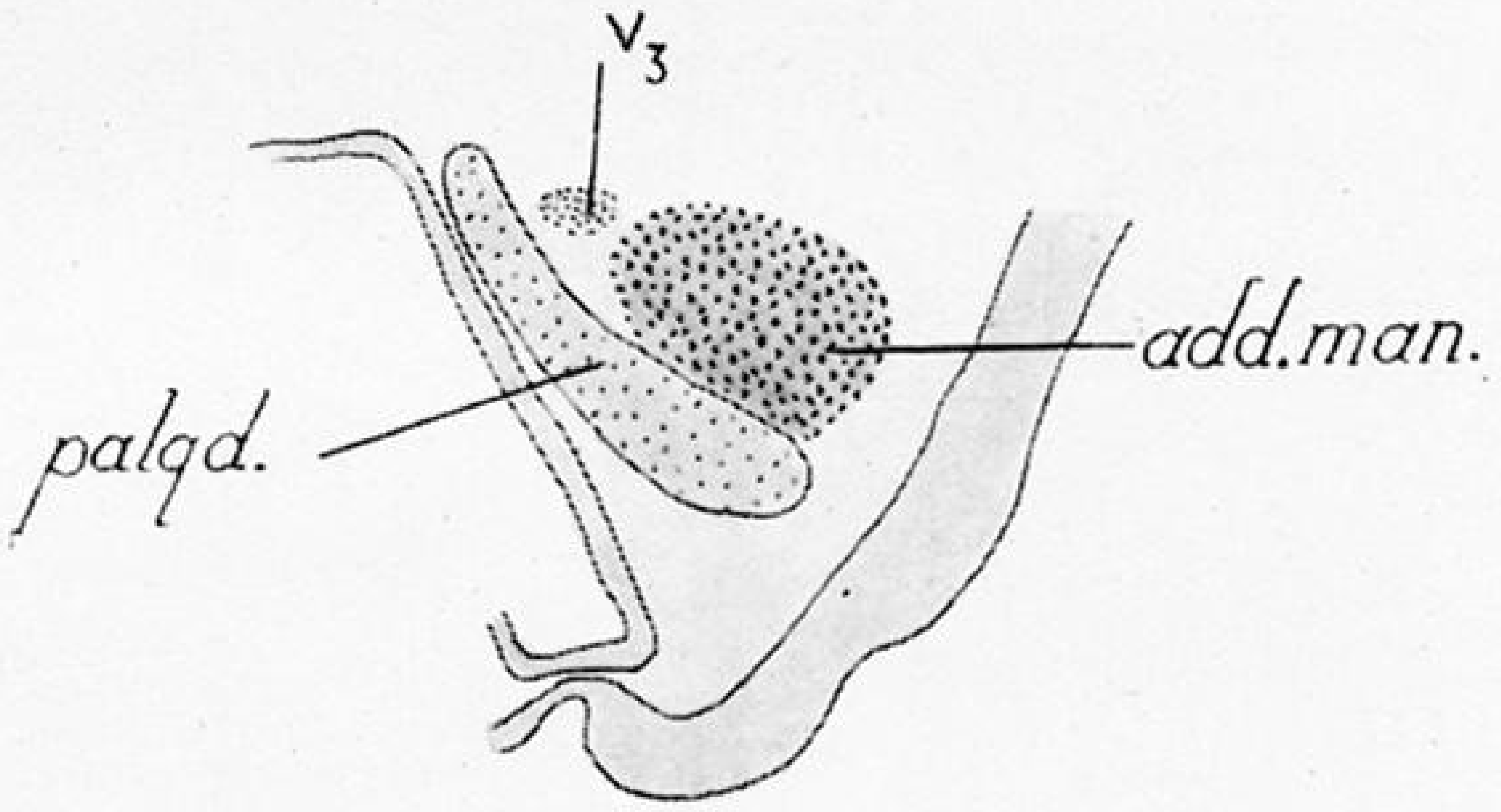

136

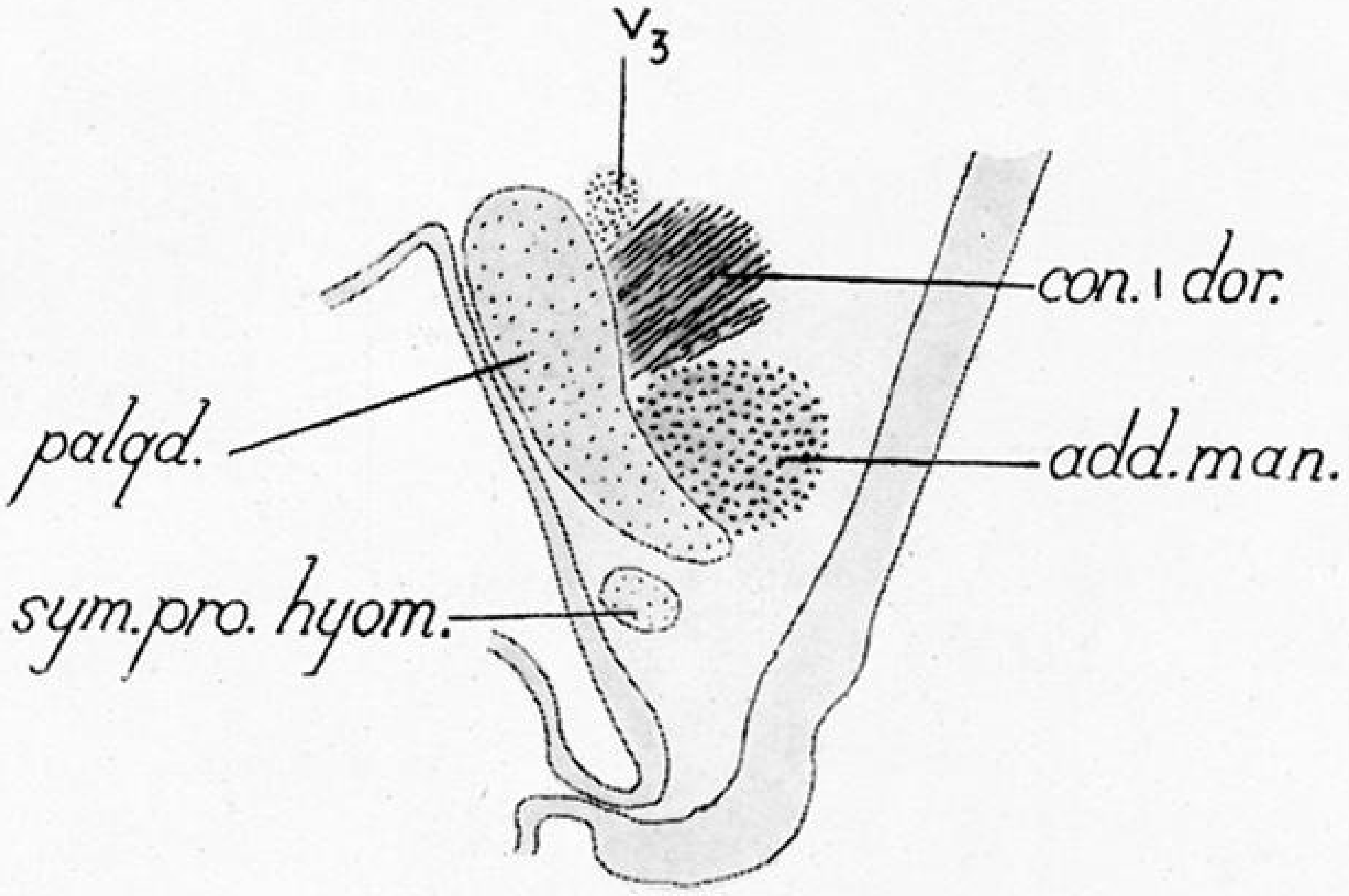

137

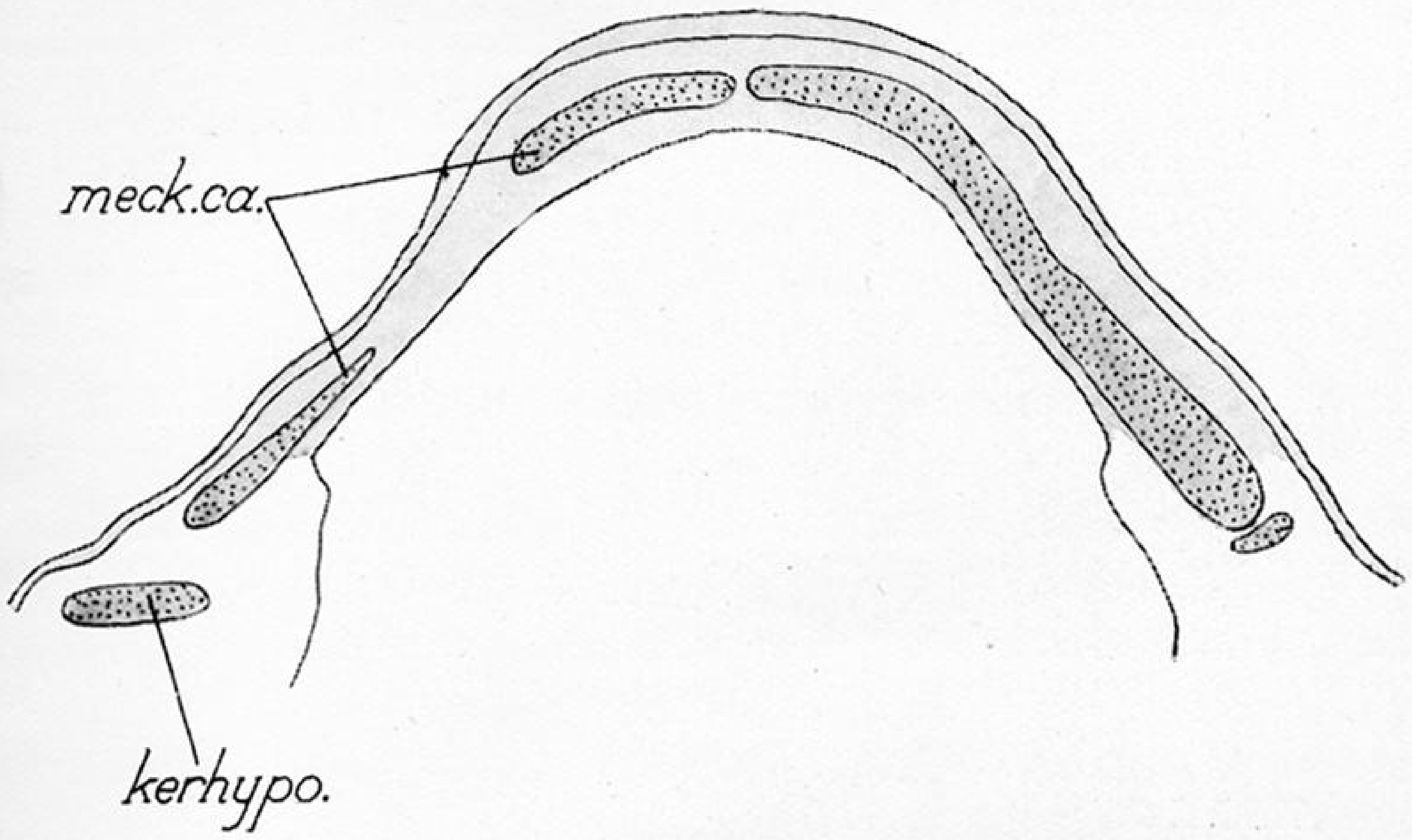

138

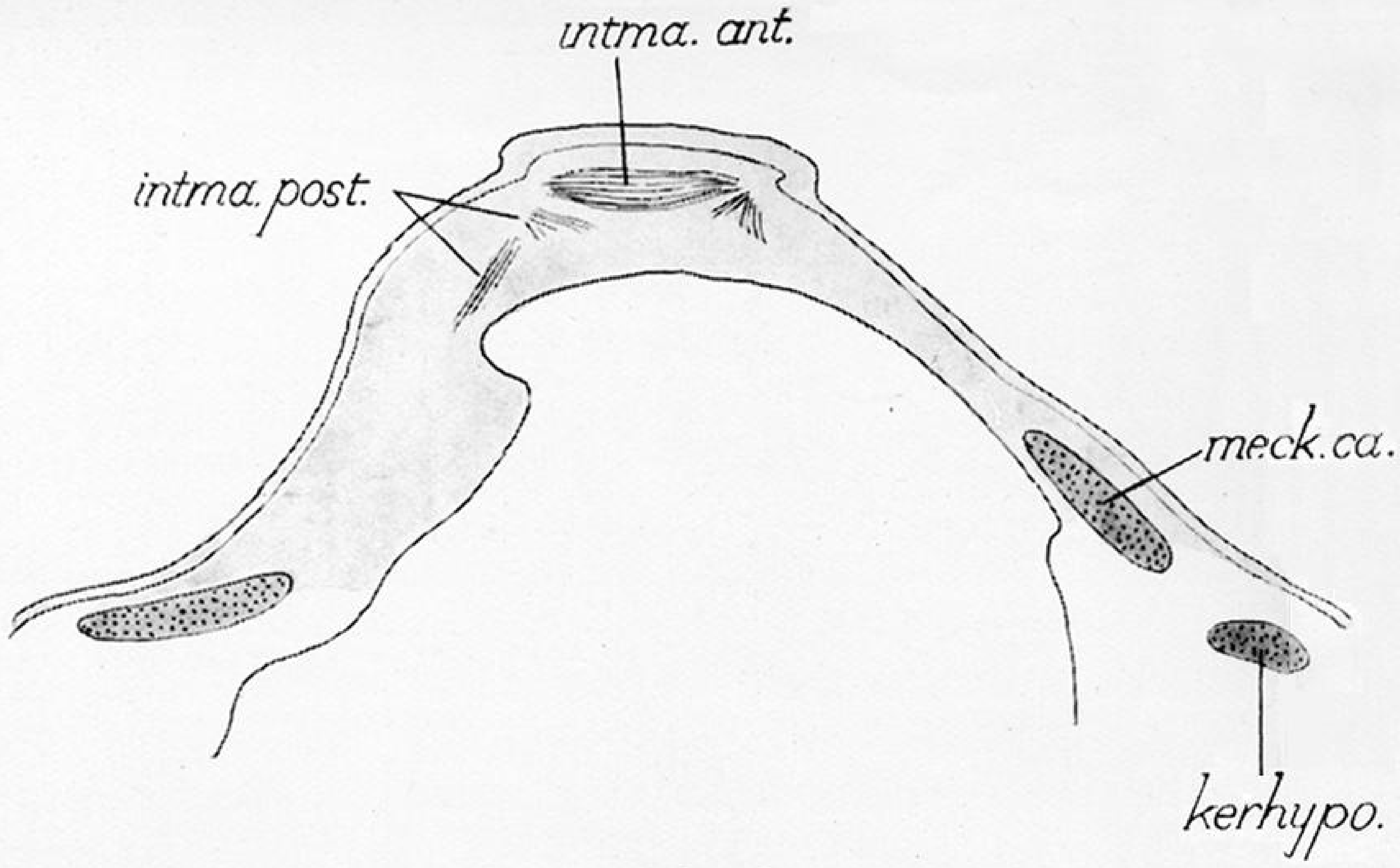

139

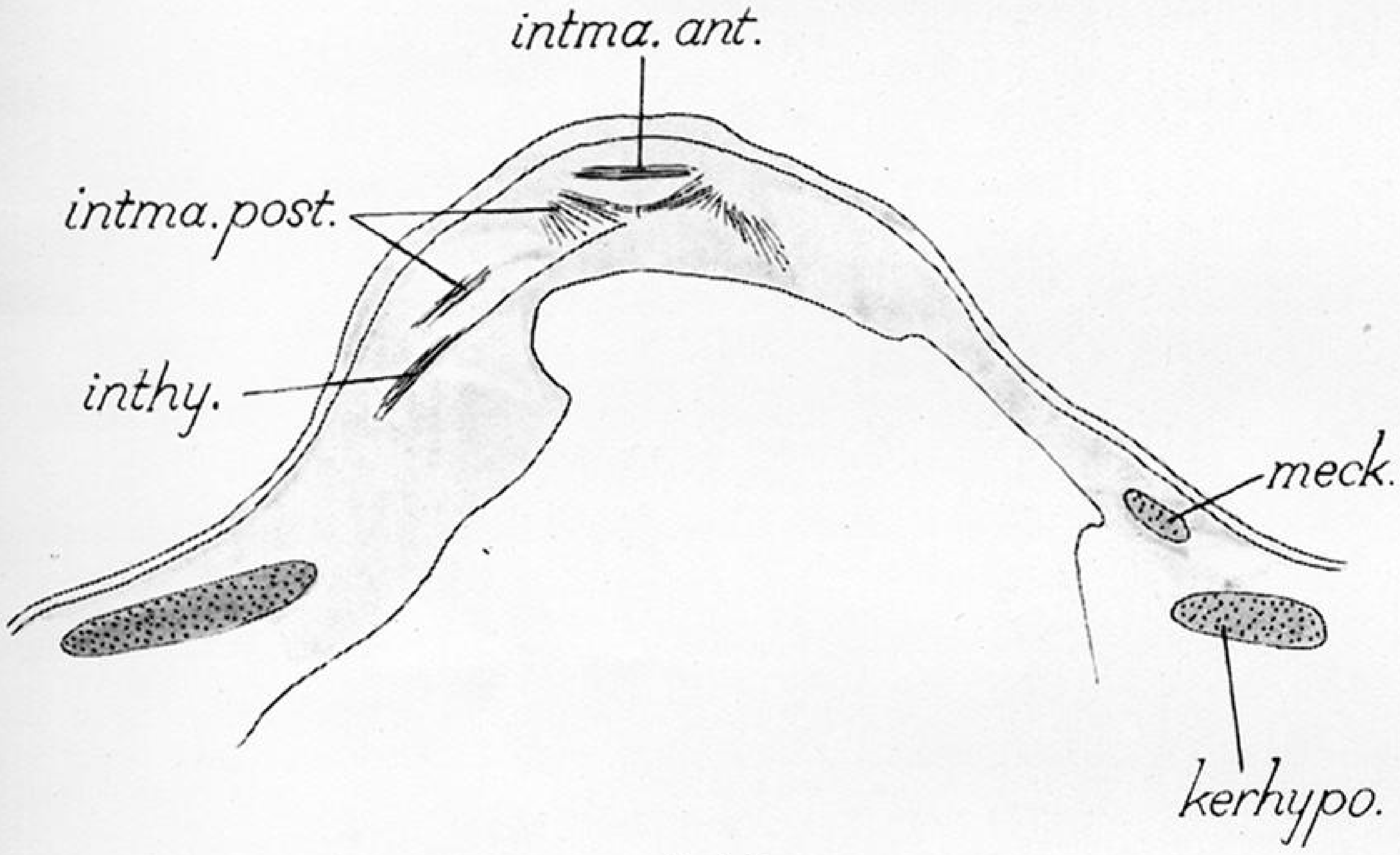

140

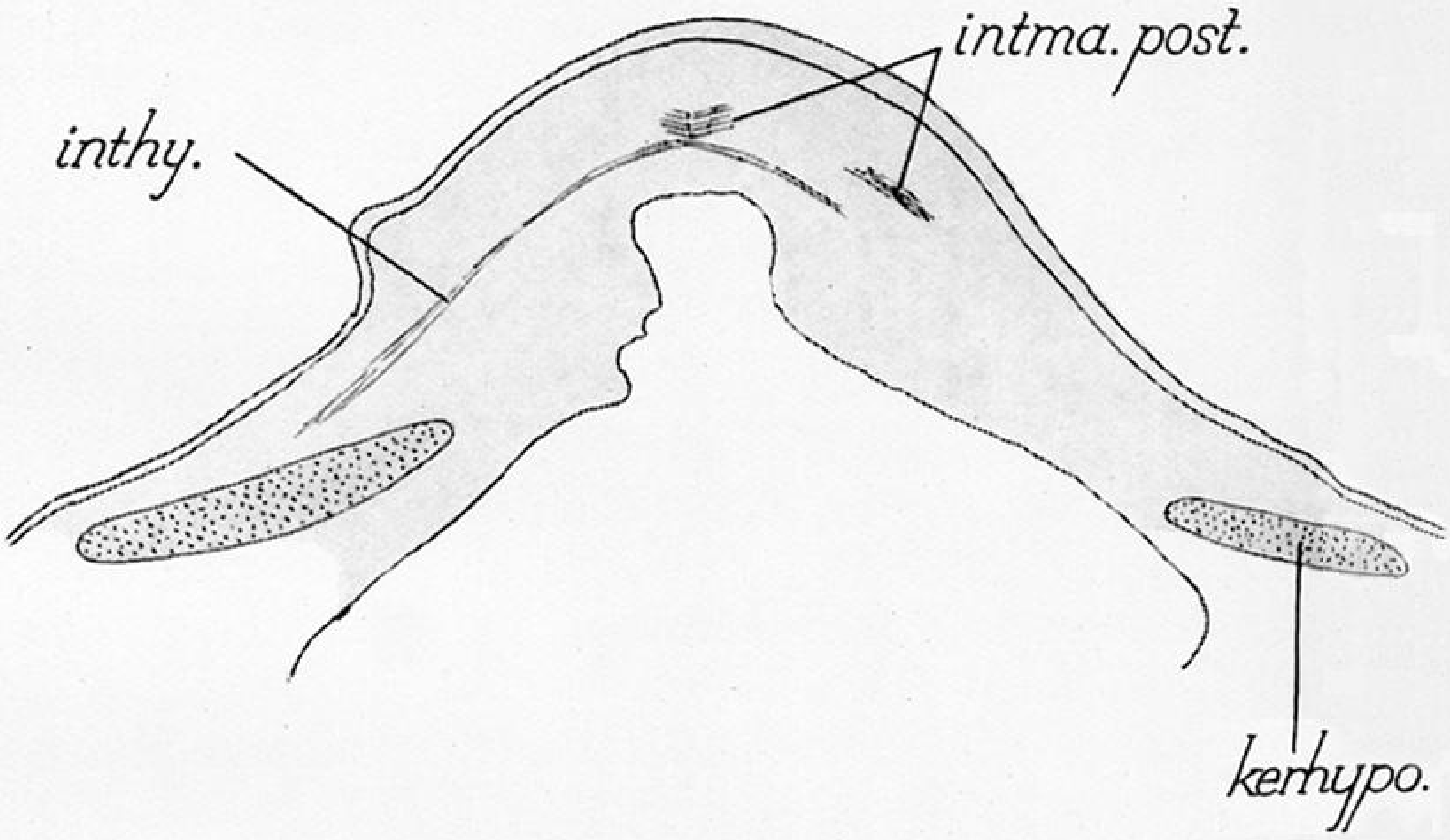

141

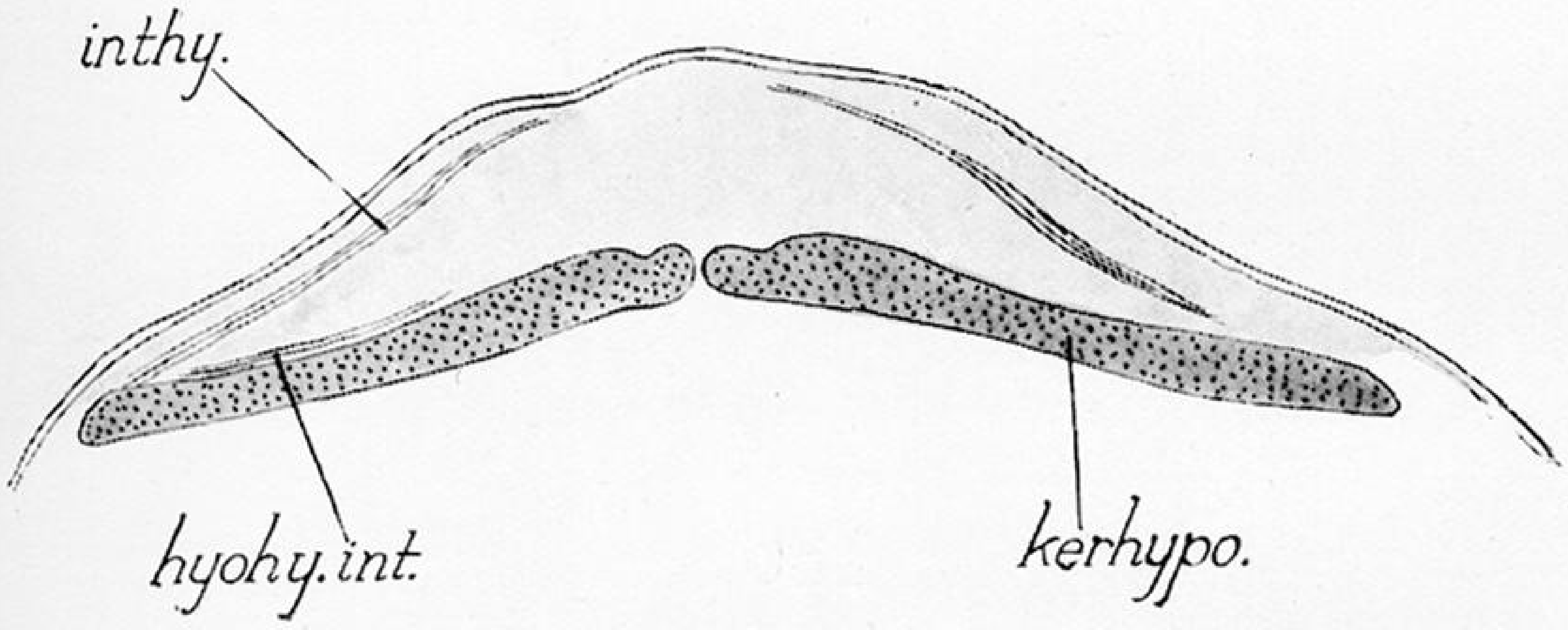

142

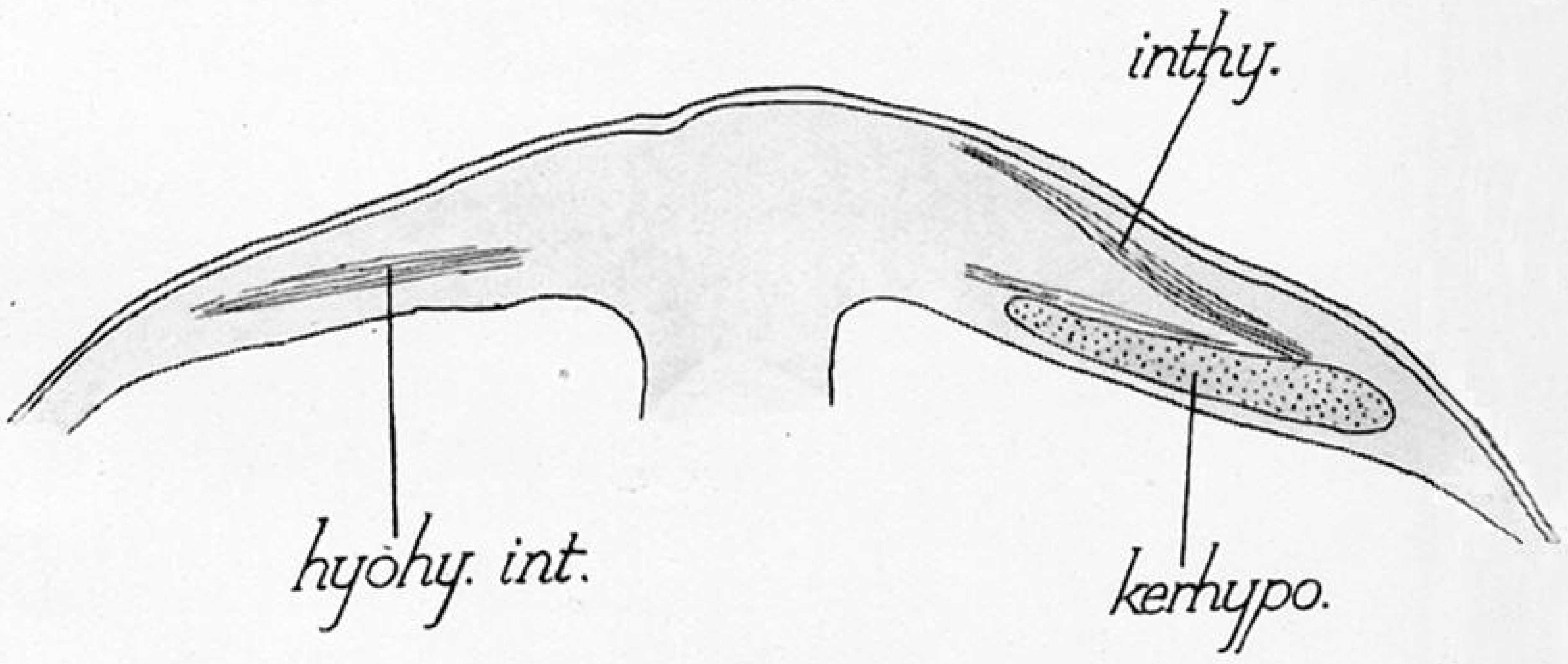

143

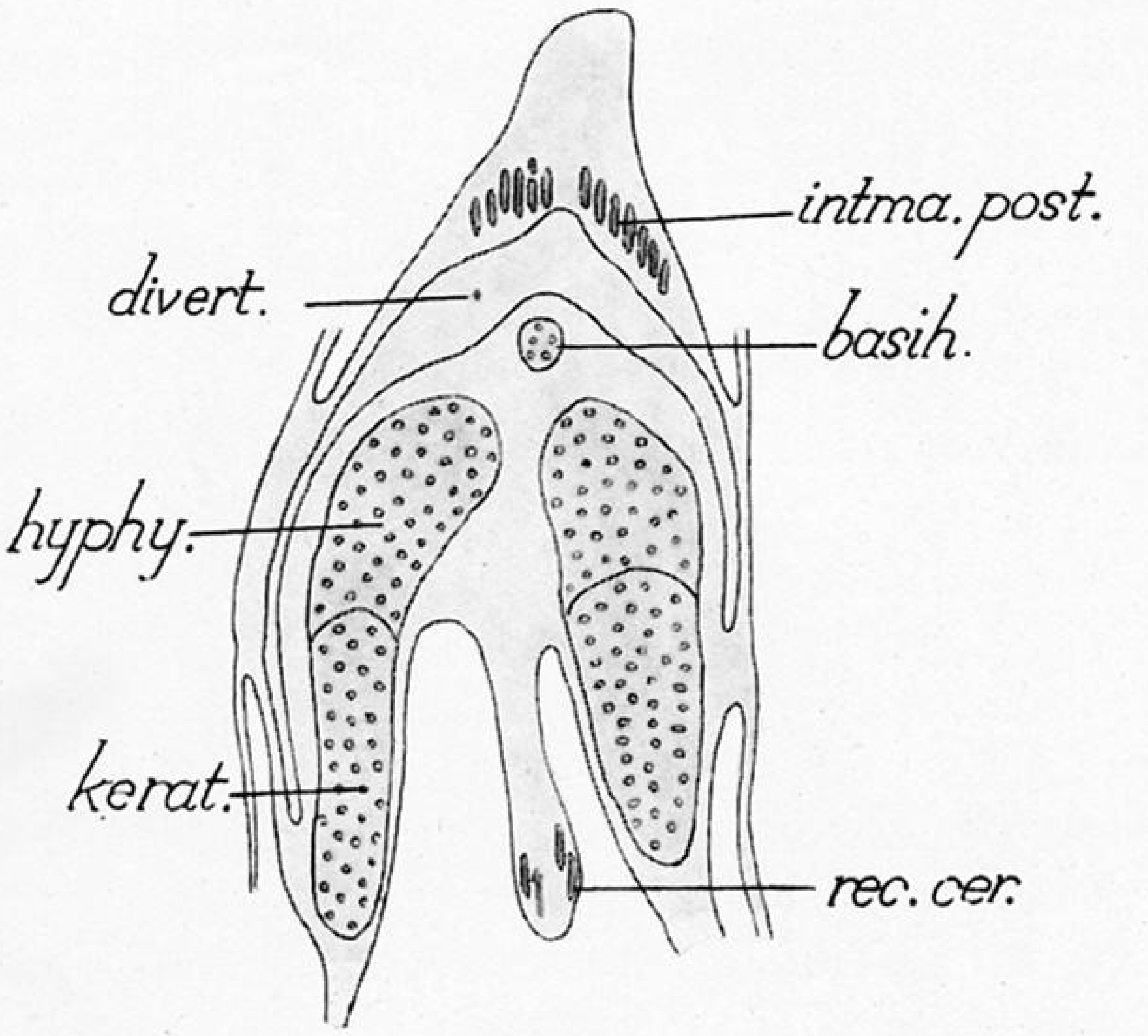

144

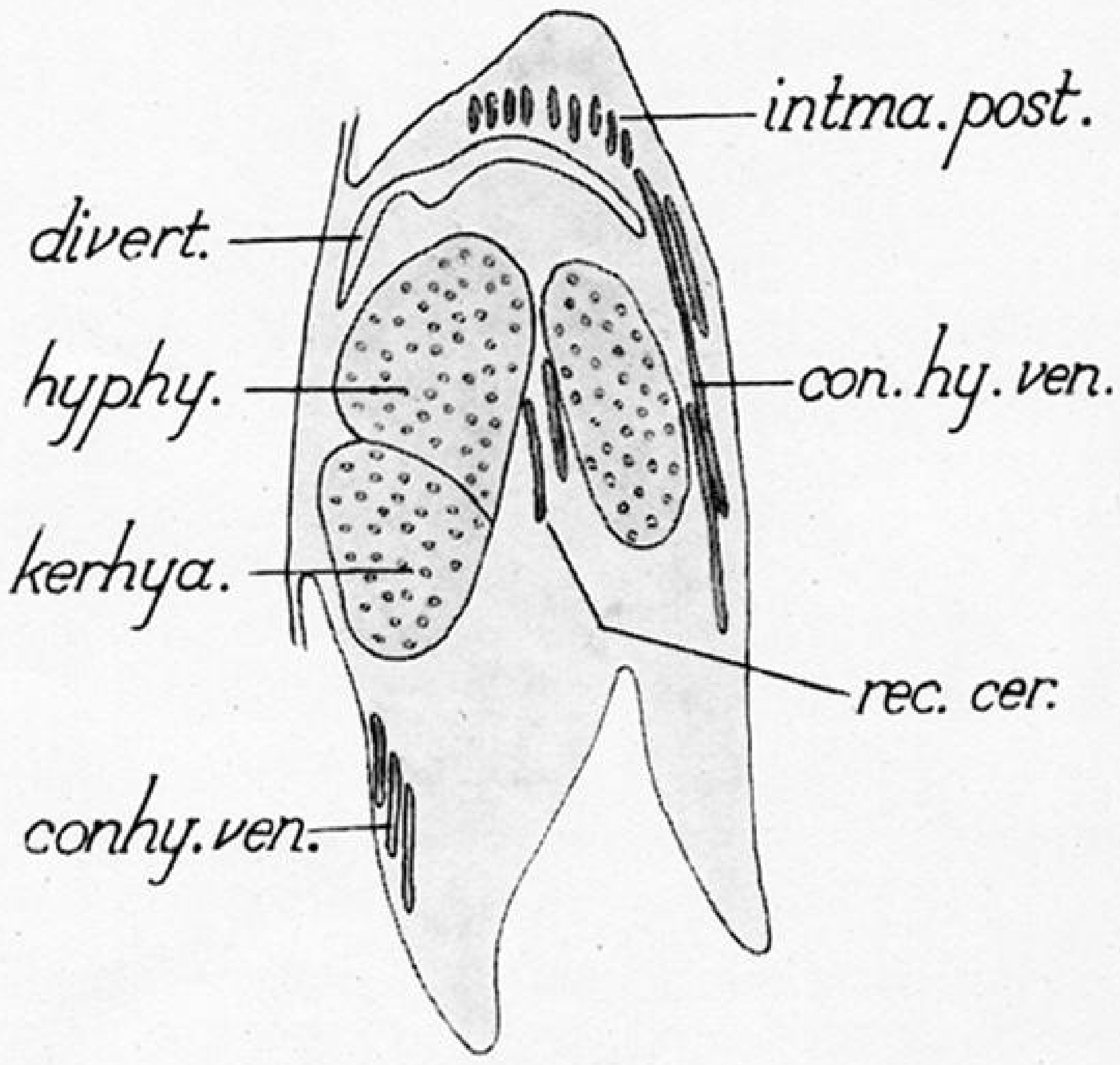

145

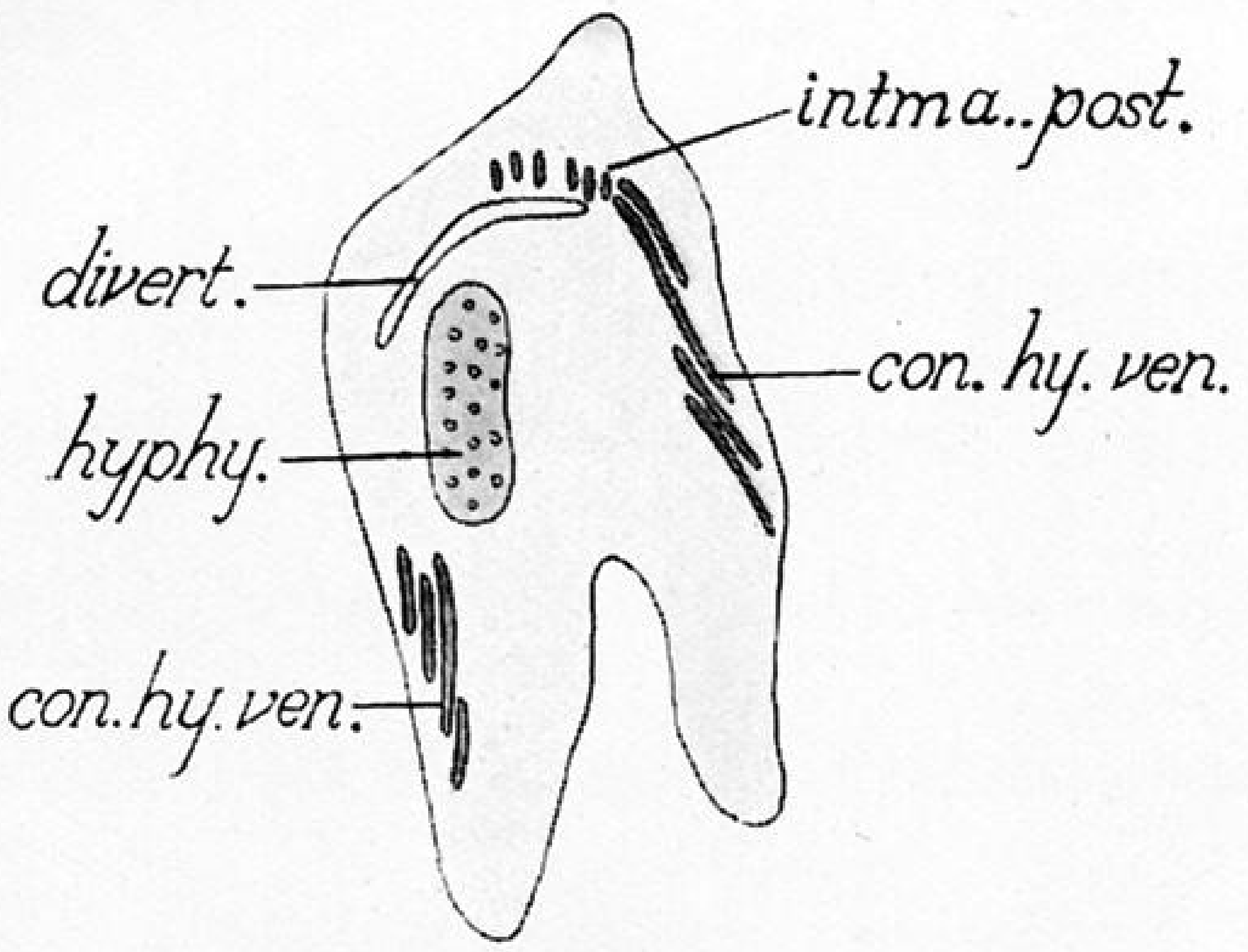

146

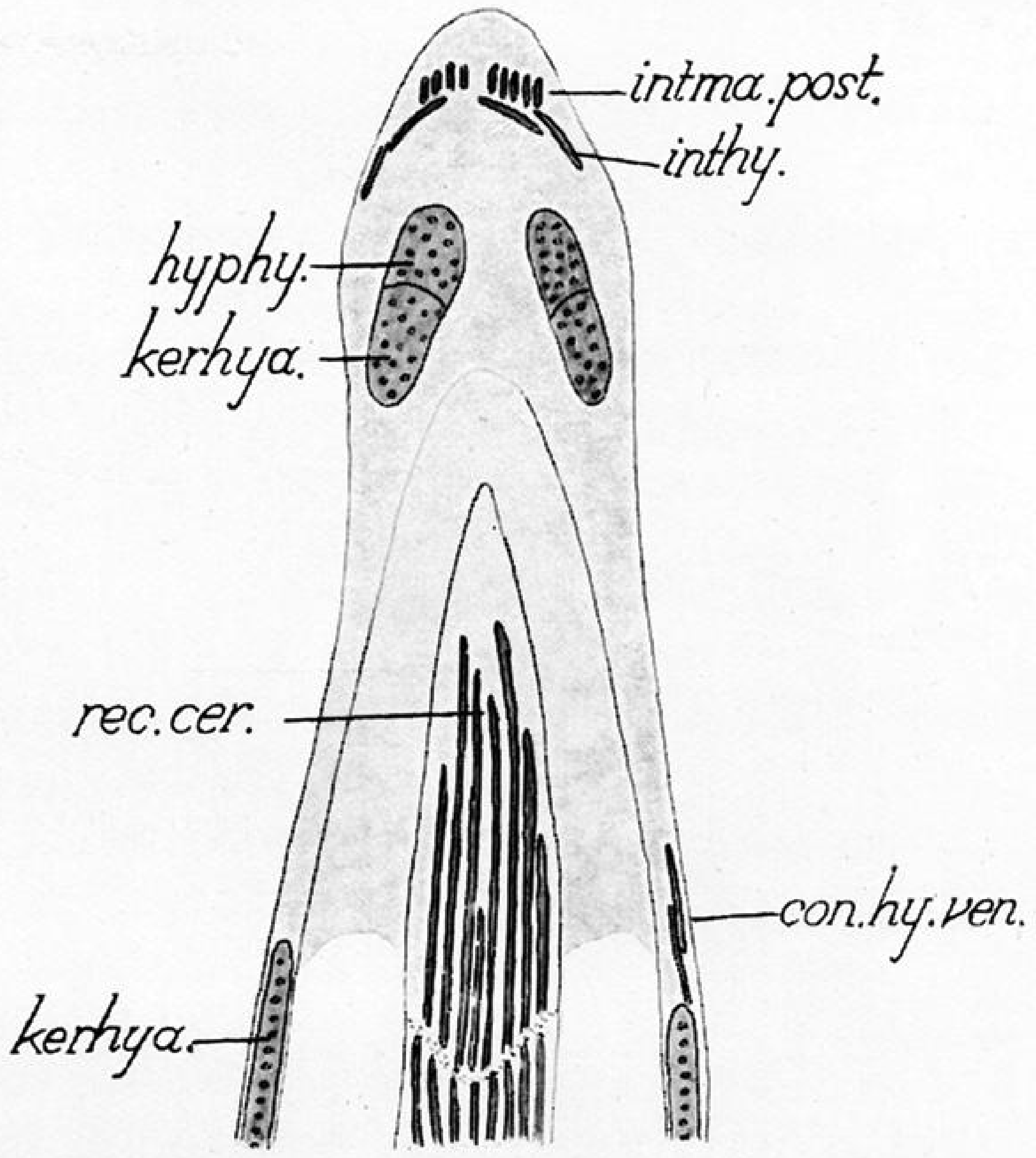

147

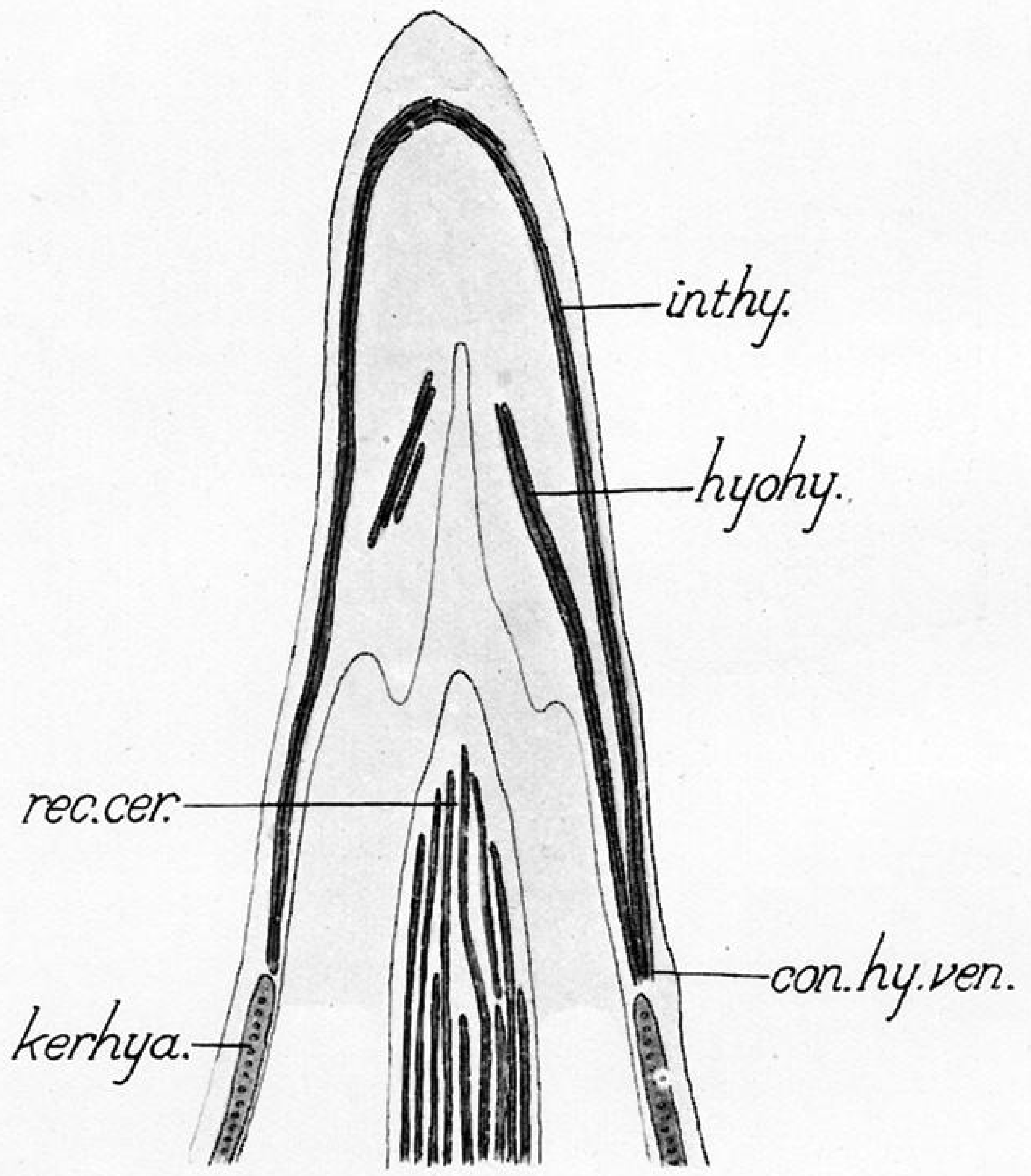

148

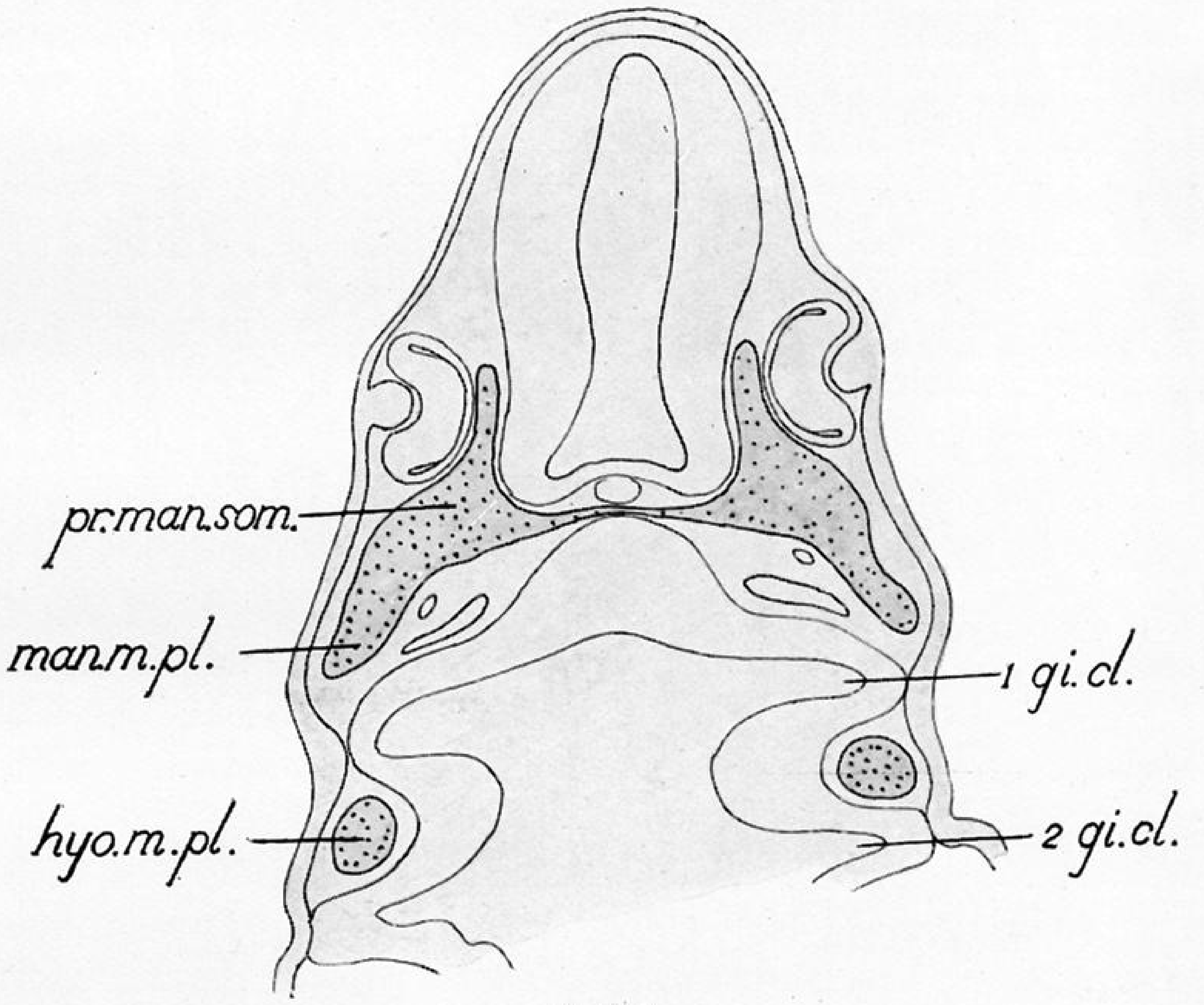

149

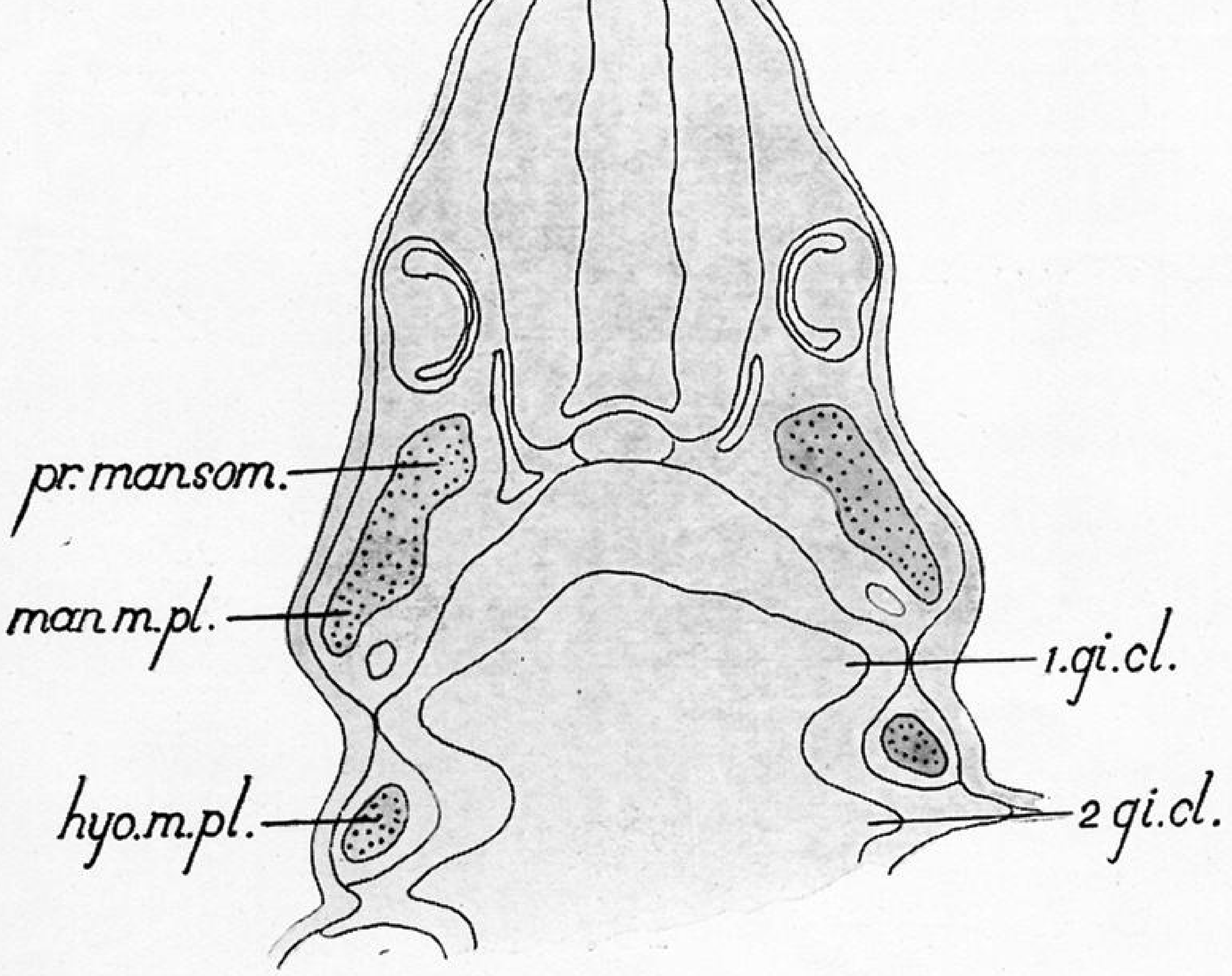

150

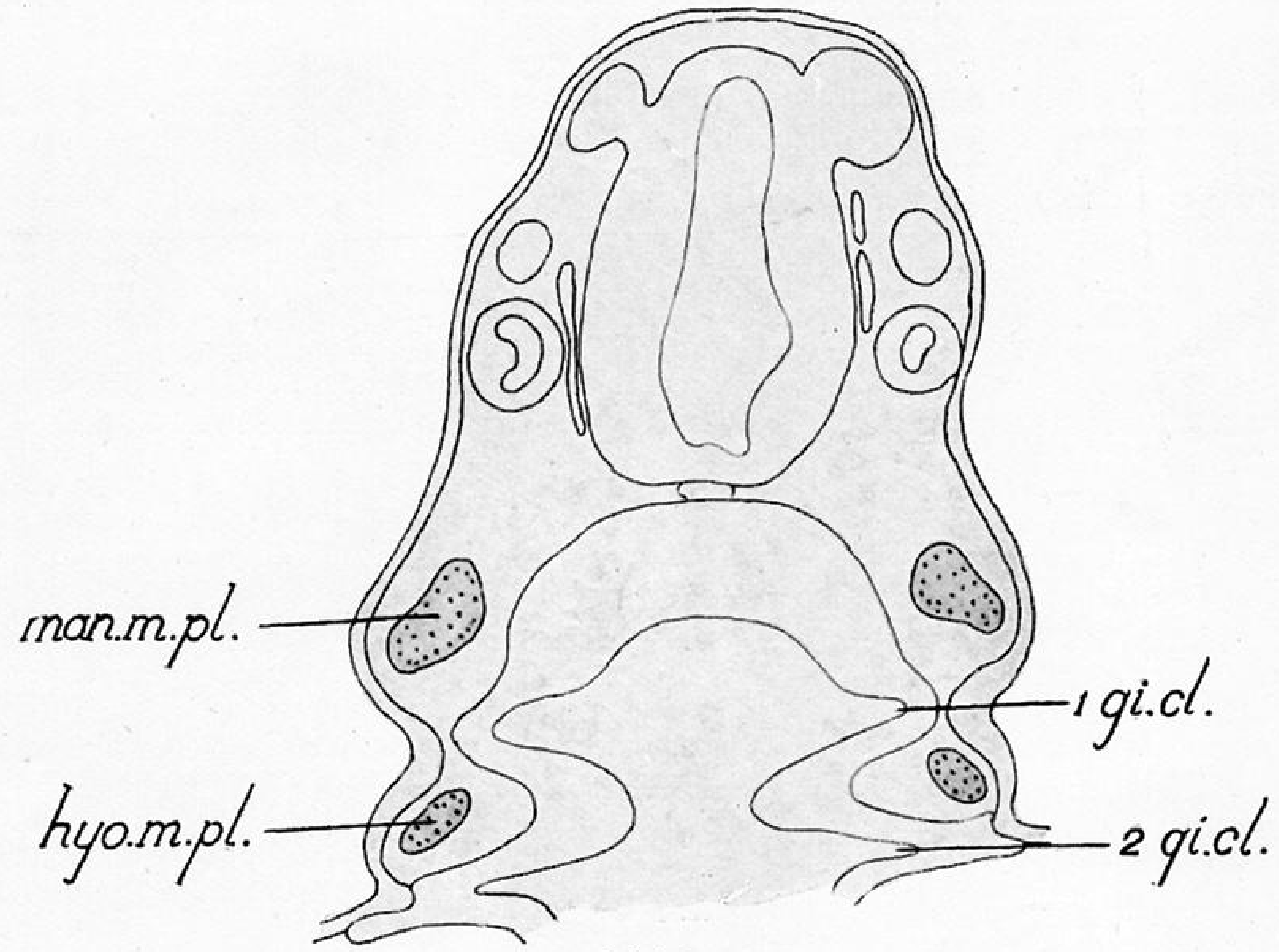

151

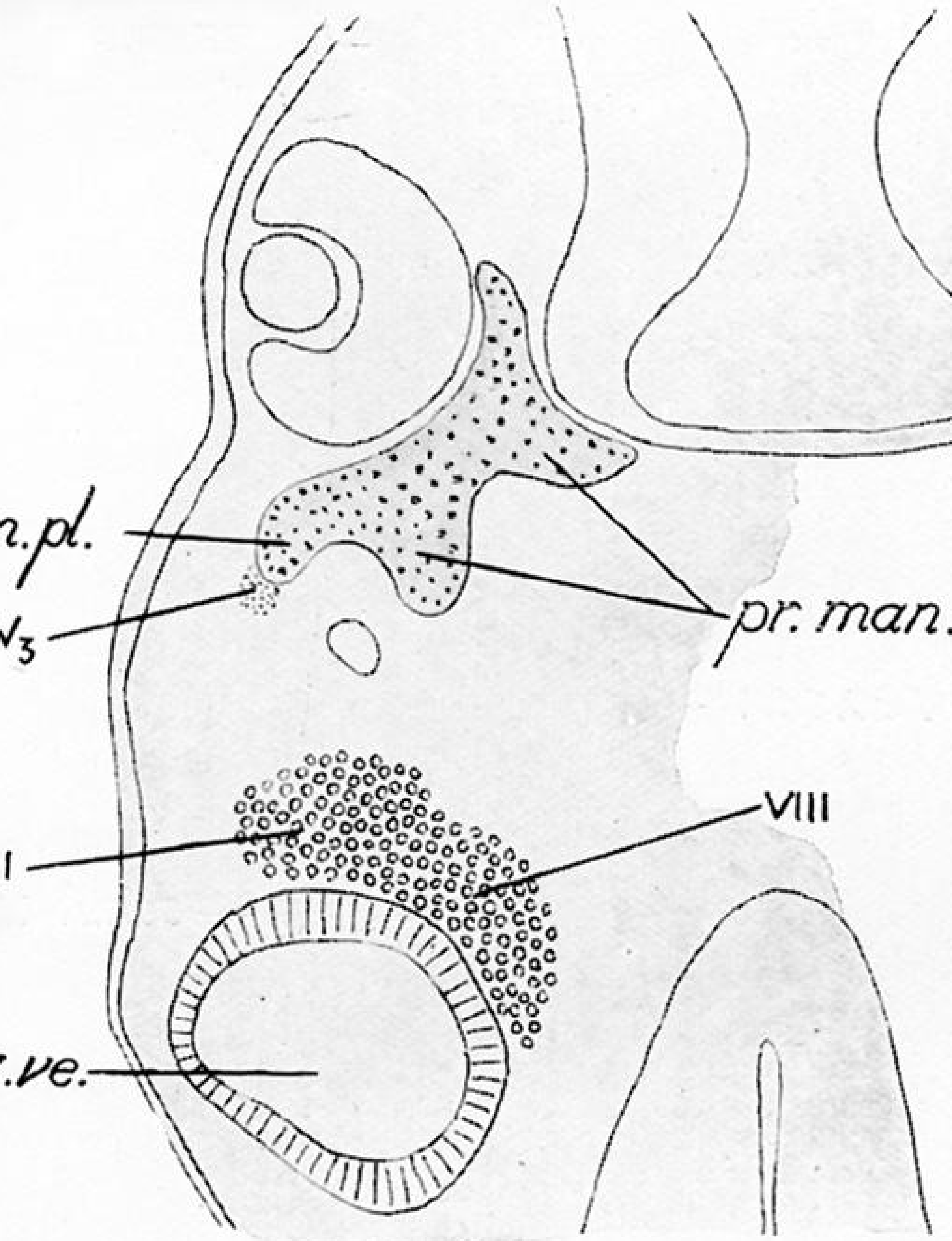

152

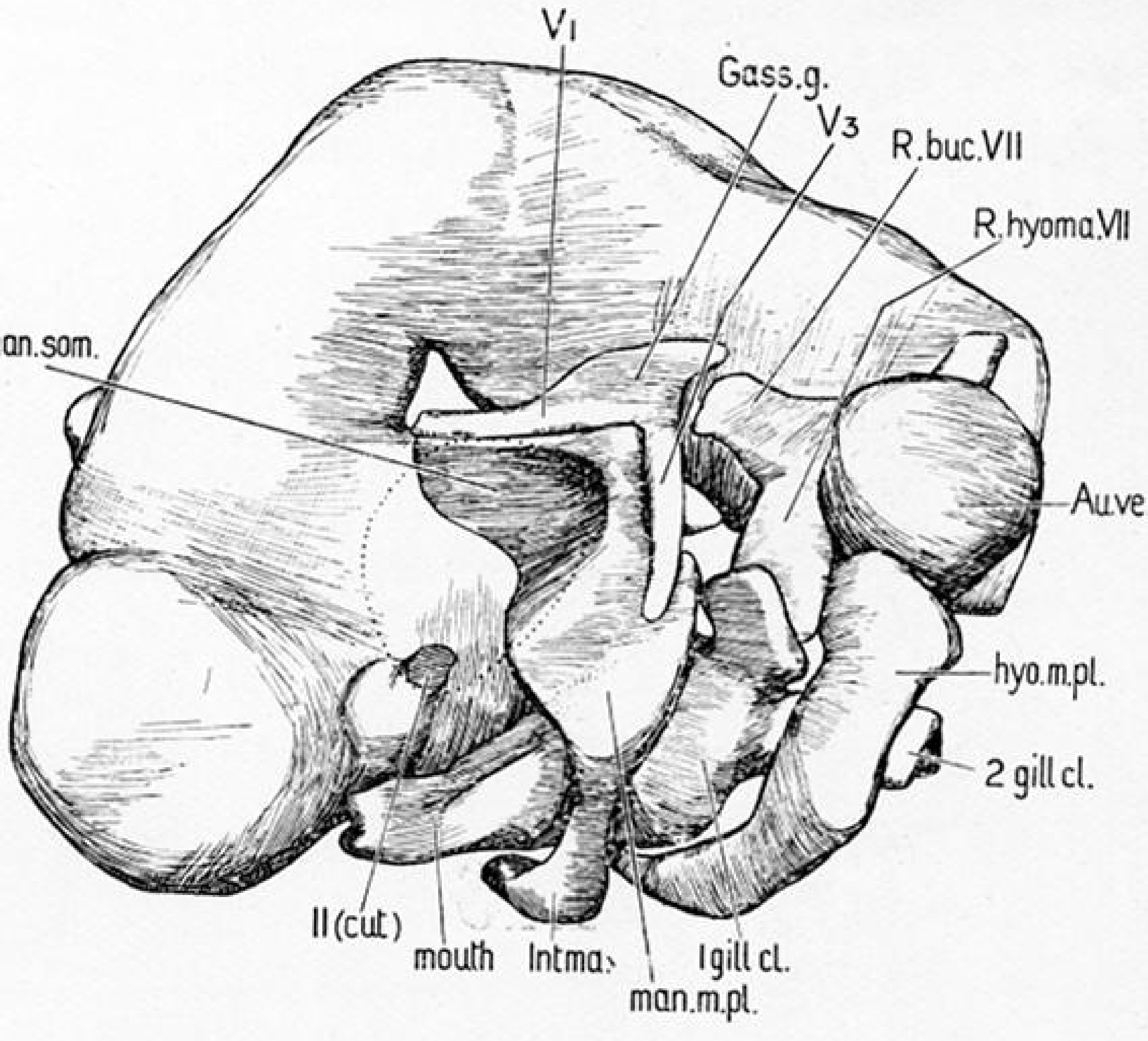

153

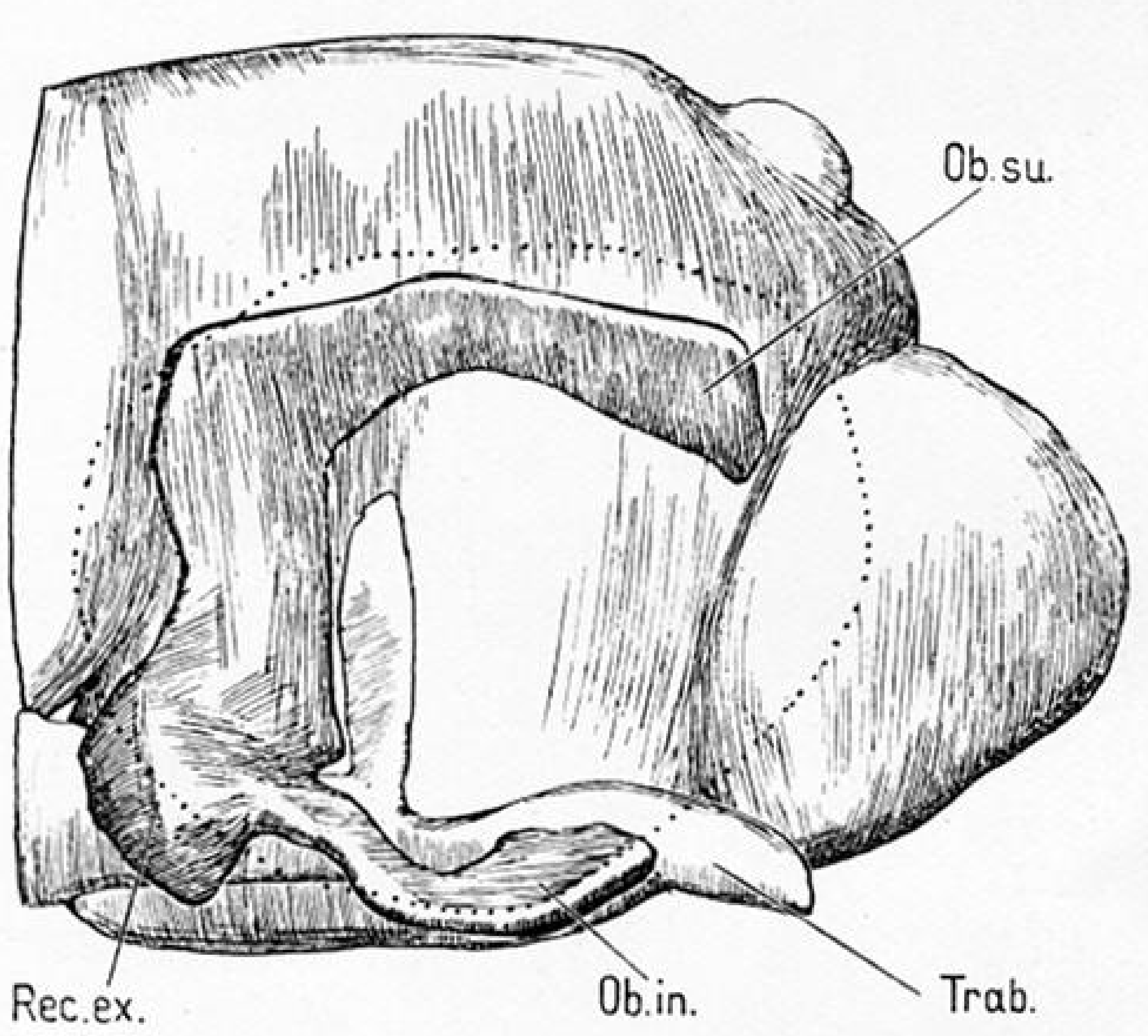

154

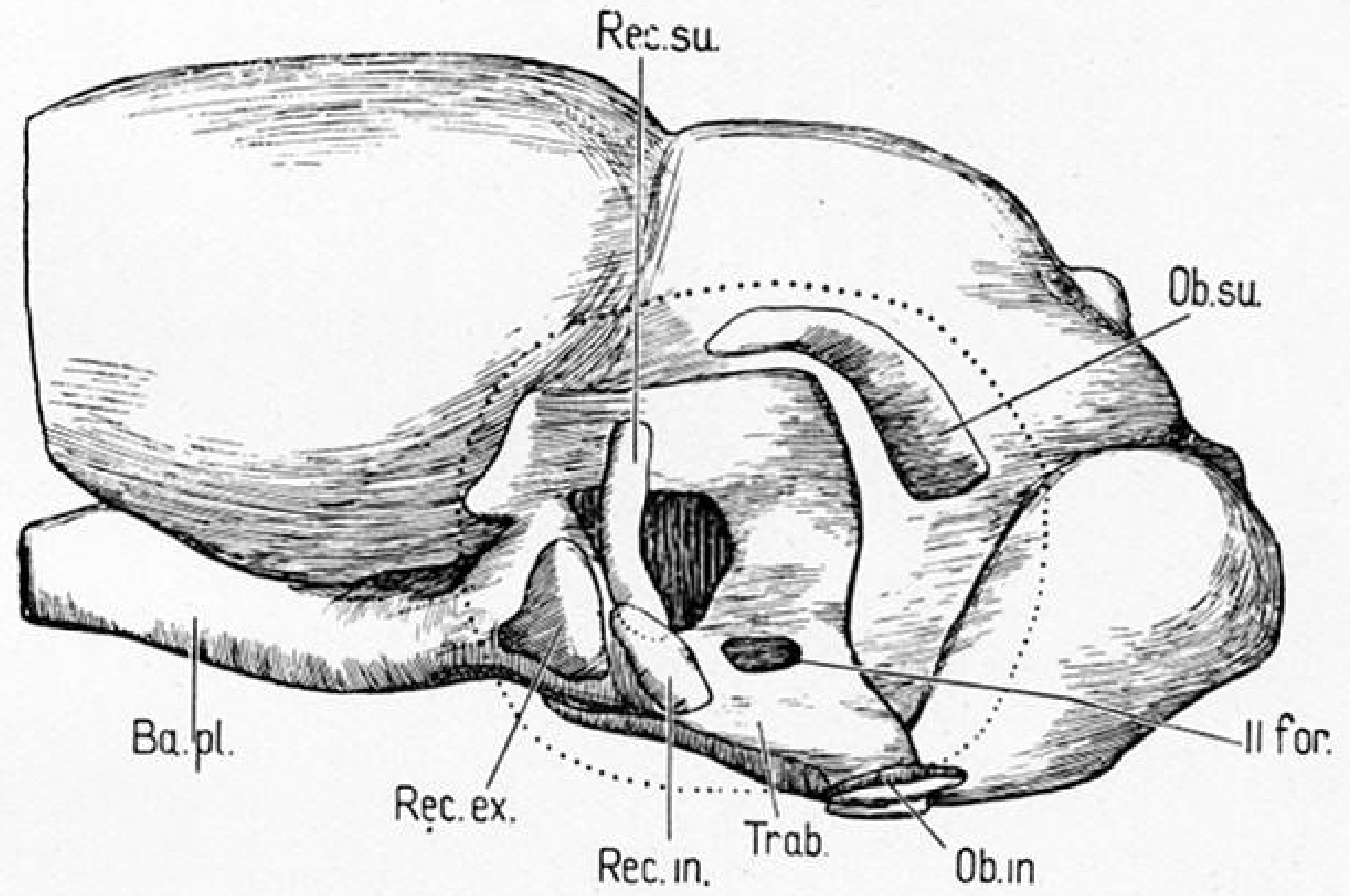

155

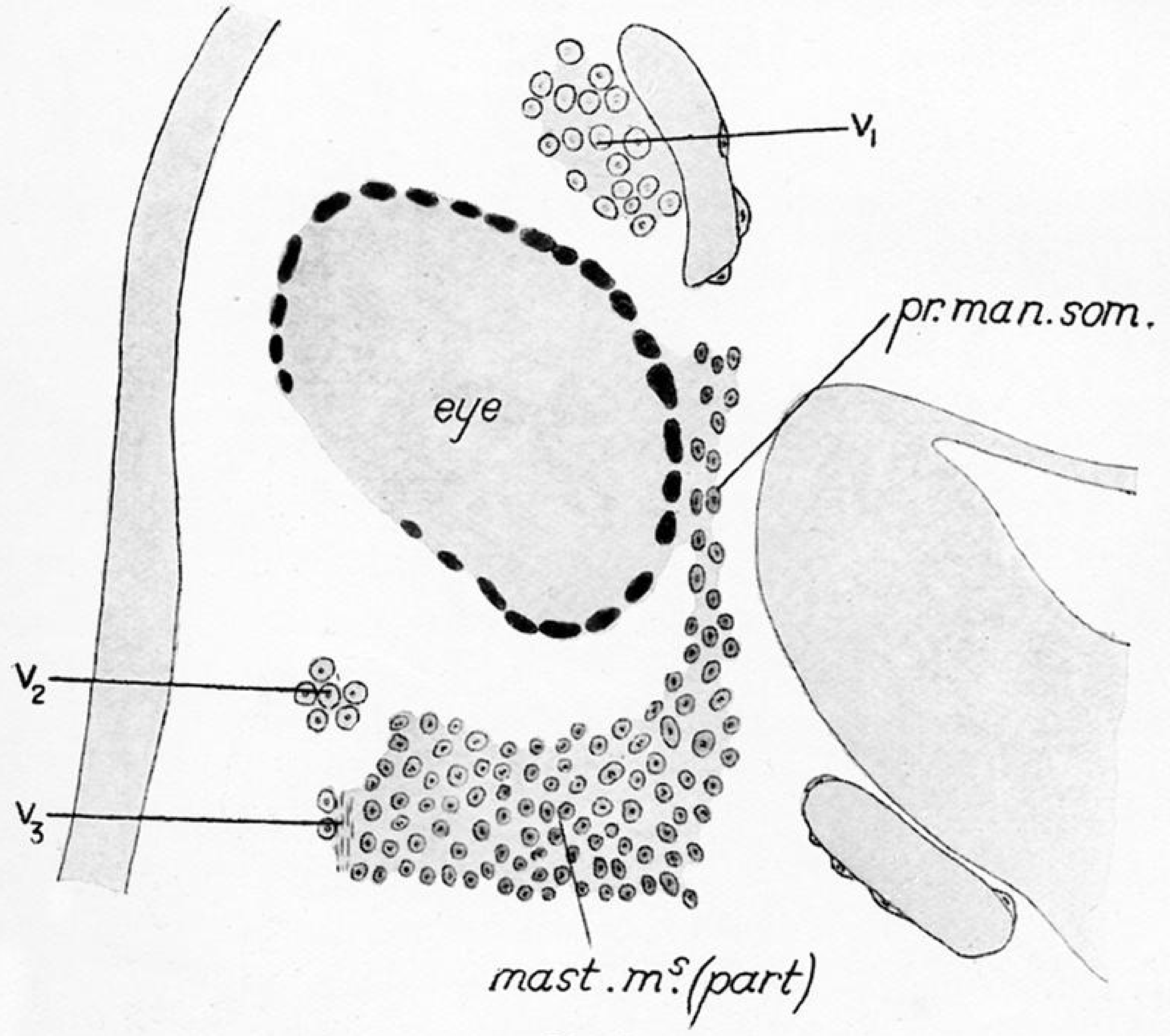

156

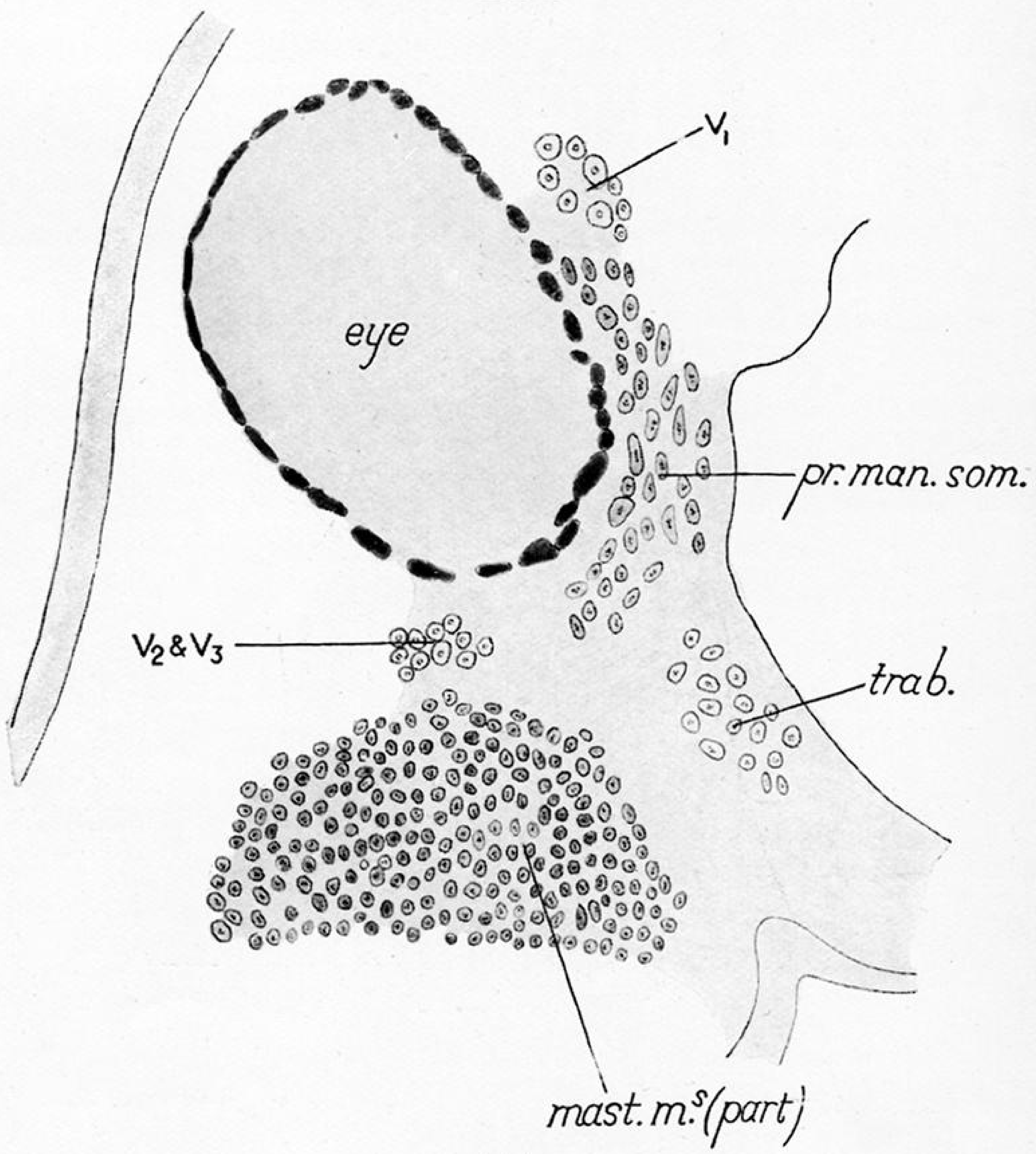

157

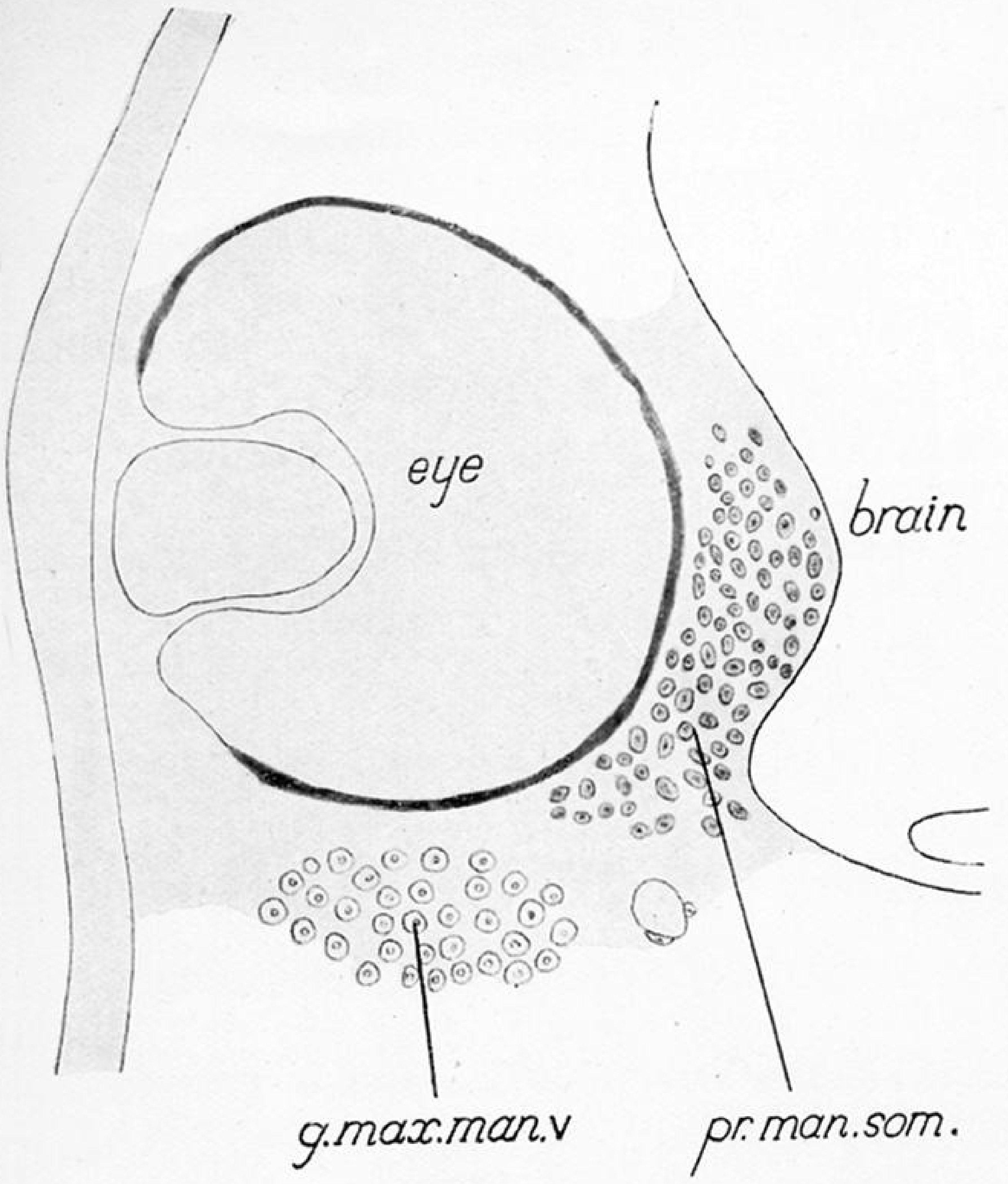

158

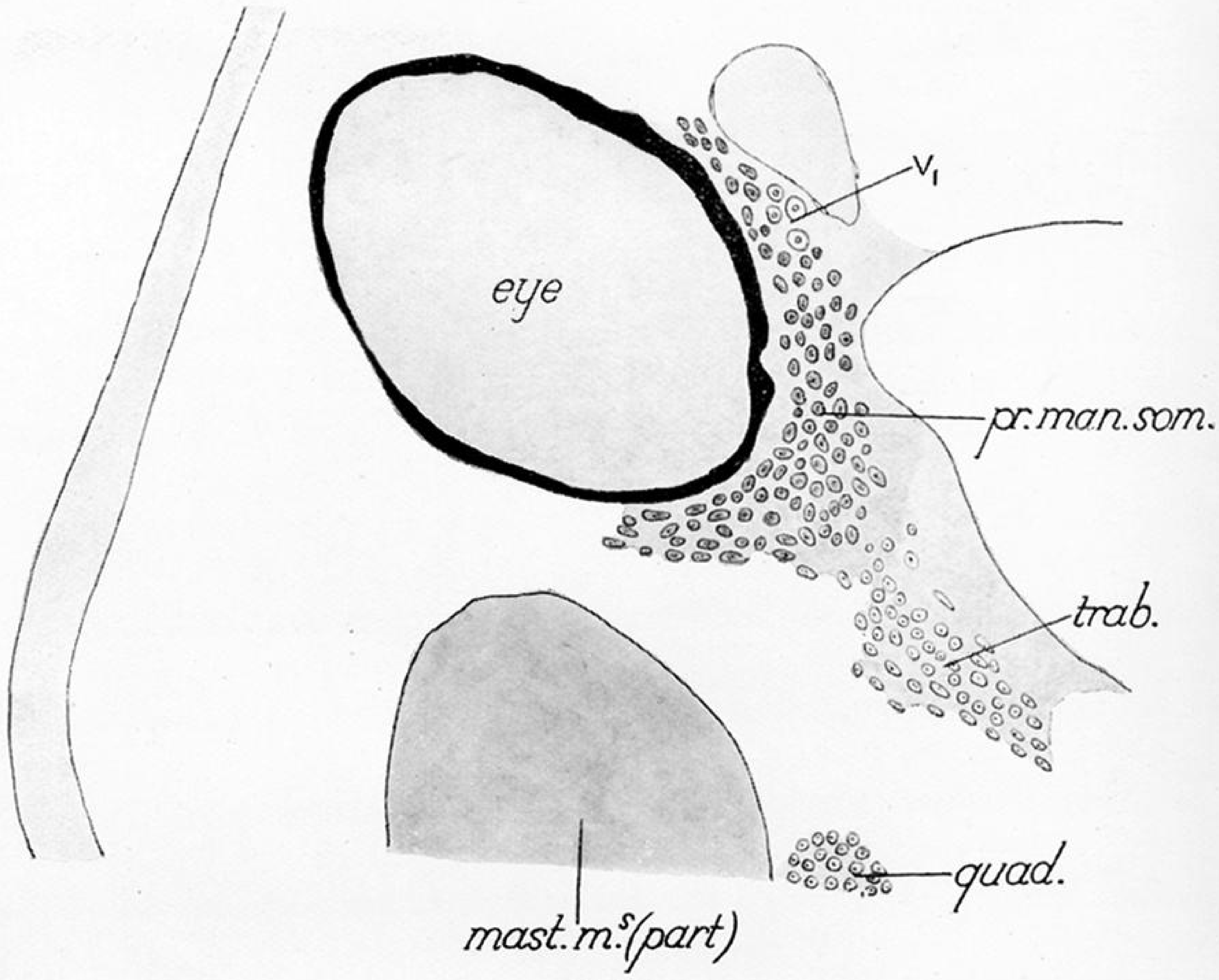

159

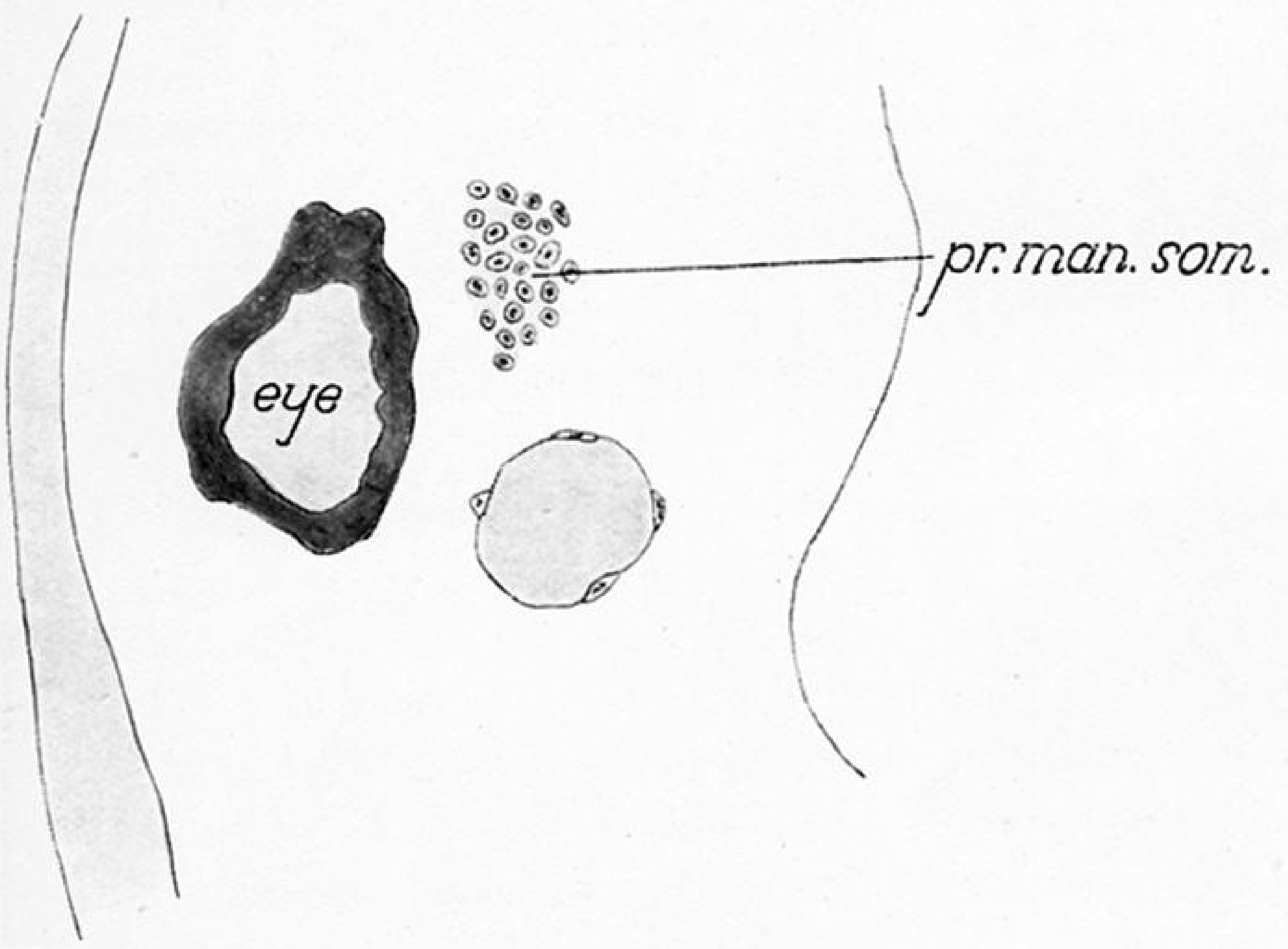

160

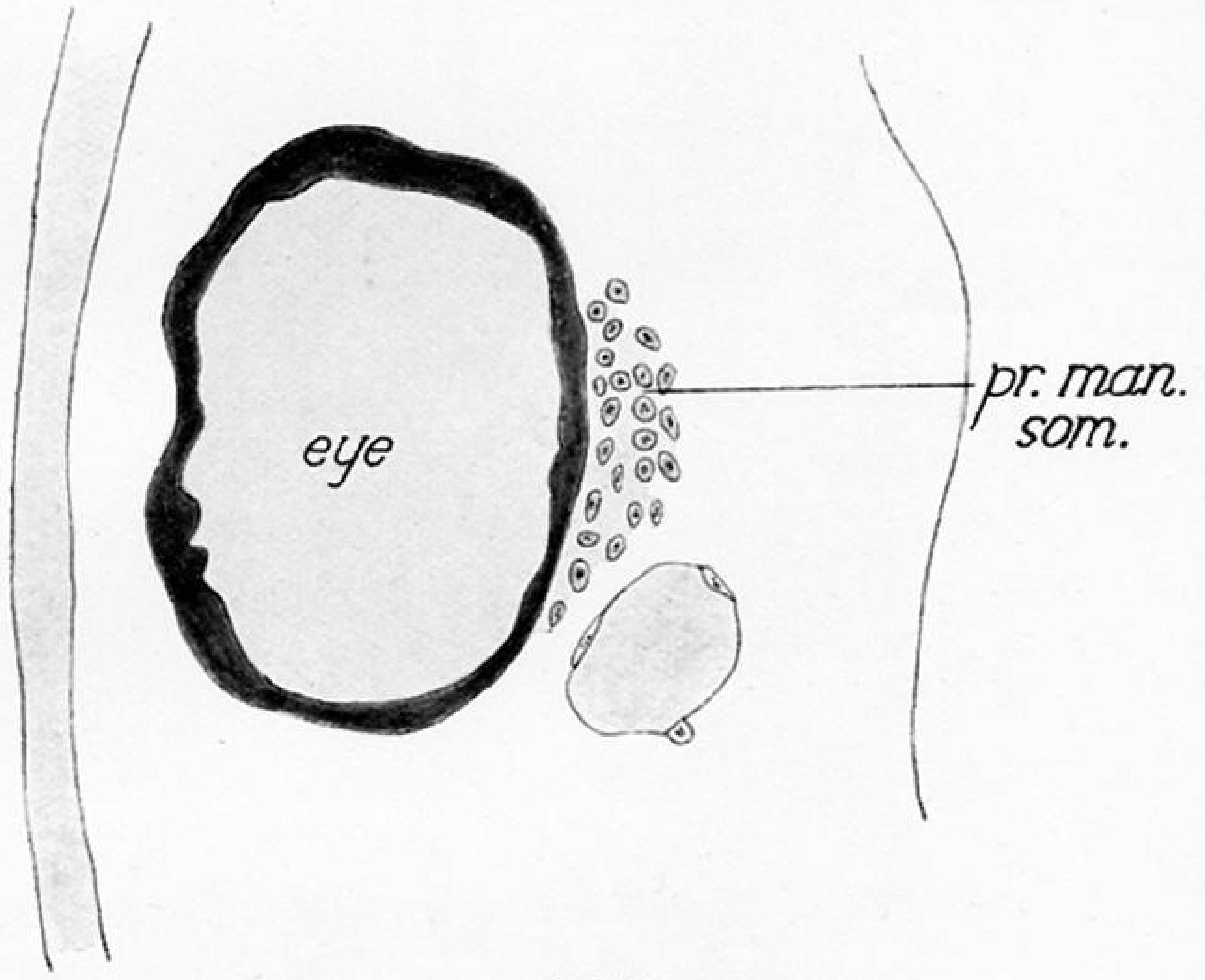

161

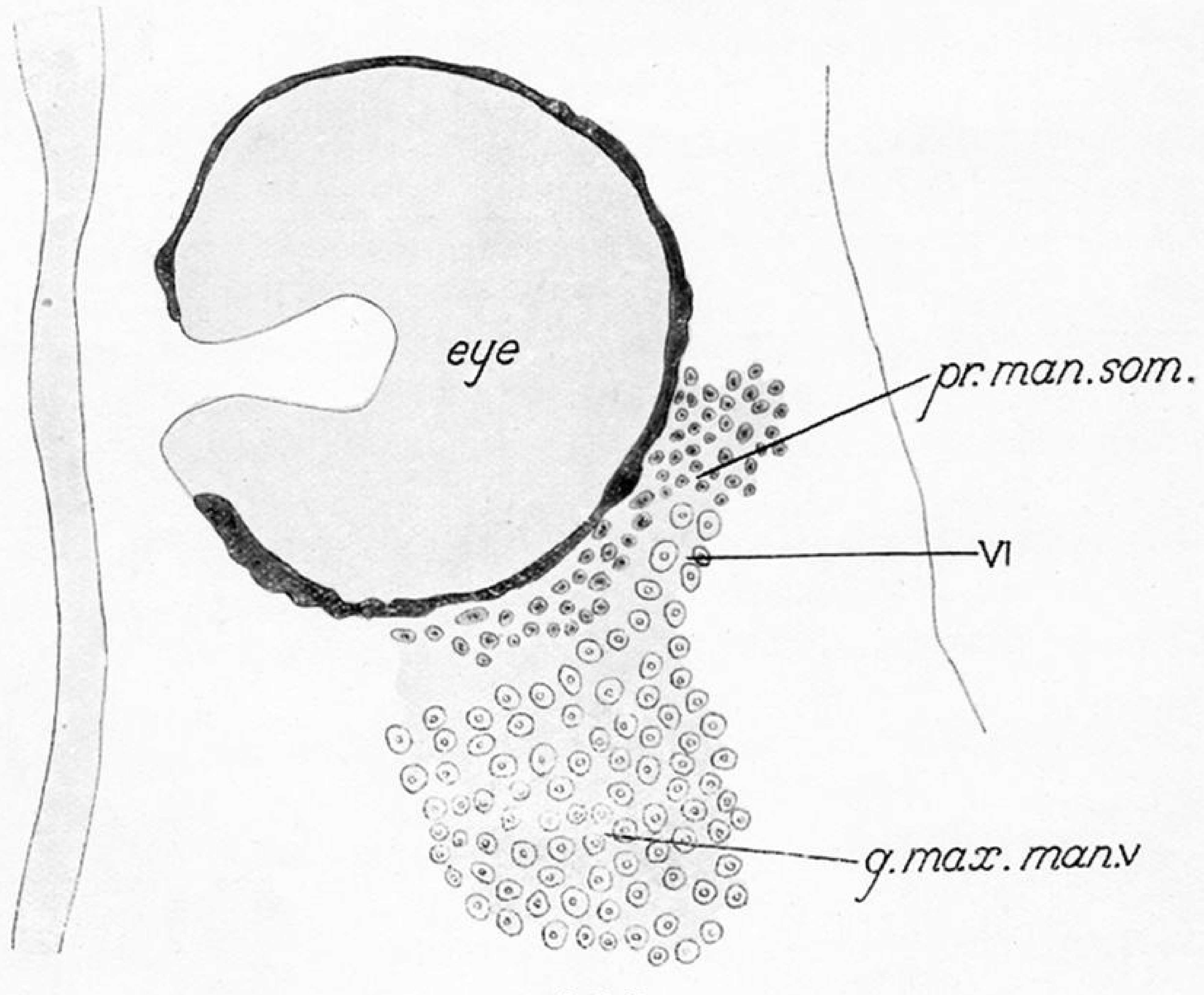

162